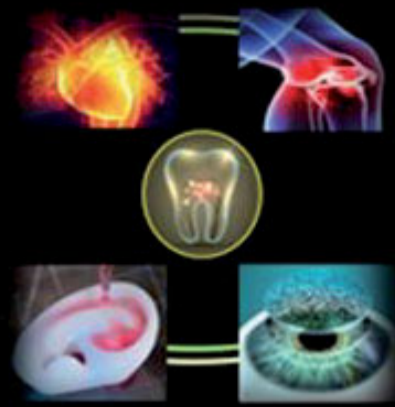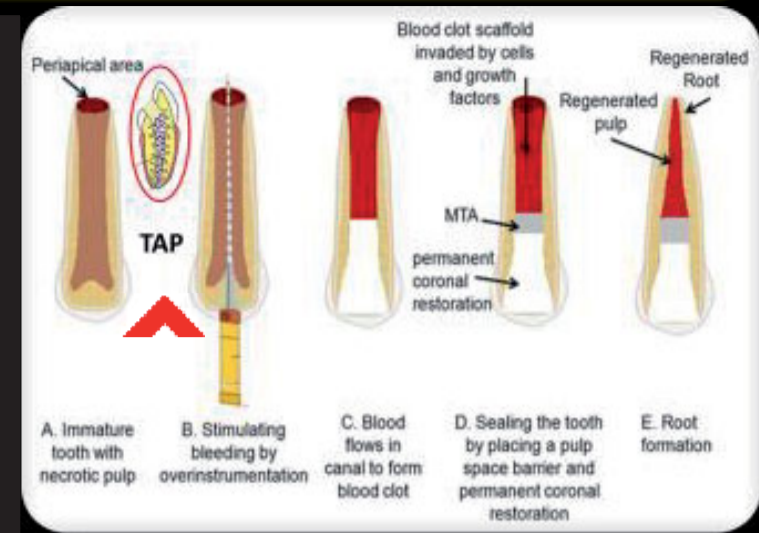


# Comparative Analysis of Tooth Discoloration Induced by Conventional and Modified Triple Antibiotic Pastes Used in Regeneration

## INTRODUCTION



Currently, regenerative medicine is a field that requires tremendous exploration. In dentistry, it has become an alternative option to the apexification procedure for the treatment of immature permanent teeth. It involves debridement of the root canal space with minimal instrumentation followed by the placement of triple antibiotic paste (TAP) which is the only source of disinfection (1). TAP consists of ciprofloxacin, metronidazole, and minocycline. The major problem is that minocycline causes visible crown discoloration.



## OBJECTIVE

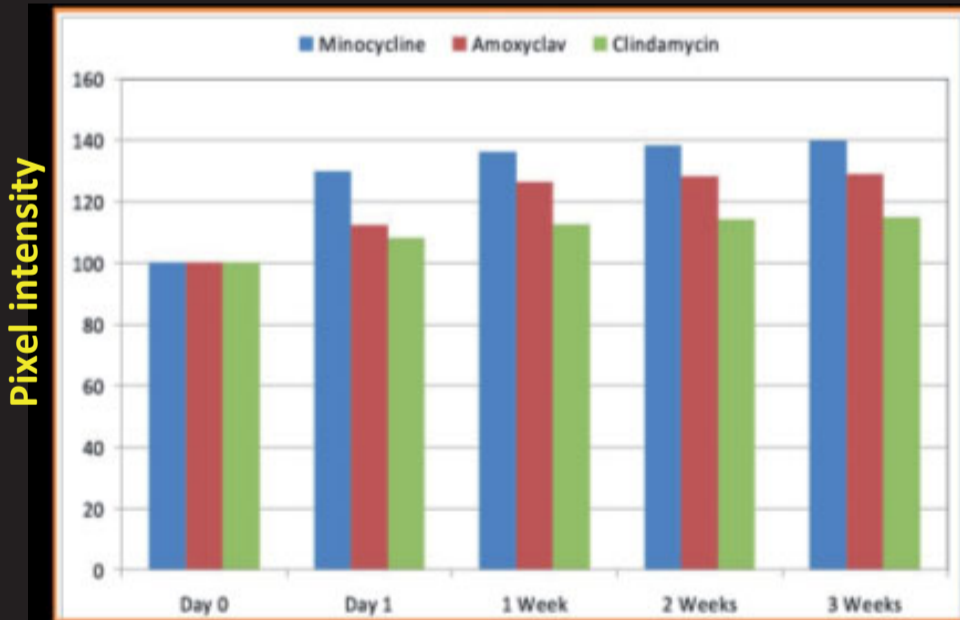
The aim of the study is to assess the discoloration potential of modified TAP, where minocycline is substituted with amoxycylav and clindamycin.

## MATERIAL & METHOD

Images were taken with DSLR on day 0, day 1, and at weeks 1, 2, and 3 at a fixed resolution. The slice analysis was performed using the software ImageJ. The images were turned into quantifiable data, and the pixel intensity was measured for each group over different time periods. The mean values were then calculated.

	Day 0	Day 1	Week 1	Week 2	Week 3	Inference
TAP WITH MINOCYCLINE						
TAP WITH AMOXICLAV						
TAP WITH CLINDAMYCIN						

## RESULTS



TAP with minocycline induced crown discoloration from day 1 after paste placement, and it increased with time. TAP with amoxiclav induced noticeable colour changes from week 1. TAP with clindamycin induced no visible discoloration at any tested time period.

## DISCUSSION

Root canal infections are polymicrobial in nature. Hence a combination is required to get rid of them. The most commonly recommended antibiotic combination is ciprofloxacin, metronidazole, and minocycline. This is because ciprofloxacin is a bactericidal broad-spectrum synthetic quinolone which is mainly effective against Gram negative organisms; metronidazole is a bactericidal imidazole that is highly effective against obligate anaerobes (2); and minocycline is a bacteriostatic broad-spectrum tetracycline (3) that is effective against Gram positive organisms. But minocycline chelates with calcium ions of the tooth to form an insoluble complex resulting in discoloration (4). Amoxicillin is an extended spectrum penicillin, clavulonic acid is a beta lactamase inhibitor, and clindamycin is a bacteriostatic lincosamide. Amoxicillin/clavulanic acid (amoxiclav) and clindamycin have an antimicrobial spectrum of action similar to minocycline (5,6). Modified TAP with clindamycin did not induce clinically visible discoloration up to 3 weeks after placement. MTAP containing clindamycin has an additional advantage of causing significantly less reduction in micro hardness when compared to conventional TAP (7).

## CONCLUSION

Within the limitations of this study, it can be concluded that modified TAP with clindamycin did not induce clinically visible discoloration up to 3 weeks after placement. Further in vivo studies are required in order to evaluate the clinical efficacy.

**REFERENCES:** 1)Hoshino E, Kurihara-Ando N, Sato I, et al. In-vitro antibacterial susceptibility of bacteria taken from infected root dentine to a mixture of ciprofloxacin, metronidazole and minocycline. *Int Endod J* 1996;29:125–30.2)Segura-Egea JJ, Gould K, Sen BH, et al. Antibiotics in endodontics: a review. *Int Endod J* 2016 Dec 22; <http://dx.doi.org/10.1111/iej.12741> [Epub ahead of print].3)Chung SH, Park Y-S. Local drug delivery in endodontics: a literature review. *J Drug Deliv Sci Technol* 2017;39:334–40. 4) S, Tsuchiya H, Yao J, et al. Reversed-phase ion-pair chromatographic analysis of tetracycline antibiotics. Application to discolored teeth. *J Chromatogr Biomed Sci Appl* 1998;706:279–85. 5) Brook I, Lewis MA, Sandor GK, et al. Clindamycin in dentistry: more than just effective prophylaxis for endocarditis? *Oral Surg Oral Med Oral Pathol Oral Radiol Endod* 2005;100:550–8.6) Radomska-Le sniewska DM, Skopi nska-R ozwska E, Malejczyk J. The effect of clindamycin and lincomycin on angiogenic activity of human blood mononuclear cells. *Cent Eur J Immunol* 2010;35:217–22.7)Prather BT1, Ehrlich Y, Spolnik K, et al. Effects of two combinations of triple antibiotic paste used in endodontic regeneration on root microhardness and chemical structure of radicular dentine. *J Oral Sci.* 2014 ;56(4):245-51.