

Management of a Deficient Anterior Maxillary Ridge

An Esthetic Challenge

Dr. Abhishek Gupta *MDS, FICOI, DICOI (USA)*

Prosthodontist & Implantologist (Pune, India)

Dr. Suraj Khalap *MDS*

Prosthodontist & Implantologist (Mumbai, India)

INTRODUCTION

The availability of adequate bone volume for dental implant placement is often diminished by trauma, pathology, periodontal disease, and tooth loss. Bone resorption in the anterior maxillary ridge frequently results in a bucco-palatal and corono-apical deformity, which precludes implant placement. Grafting procedures have been documented to be highly effective in reconstructing jaw anatomy and providing biomechanical support for the placement of dental implants.

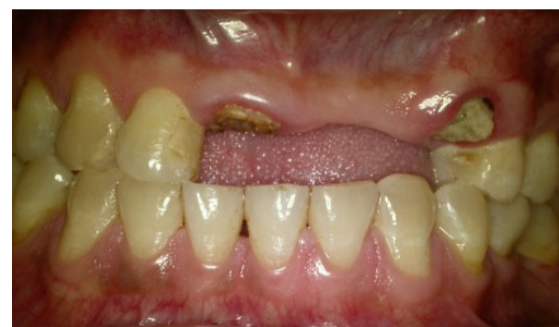OBJECTIVE

This poster describes a surgical & prosthetic approach to achieve a highly aesthetic rehabilitation in a case with a severely deficient anterior maxillary ridge. A technique of bone augmentation with block allograft and titanium mesh is described.

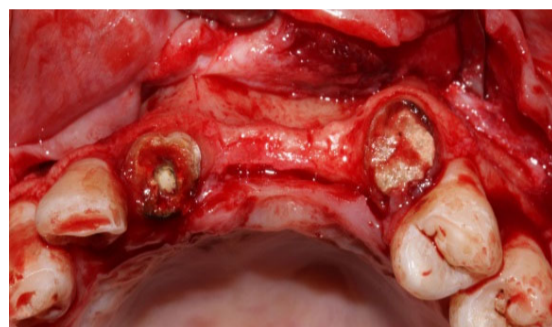
MATERIAL & METHODS

The treatment protocol was divided into 3 stages as follows:

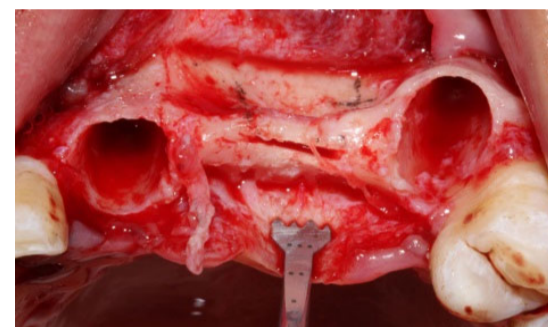
Stage 1: Hard Tissue Management



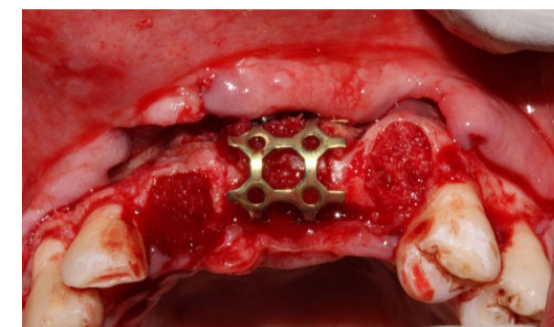
Pre-Treatment



Bucco-Lingual deficiency in anterior ridge

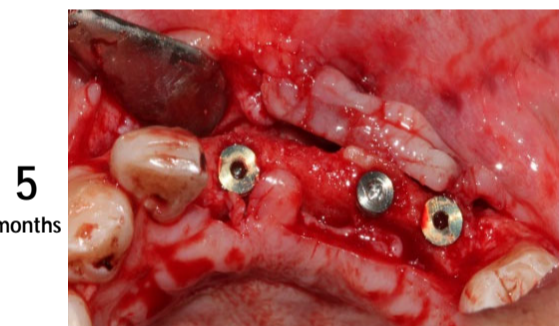


Atraumatic Extraction and Ridge Split

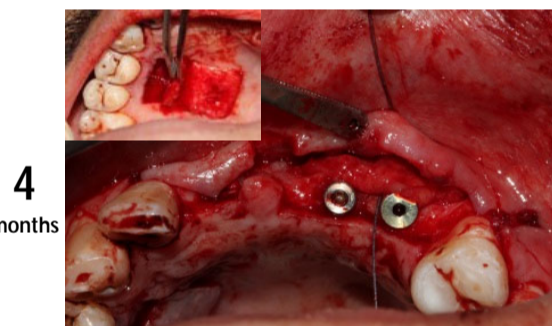


GBR with Titanium Mesh

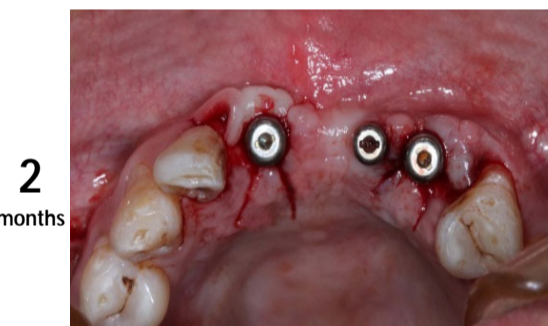
Stage 2: Soft Tissue Management



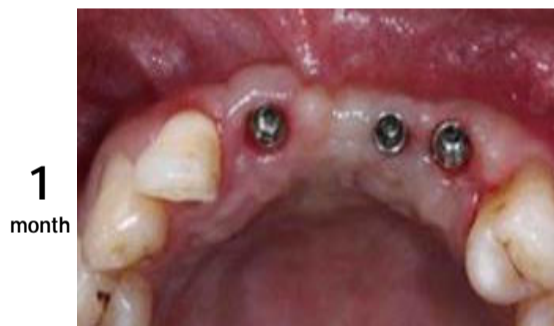Implants placed



Connective Tissue Grafting

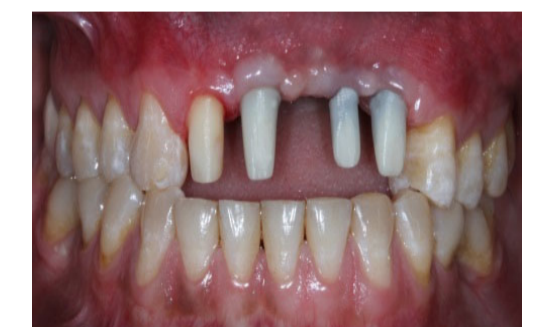

Papilla Regeneration using Tissue Contouring Technique

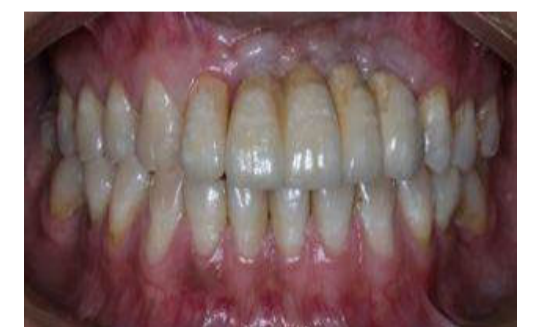

Stable soft tissue around implants

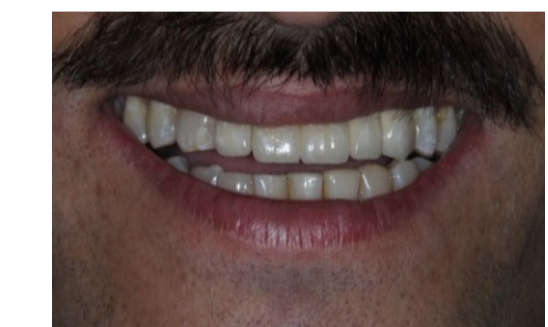Stage 3: Prosthetic Management



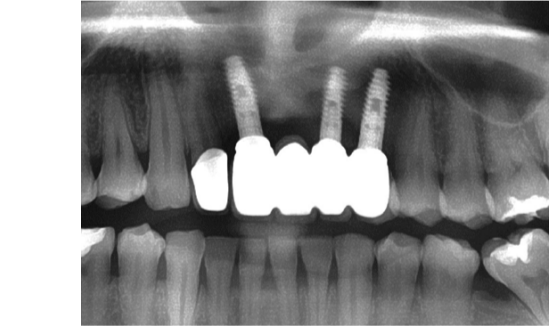
Customized Zirconia Abutments



Porcelain fused to Zirconia Prosthesis



Smile restored



Post-op OPG

DISCUSSION & CONCLUSION

Lack of sufficient bone to place an implant at a functionally and an aesthetically appropriate position is a common problem, especially in the maxillary anterior region. The ridge split technique creates a new implant bed by longitudinal osteotomy of the alveolar bone when the width of bone is 3 mm to <6 mm. The management of bucco lingual defects <3 mm are still critical in the aesthetic zone. Lateral augmentation with bone blocks and guided bone regeneration have been successfully adopted for management of bucco-palatal horizontal ridge defects. Autogenous bone is regarded as the "gold standard" for cortical-cancellous blocks (Misch et al., 1992). However, its use is limited by risks of donor site morbidity: immediate postoperative pain & oedema, infections, hematomas, and neurosensory deficits. Cancellous bone-block allografts have been used for alveolar ridge augmentation with clinical success (Nissan et al., 2008) and with fewer post-operative complications.

Thicker soft-tissue biotypes promote long-term stable gingival margins and provide a better aesthetically appealing prosthesis. The use of a connective tissue graft that is harvested from the patient's palate helps to achieve better soft tissue bulk and aesthetics. The rationale for the peri-implant plastic surgery approach goes well beyond pure aesthetics as it creates peri-implant keratinised mucosa and inter-implant soft tissue height in order to avoid food impaction, inter-implant airflow, and speech problems. Clinical data indicate reduced peri-implant mucosal discoloration and hence better aesthetics from zirconia abutments, which may be preferable over metal abutments in patients with thinner mucosal tissues or patients with high or gummy smiles.