

Horizontal Ridge Augmentation With Fresh-frozen Bone Allografts - Case Report

Dr. Eugénio Miguel Pereira (University of Coimbra, Faculty of Medicine); Prof. Dr. Alexander D'Alvia Salvoni (Faculty and Center for Dental Research São Leopoldo Mandic, Campinas, Brasil); Dr. Ricardo Dias (University of Coimbra, Faculty of Medicine); Prof. Dr. Fernando Judas (University of Coimbra, Faculty of Medicine); Prof. Dr. Fernando Guerra (University of Coimbra, Faculty of Medicine)

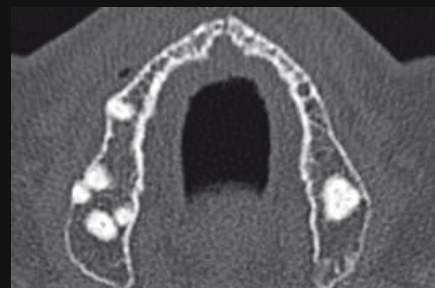
AIMS OF THE PROCEDURE

We intend to present a technique of reconstruction of maxillary horizontal bone defects by applying, fresh-frozen cortico-cancellous blocks allografts, from the Bone Bank, Faculty of Medicine, University of Coimbra, in the *onlay* technique, with the aim of implant supported prosthetic rehabilitation.

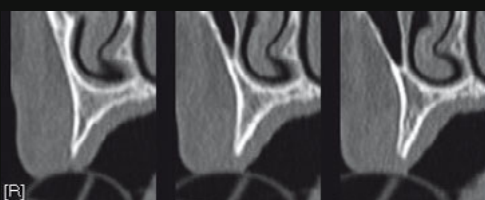
CASE REPORT

In a 23-months period (2012-2014), a 46-year-old female, ASA I, appeared in the Department of Dental Medicine, Faculty of Medicine, University of Coimbra. with lack of retention of the upper denture. Clinical records including digital photographs, panoramic and CT scans were recorded. The residual ridge was considered reduced in thickness if the bucco-palatal dimensions measured were $\leq 4,00\text{mm}$. The average thickness of the alveolar crest across the region to rehabilitate was 3,2mm. The patient signed a written informed consent form approved by the Ethics Committee of University of Coimbra. The fresh-frozen bone (FFB) allograft from the iliac crest was processed according to the international guidelines in an authorized bone tissue bank (Bone and Tissue Bank of the Coimbra Hospital and University Centre, Coimbra, Portugal). During the first surgical stage, FFB was thawed in a solution of sterile saline with vancomycin hydrochloride (Farma APS®, Portugal) 500ml/500mg for at least 40 minutes before the procedure, to gradually get to room temperature. Prior to surgery the patient rinsed with chlorhexidine 0,12% (Pierre Fabre®, Portugal). Under local anesthesia (4% articaine with 1:100.000 epinephrine), a full-thickness crestal incision and two vertical releasing incisions were performed; and the ridge defect was evaluated. After determine the size and shape of the needed blocks, the residual fibers were removed from the FFB, and it was cut and sculpted with rotary instruments. The recipient site was prepared with decortication to enhance bleeding and promote the revascularization of the FFB bone *onlay* blocks. The blocks were positioned, stabilized and fixed to the recipient site with micro-screws (Sistemas de Prótese, Conexão®, Brasil). The residual ridge was measured before and after placing the blocks, with a dial caliper. The gaps at periphery of the blocks were filled with FFB chips, and the sharp angles were gently reduced. The flaps were repositioned without tension with nylon 4-0 (Lab. Aragón, S.L.Esp.®). After a 5-months healing period, a second stage approach was performed, with the surgical exposure of the augmented sites. A third measurement of the ridge was taken. The micro-screws were removed and 8 standard-dental implants (Master Active, Conexão®, São Paulo, Brasil) were installed. A bone biopsy was harvested with a 3,00mm diameter trephine, provided that procedure would not compromised the implants. The core sample was fixed in formalin solution, decalcified, dehydrated and embedded in Paraplast®. Sections were stained with hematoxylin-eosin. The sections were examined by light microscopy. After six months healing period, the patient was rehabilitated with implant-supported fixed prosthesis. After each surgical intervention, the patient received antibiotics (amoxicillin+clavulanic acid 875mg/125mg (Bial®, Portugal), twice a day for 7 days), nonsteroidal anti-inflammatory treatment (Ibuprofen 600mg (Abbott® Laboratórios, Lda, Portugal), twice a day for 5 days), and analgesics (Paracetamol-Codein phosphate 500mg/30mg (Bene Farmacêutica®, Portugal), according to individual needs. A twelve months follow-up was done by a clinical controle and panoramic radiographs.

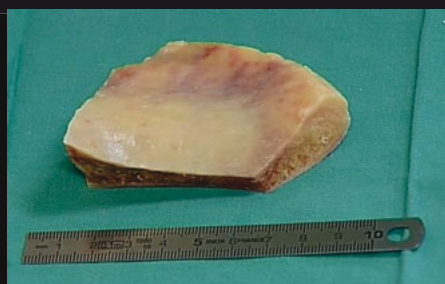STAGE I



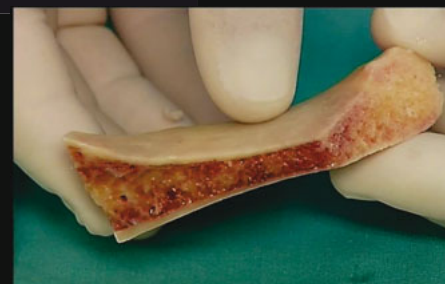Pre-op CT scan image, evidenced by the residual severe atrophic ridge.



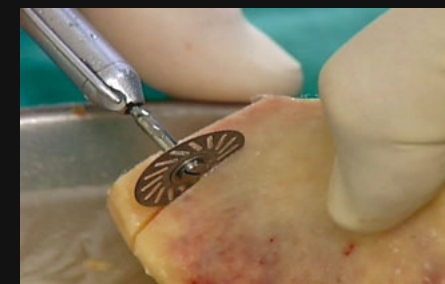A preoperative CT scan radiograph. Note the bony ridges shaped in knife edge.



Fresh-frozen Bone from iliac crest. Bone and Tissue Bank of University of Coimbra, (Iliac : 6,5cm X 4,5cm, 40gr).



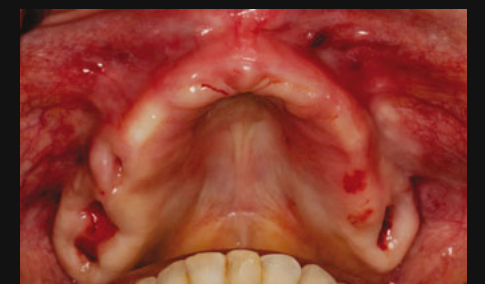The cortico-cancellous FFB from iliac crest.



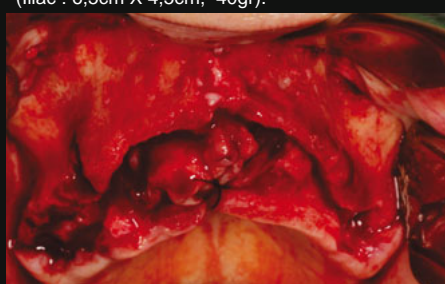Preparing the FFB with rotary instruments.



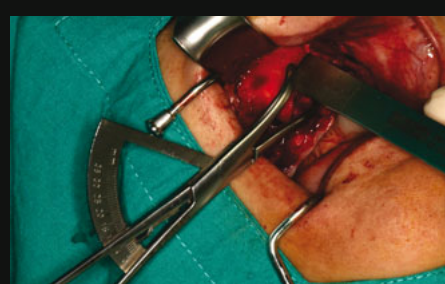Iliac FFB strips submerged in a vancomycin solution.



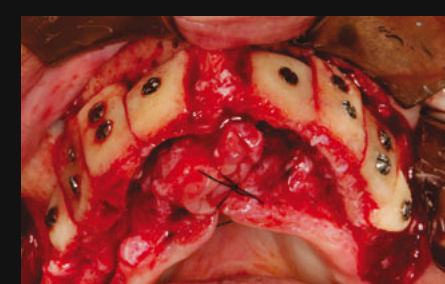
Intraoral view of the at the initial phase (stage I).



Intraoperative view of the accentuated maxillary ridge resorption, exposing the horizontal defect.

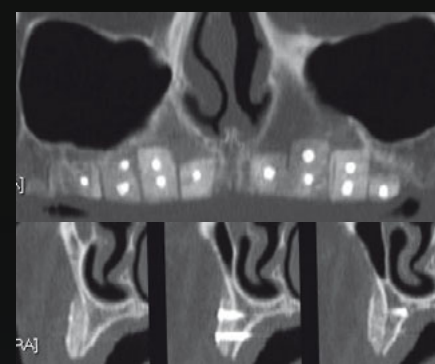


Residual alveolar ridge was measured before and after placing the blocks, with a dial caliper

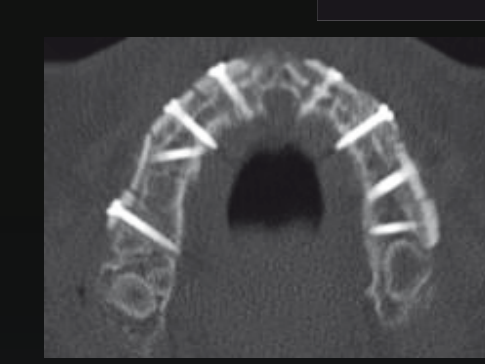

Intraoperative view with the arrangement of FFB blocks showing good contour and good stability at the recipient site using the micro-screws.

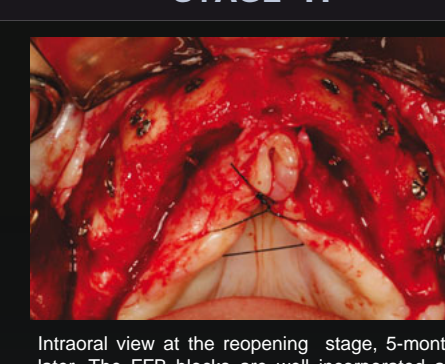
STAGE II



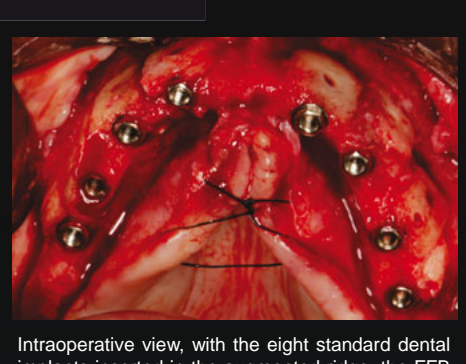
Panoramic and CT scan showing the FFB blocks well incorporated, before implant placement.



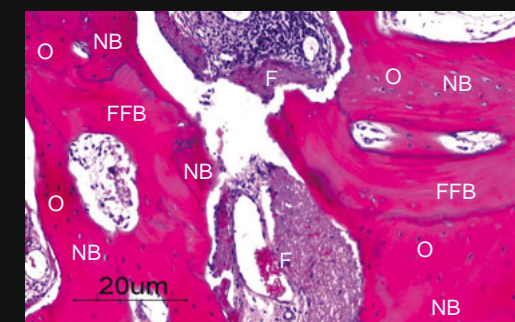
CT scan showing the FFB blocks at 5-months healing period.



Intraoral view at the reopening stage, 5-months later. The FFB blocks are well incorporated and shows no marginal bone resorption.

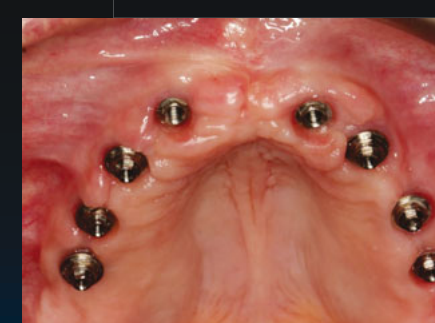

Intraoperative view, with the eight standard dental implants inserted in the augmented ridge, the FFB blocks showed good vascularization and present the cortical buccal plate covering the implant.

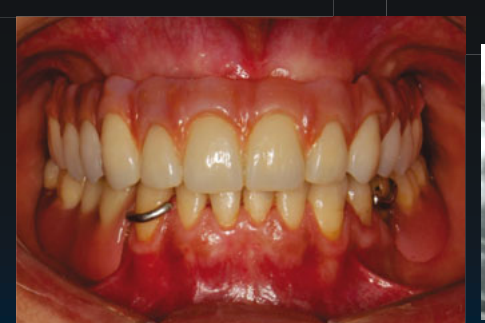

Well incorporation of the FFB block at 5-months. Evidenced by newly formed bone (NB) with viable osteocytes (O), residual FFB particles (FFB) without osteocytes, and well-vascularized fibrotic tissue (F) (hematoxylin-eosin stain; original magnification X100).

REHABILITATION

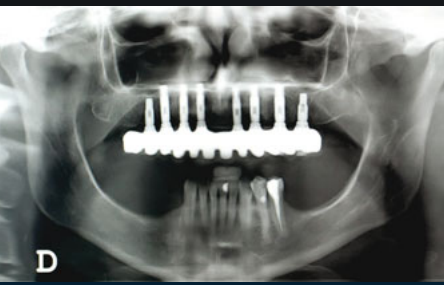

Intraoral view with evidence of good tissue healing.



Final restoration.

FOLLOW-UP 12 MONTHS



Twelve months follow-up panoramic radiograph, showing implant-supported restorations.

RESULTS

During the re-entry procedures, all the blocks were found to be firm in consistency, well-incorporated and vascularized, with minimal resorption, allowing the installation of eight implants. Histologic evaluation revealed rapid incorporation of the FFB blocks at 5-months, as evidenced by newly formed bone surrounding the residual allograft and containing viable osteocytes. There were no post-operative complications. After twelve months, the implant-supported rehabilitation was in perfect function and none of the implants were lost.

DISCUSSION

The reconstruction with *onlay* bone blocks, provides better outline and resistance to implant placement. The phenomenon of osteoconduction is well illustrated at the histologic sample, which found newly formed bone surrounding FFB cancellous fragments. The application of fresh-frozen bone blocks allografts allowed good adaptation to the recipient site, reduced operative time, less morbidity, greater availability, security implementation and patient comfort compared to the application of autografts.

CONCLUSION

Bone reconstruction by the application of fresh-frozen allogeneic bone blocks under local anesthesia by applying the *onlay* technique has been shown to be a suitable alternative to the use of autografts, in bone reconstructions at a short period of time. Future studies using FFB, especially with long-term follow-up, are needed to learn about the behavior of this allogeneic material after longer periods of function.

REFERENCES

- Talgren A. The continuing reduction of the residual alveolar ridges in complete denture wearers: A mixed-longitudinal study covering 25 years. *J Prosthet Dent*. 2003;89(5):427-35.
- Cawood JI, Howell RA. A classification of the edentulous jaws. *Int J Oral Maxillofac Surg*. 1988;17(4):232-6.
- Collins M, James DR, Mars M. Alveolar bone grafting: A review of 115 patients. *Eur J Orthod*. 1998;20:115-120.
- Mish CM. Autogenous bone grafting for dental implants. In: Fonseca RJ, Turvey TA, Marciani RD, editors. *Oral and maxillofacial surgery*, vol. 1. Philadelphia: WB Saunders Co; 2008. P. 344-70. Chapter 24.
- Mitch CM. Comparison of intracranial donor sites for onlay grafting prior to implant placement. *Int J Oral Maxillofac Surg*. 1997;26(7):757-76.
- Pikos MA. Mandibular block autografts for alveolar ridge augmentation. *Atlas Oral Maxillofac Surg Clin North Am*. 2005;13(2):91-107.
- Younger EM, Chapman MW. Morbidity at bone graft donor sites. *J Orthop Trauma*. 1989;3:192-5.
- Carrizo F, Brunelli G, Franzo M, Viscioni A, Rigo L, Guis R, et al. A retrospective study on 287 implants installed in resorbed maxillae grafted with fresh frozen allogeneous bone. *Clin Implant Dent Relat Res*. 2010;12(2):91-8.
- Neovius E, Engstrand T. Craniofacial reconstruction with bone and biomaterials: review over the last 11 years. *J Plast Reconstr Aesthet Surg*. 2009; 20:1-9.
- Nissan J, Romanos GE, Mardinger O, Chausu G. Immediate nonfunctional loading of single-tooth implants in the anterior maxilla following augmentation with freeze-dried cancellous block allograft: a case series. *Int J Periodontics Restorative Dent*. 2008 Oct;28(5):509-15.
- Peirangano PS, Amar S. Localized ridge augmentation with allogeneic block grafts prior to implant placement: case reports and histologic evaluations. *Implant Dent*. 2005;14(2):139-48.
- Sarone A, Vitarani P, Orlando B, Tonelli P, Covani U. Deep-frozen allogeneic onlay bone grafts for reconstruction of atrophic maxillary alveolar ridges: a preliminary study. *J Oral Maxillofac Surg*. 2009;67(6):1300-6.
- Contar CMM, Sarot JR, Bordin J, Galvão GH, Nicolai GV, Machado MAN. Maxillary ridge augmentation with fresh-frozen bone allografts. *J Oral Maxillofac Surg*. 2009;67(6):1280-5.
- Neivins M, Mellong JT. The advantages of localized ridge augmentation prior to implant placement: a staged event. *Int J Periodontics Restorative Dent*. 1994;14(2):98-111.
- Okanen K, Sándor GKB, Kainulainen VT, Salonen-Kemppi M. Augmentation of the narrow traumatized anterior alveolar ridge to facilitate dental implant placement. *Dent Traumatol*. 2003;19(1):19-29.
- Heberer S, Rubin B, Krekeler L, Schink T, Nelson JJ, Nelson K. A prospective randomized split-mouth study comparing iliac onlay grafts in atrophic edentulous patients: covered with periosteum or a bioresorbable membrane. *Clin Oral Implants Res*. 2009; 20(3):319-26.
- Lyford RH, Mills MP, Kraop CI, Scheyer ET, Mellong JT. Clinical evaluation of freeze-dried block allografts for alveolar ridge augmentation: a case series. *Int J Periodontics Restorative Dent*. 2003 Oct;23(5):417-25.
- Laverick S, Sumnerwell A, Cawood JI. Ten years of experience with the anterior maxillary and mandibular osteoplasty (class IV ridges): a retrospective analysis of implant survival rates. *Int J Oral Maxillofac Surg*. 2008;37(5):415-8.
- Cordaro L, Amadei DS, Cordaro M. Clinical results of alveolar ridge augmentation with mandibular bone grafts in partially edentulous patients prior to implant placement. *Clin Oral Implants Res*. 2002;13(1):103-11.

Keywords: Bone blocks, *onlay* technique, bone allografts, cortico-cancellous, horizontal bone defects, recipient site.

Presented at the 23th PORTUGUESE DENTAL ASSOCIATION ANNUAL MEETING
06,07,08 November 2014, Lisboa, Portugal