

CAMLOG and CONELOG implants with LOCATOR attachment retained dentures in the treatment of total edentulism

Study of 11 cases

DEDEOGLU R. K.

ATADENT Dental Clinic - Private Practice- ISTANBUL / TURKEY Dr., DDS keremdedeoglu@atadent.com.tr

Introduction

Implant-supported overdentures with retentive attachments are reliably being used in the treatment of restoring complete edentulism in daily practice. There are different approaches regarding the number of implants required and type of connectors to achieve satisfactory retention and stability, however, placing a minimum of 4 implants in the maxilla and placing 2-4 implants in the mandible can be regarded as a widely preferred treatment approach by the clinicians. The aim of this case study is to present 11 edentulous cases with Locator attachments applied on Camlog/Conelog dental implants and share prosthetic and retentive attachment related complications for a mean follow up period of 38 months.

Materials & Methods

Total of 78 (62 Camlog and 16 Conelog) implants at 11 cases (2 female and 9 male)

- 8 cases with 4 implants in each jaw
- 2 cases with 4 implants in the maxilla and 2 in the mandible
- 1 case 2 implants in the mandible only

Locator (Zest Anchors) attachment supported final dentures applied after 12 and 6 weeks for the maxilla and mandibula, respectively .

Follow ups at every 6 months for implant or prosthetics related complications.

Mean follow period of 38 months

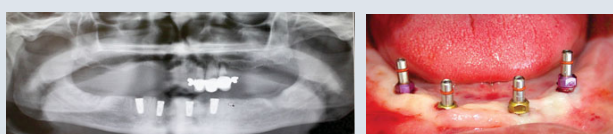


Fig.1 Post-op OPT

Fig.2 4 implants are inserted by flapless surgery

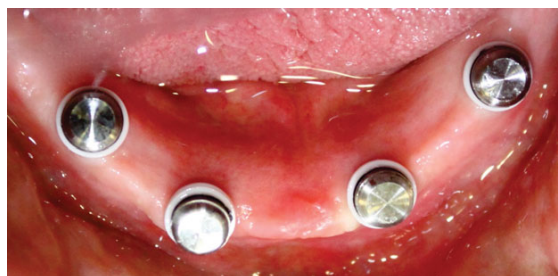

Fig. 3 Metal housings and undercut blockers seated on LOCATORS prior to chairside fixation

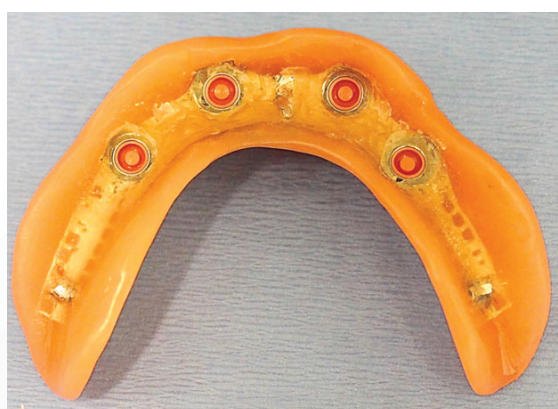

Fig. 4 Pink males (retention force 3 lbs) inserted in metal housings



Results

- At the first 6 month follow up appointment, 3 cases presented plaque formation inside the gap which is designed to act as a retentive factor at the top of the Locator attachment.
- No complications regarding the dentures were encountered.
- No complications regarding implant survival nor loosening of the Locator attachments were noted.
- The patients presented high positive feedbacks regarding the denture stability by means of function and comfort. Weakening of denture stability due to plastic male parts' wear at 6 month follow-ups were encountered as expected and resolved by replacing the plastic cap in the metal housing as provided.

Gender	No of imp maxilla	No of imp mandible	Follow up months	Complications	No of plastic part change
F	4	4	26	Plaque on attachment	4
F	4	4	42	-	7
M	4	4	44	-	7
M	4	4	43	-	7
M	4	4	32	Plaque on attachment	5
M	4	4	32	-	5
M	4	4	46	-	7
M	4	4	48	-	8
M	4	2	36	-	6
M	4	2	36	-	6
M	0	2	40	Plaque on attachment	6
TOTAL	40	38	Mean 38.6		

Table 1 Study summary table

Conclusions

- Locator attachments presented effective function as retentive agents for dentures in the treatment of total edentulism for a follow up period of 38 months.
- Replacement of the retentive plastic caps every 6 months resolved the stability weakening due to plastic parts' wear and were well tolerated by the patients for this study.
- Plaque accumulation at the top of the attachment seemed to be the most important complication in 3 cases' first follow up appointments. The patients should be carefully informed in detail about the manual cleaning of the attachment in order to obtain the best retentive results for Locator attachments due to their circular gap-like design acting as a supporting mechanism to retention at the top of the attachments.
- Locator abutments presented easy handling to the clinician for chair side denture application.
- Locator abutments were found to be easy in seating and removing the denture by the patients, thus being user friendly.
- Studies with longer term survival rates comparing alternative abutment systems are necessary and will be more effective in stating definite conclusions in the favour of any retentive anchorage system for the rehabilitation of total edentulism.