

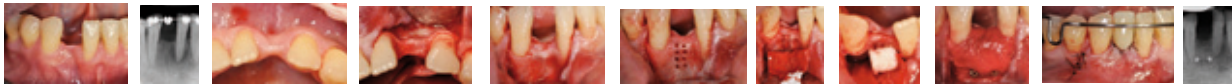
# Lateral Ridge Augmentation before implant placement in deficient lower anterior ridges. *Case Report*

Lopez F\* DDS

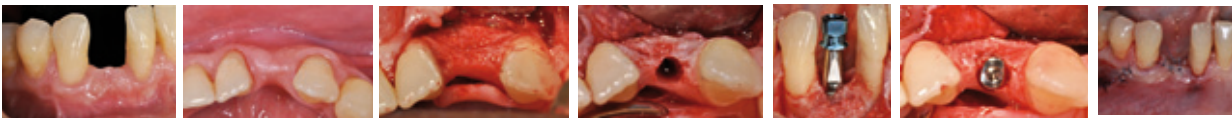
**Abstract:** Atrophic lower anterior ridges after tooth extraction appear to be a contraindication for implant therapy. The present case report will follow the use of Anorganic Bovine Bone Marix (ABBM) in order to augment the knife - edge sites before implant placement

**Methods:** A 57 year old patient consulted for a solution at regio 42, where the tooth was extracted more than 5 years ago. Initial Cone Beam Tomography (CBT) was taken determining the lack of anterior-posterior bone volume (2mm) for implant placement. A full thickness flap was performed to expose bone tissue and to perforate corticalis to provide blood combine with the ABBM graft (Bio-Oss Collagen) and the fixation of a collagen membrane (Bio-Gide) with titanium mini screws (x2). The ABBM was carefully stabilized, covered with the collagen membrane and the sutured with 6-0 nylon. The patient was handled with antibiotics and analgesics for 7 days and 10 days post surgery sutures were removed. An implant is scheduled to be installed 6 months after the initial guided bone regeneration procedure. The patient held an orthodontical space maintainer including the missing tooth 42 during the initial healing phase up to the healing screw installation and a CBT was taken as control. Second phase (re-opening) was performed 3 months after the implant placement and Healing Screw was installed, allowing the soft tissue ready for Prosthetic procedure.

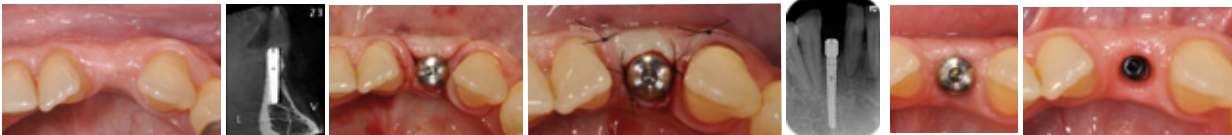Day 1



Month 6



Month 9



**Conclusions:** Localized lateral bone augmentation in compromised lower anterior ridges appear to be predictable with the use of ABBM and a collagen membrane. The importance of the stabilization of the collagen membrane with titanium mini-screws shall be important in the final outcome.