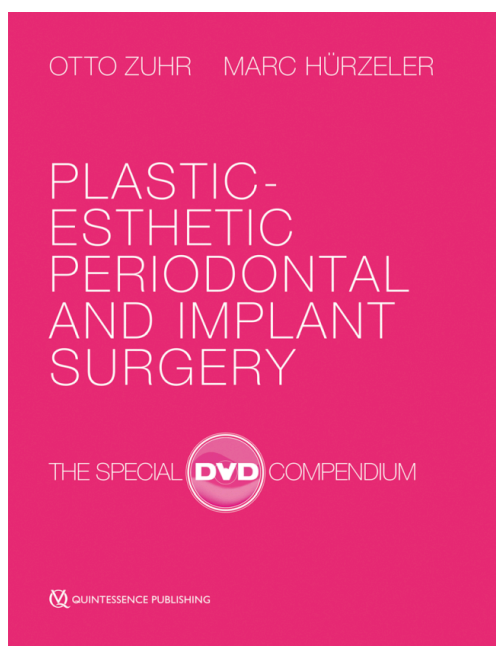




Auflage: 2. Auflage 2016
Einband: 4 DVDs with 10 videos in a box, Runtime: 08:05 hours
ISBN: 978-1-85097-294-5
Artikelnr.: C3110
Erschienen: Februar 2016

Plastic-Esthetic \$175.00
Periodontal and
Implant Surgery DVD
Set
Volume 1 \$35.00
Volume 4 \$35.00
Volume 5 \$35.00
Volume 6 \$35.00
Volume 7 \$35.00
Volume 8 \$35.00
Volume 9 \$35.00
Volume 10 \$35.00

Änderungen vorbehalten!

Quintessence Publishing Company, Inc.

 411 North Raddant Road
Batavia
Illinois IL 60510
Vereinigte Staaten von Amerika

 +1 (0)630 / 736-3600

 +1 (0)630 / 736-3633

 contact@quintbook.com

 <https://www.quintessence-publishing.com/usa/en>

Produkt-Information

Autoren: Otto Zuhr / Marc Hürzeler
Titel: Plastic-Esthetic Periodontal and Implant Surgery
Untertitel: The Special DVD Compendium
Kurztext:

These high-definition DVDs showcase the exceptional minimally invasive microsurgical techniques featured in the best-selling book. Surgical procedures are performed by the authors and explained with commentary to clarify the surgical technique and sequencing. This compact DVD compendium, featuring all 10 surgeries on 4 DVDs, comes in a handy slipcase with an accompanying booklet.

Film 1: Autograft Harvesting

The vast majority of procedures in plastic-esthetic periodontal and implant surgery are reconstructive procedures, often carried out with autologous connective tissue and/or bone grafts. The harvesting of autologous grafts has therefore become a frequent routine procedure. This volume presents four of the most common techniques for harvesting autologous connective tissue or bone grafts.

Contents:

- Harvesting a block bone graft from the lateral mandibular angle
- Harvesting a subepithelial connective tissue graft from the lateral palate
- Harvesting a thick mucosal graft from the lateral palate
- Harvesting a subepithelial connective tissue graft from the maxillary tuberosity region

Runtime: 49:32 Min.

Film 2: Gingival Augmentation with Autologous Connective Tissue

Thin marginal soft tissues can be a risk factor leading to gingival recession. It is therefore appropriate in certain clinical situations to augment the marginal gingiva with connective tissue autografts. This volume presents a modified tunnel technique without incision for gingival augmentation.

Contents:

- Tunneling preparation of a split-thickness flap in the area of the buccal soft tissues
- Harvesting a subepithelial connective tissue graft from the lateral palate
- Inserting the connective tissue graft and suturing

Runtime: 29:02 Min.

Film 3: Singular Gingival Recession Coverage

Many people are affected by gingival recession. This is one of the main reasons why a large number of surgical techniques have been described for treating such mucogingival lesions. These differ in not only how the incision is made and how the flap is prepared, but also—very importantly—in whether the mobilized soft tissue is moved to a different position and whether this is carried out by itself or in combination with other measures, such as a connective tissue graft. This volume presents three of the most commonly-used methods for covering singular gingival recession areas.

Contents:

- Coverage of a singular recession with the coronal advancement flap technique and autologous connective tissue
- Coverage of a singular recession with the double lateral advancement flap technique and autologous connective tissue
- Coverage of a singular recession using a modified tunneling technique and autologous connective tissue

Runtime: 63:28 Min.

Film 4: Multiple Gingival Recession Coverage

Many people are affected by gingival recession. This is one of the main reasons why a large number of surgical techniques have been described for treating such mucogingival lesions. These differ in not only how the incision is made and how the flap is prepared, but also—very importantly—in whether the mobilized soft tissue is moved to a different position and whether this is carried out by itself or in combination with other measures, such as a connective tissue graft. This volume presents two of the most frequently recommended methods for covering multiple gingival recession areas.

Contents:

- Coverage of multiple recessions with the coronal advancement flap technique and enamel matrix proteins
- Coverage of multiple recessions using a modified tunneling technique and autologous connective tissue

Runtime: 47:08 Min.

Film 5: Esthetic Crown Lengthening

To obtain harmonious gingival contours in the anterior jaw, esthetic crown lengthening may be indicated for natural or restored teeth. If a sufficient height of keratinized tissue is present, this is done by performing an external gingivectomy, either with or without ostectomy depending on the height of the dentogingival complex. If the width of the keratinized gingiva is insufficient, an apical repositioning flap is required. This volume presents the two approaches for esthetic crown lengthening.

Contents:

- External gingivectomy
- External gingivectomy and ostectomy

Runtime: 37:52 Min.

Film 6: Horizontal Papilla Augmentation with Autologous Connective Tissue

The loss of papillae can be localized or generalized, and the resulting compromised esthetics can be a great burden for patients. While the vertical reconstruction of papillary defects is not currently considered a predictable surgical procedure, enlarging the papillary volume surgically in a horizontal direction may well be feasible. This volume presents a clinically proven technique for horizontal papilla augmentation.

Contents:

- Tunneling preparation of a split-thickness flap in the area of the interproximal soft tissues to be augmented
- Harvesting a subepithelial connective tissue graft from the maxillary tuberosity region
- Inserting the connective-tissue graft and suturing

Runtime: 17:23 Min.

Film 7: Management of Extraction Sockets

The resorption of periodontal hard and soft tissues adjacent to extraction sockets as a result of remodeling following tooth extraction represents a major treatment challenge in the esthetic zone. To counteract these processes therapeutically, numerous studies have been conducted and various techniques for socket preservation discovered in recent years. This volume presents measures for ridge prophylaxis that take into account the insights gained from these studies, addressing one- and two-stage implant procedures, as well as bridges.

Contents:

- Ridge prophylaxis for one-stage implant-supported bridges
- Ridge prophylaxis for one-stage implant-supported crowns

- Ridge prophylaxis using the socket seal technique in incremental implant-supported crown and bridge procedures

Runtime: 77:26 Min.

Film 8: Soft Tissue Augmentation Under Bridge Pontics

In the context of fixed dental prostheses, for esthetic and hygienic reasons it may be advisable to perform horizontal soft tissue augmentation using connective tissue taken from the lateral palate, or from the tuberosity region. From a clinical perspective, there are two proven techniques: the inlay technique can achieve horizontal augmentation of the alveolar crest and cause thickening of the papillae adjacent to the edentulous space. To cover the graft completely, an additional palatal island flap is recommended. Alternatively, pouch techniques have proven successful where pockets are prepared by undermining and connective tissue grafted into these pockets. A modification of the procedure allows the soft tissue to be concurrently contoured by the pontics of the provisional bridge. This volume presents both techniques.

Contents:

- Modified pouch technique
- Inlay technique and palatal island flap

Runtime: 62:14 Min.

Film 9: Defect Reconstruction and Concurrent Implant Placement

Simultaneous implant placement at the time of augmentation is preferable to a twostep procedure, because of the shorter treatment time and greater patient comfort. In the presence of a Class I defect, a reconstruction with particulate autologous or xenogeneic bone substitute and a corresponding barrier (modified double-layer technique) can be achieved. The cortical plate technique is particularly suitable for eliminating vertical aspects of the defect. This volume illustrates both techniques.

Contents:

- Horizontal defect reconstruction and simultaneous implant placement using the modified double-layer technique
- Vertical defect reconstruction and simultaneous implant placement using the cortical plate technique

Runtime: 59:42 Min.

Film 10: Implant Placement Using a Modified Roll Flap Technique

When placing an implant in the esthetic zone, it is often necessary to address persisting tissue deficits by appropriate soft-tissue augmentation procedures. This volume presents a modified roll flap technique, an incision-free entry procedure that combines a modified roll flap with a tunneling approach to build volume horizontally in the area of the buccal soft tissue.

Contents:

- Deepithelialization and roll flap elevation
- Tunneling preparation of a split-thickness flap in the area of the buccal soft tissues
- Rotation of the roll flap, and delivery of the temporary abutment and suturing

Runtime: 16:55 Min.

Fachgebiet(e): [Implantologie, Oralchirurgie, Parodontologie](#)