



SMILE MODIFICATION IN ODONTOPEDIATRICS MINIMAL INVASIVE ESTHETIC SOLUTION FOR A COMPLEX CASE

Bernardino D^{1*}, Velha L¹, Braga R¹, Almeida CF², Figueiredo A³

1 - Integrated Master's Degree Student in Dental Medicine, Institute of Health Sciences of Viseu, Universidade Católica Portuguesa

2 - Guest Assistant, Institute of Health Sciences of Viseu, Universidade Católica Portuguesa, Center for Interdisciplinary Research in Health - Universidade Católica Portuguesa

3 - Assistant Professor, Institute of Health Sciences of Viseu, Universidade Católica Portuguesa, Center for Interdisciplinary Research in Health - Universidade Católica Portuguesa



INTRODUCTION

The presence of diastema in the region of maxillary central and lateral incisors is considered a highly detrimental anesthetic factor from the social point of view.(1) They can compromise the aesthetics of the smile substantially in function of its extension.(2-3)

Its etiology is multifactorial and should be judged with caution and according to the patient so that the correct treatment is performed and completed successfully.(4-6)

CLINICAL CASE DESCRIPTION

A 15 year old female patient, healthy and institutionalized in a foster care, came to an appointment of Pediatric Dentistry at the Dental Clinic of the University UCP-Viseu, under the "Pequenos Grandes Sorrisos" social program referring a discomfort in the 2nd quadrant. In performing the anamnesis, it was verified that the patient had an Attention Deficit Hyperactivity Disorder and psychological problems with her smile.

At the oral examination, agenesis of the teeth 1.2 and 2.2 was observed, with the permanence of 6.3 and a marked deviation of the upper dental middle line to the right (3mm). After extracting the 63 (urgency), tooth that caused the discomfort, a treatment plan was drawn up. The ideal treatment would pass through a bi-maxillary orthodontic treatment.

Knowing the patient's personal history and her particularities, that hypothesis had to be excluded. Was then proposed to perform a coronoplasty of the canines and increase of the central incisors. For planning were performed: photographic status, study models and occlusal recording (Oclufast, Zhermack, Germany). Afterwards was done a Digital Smile Design and sent to the laboratory for the diagnostic waxing. The mock-up (CoolTemp, Coltène, Switzerland) was realized for a aesthetic, functional and phonetic evaluation, it was also an important step for the behavioral motivation of the patient during the next treatment. Later, an application of orthophosphoric acid and adhesive was applied (One Coat Bond, Coltène, Switzerland). The final restorations in composite resin (Synergie D6, Coltène, Switzerland) were performed using color A1 and U, with the support of a transparent silicone mold (RegistradoClear, VOCO, Germany).

At the control visit, the finishing of the interproximal and cervical regions was improved. Then a complete finishing and polishing protocol was applied initially with polishing discs (Soflex 3M, 3M, EUA), rubbers (ShapeGuard Coltène, Switzerland), goat hair disc with polishing paste (Shiny C, Micerium, Italy) and felt disc with polishing paste (Enamelize, Cosmedent, USA).

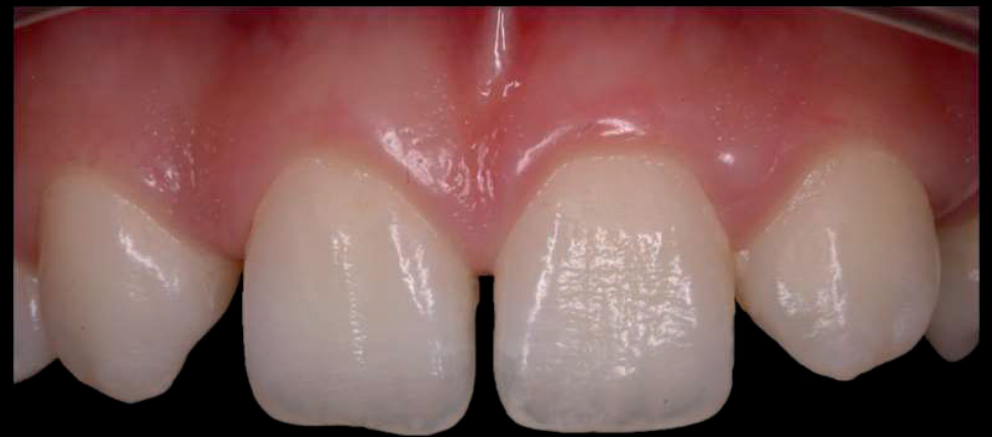

Image 1: Initial Intraoral oral photography

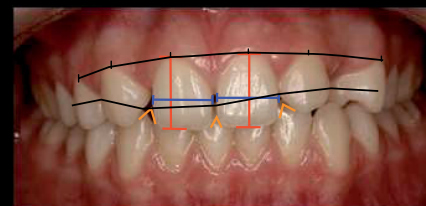


Image 2: Digital Smile Design smile analysis

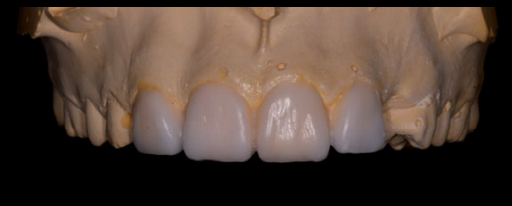

Image 3: Diagnostic waxing



Image 4: Silicone matrix

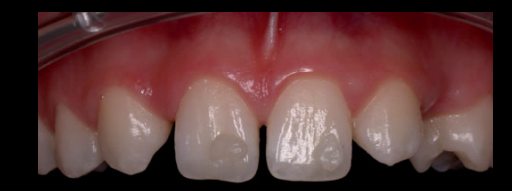

Image 5: Colour selection

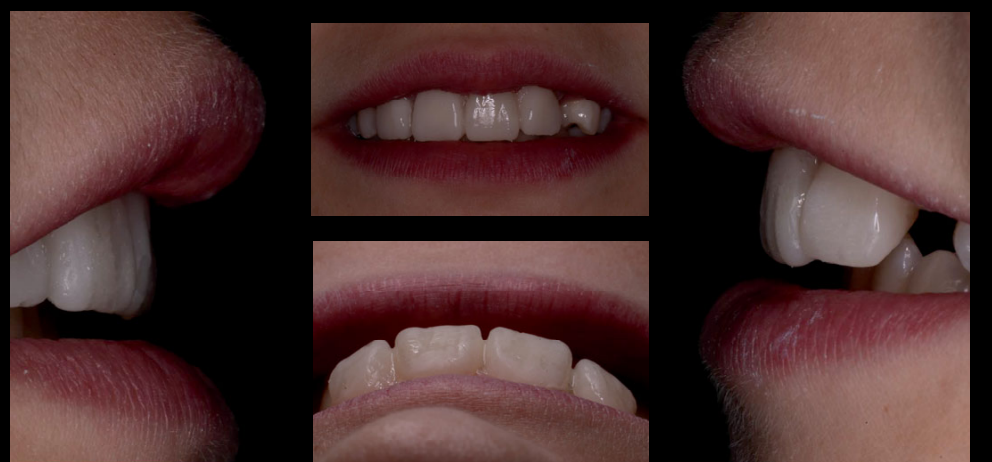

Image 6, 7, 8, 9: Final extra-oral photographs

DISCUSSION

The orthodontic treatment would last at least 2 years. The patient was looking for a quick and economical solution. Coronoplasties with individualized mock-ups can easily solve some questions, particularly in the field of aesthetics in Pediatric Dentistry.

In this way we were able to solve a situation that caused discomfort and psychological problems to the patient despite the limitations that exist.(4-5)

CONCLUSION

The treatment plan must be molded to each patient. His limitations must be a motivation according the patient's objectives.

BIBLIOGRAPHY

1. Paschoal MA, Santos-Pinto L, Nagle M, Ricci WA. Esthetic and function improvement by direct composite resins and biomimetic concept. J Contemp Dent Pract 2014; 15(5):654-658.

2. Guerra M, Venância G, Augusto C. Fechamento de diastemas anteriores com resina composta direta: relato de caso. Rev Assoc Paul Cir Dent 2016;70(3):317-22.

3. Shaw WC. The influence of children's dentofacial appearance on their social attractiveness as judged by peers and lay adults. Am J Orthod. 1981;79:399-415.

4. Paschoal MA, Santos-Pinto L, Nagle M, Ricci WA. Esthetic and function improvement by direct composite resins and biomimetic concept. J Contemp Dent Pract 2014; 15(5):654-658.

5. Barbosa TS, Gavia o MBD. Oral health-related quality of life in children: Part II. Effects of clinical oral health status. A systematic review. Int J Dent Hygiene 6, 2008; 100-107

6. Kabbach W, Sampaio CS, Hirata R. Diastema closures: A novel technique to ensure dental proportion. J Esthet Restor Dent. 2018;30:275-280.