



# Effects of Immediate and Delayed Canine Retraction after Premolar Extraction

Nawaporn Ritwiroon, Boonsiva Suzuki, Eduardo Yugo Suzuki  
Department of Orthodontics, Faculty of Dentistry, Bangkokthonburi University, Thailand



## Introduction

Based on the regional acceleratory phenomenon (RAP) concept, surgical procedures are suggested to enable faster tooth movement.<sup>1,2</sup> Tooth extraction is one surgical procedure that may induce RAP.<sup>3</sup>

A previous study has shown that immediate canine retraction after premolar extraction provides a faster rate of canine movement.<sup>4</sup> However, the effects of immediate canine retraction and delayed retraction using 50 gf have never been evaluated.

## Aim of Study

To evaluate and compare the rate and change in angulation of canine distal movement between immediate and delayed canine retraction.

## Materials and Methods

A total of 40 canines which had been retracted with 50 gf into premolar extraction site were included in this study. The date of maxillary first premolar extraction and canine retraction of each patient were recorded and used to categorise the data into immediate retraction and delayed retraction for 1 to 4 weeks (Figure 1).

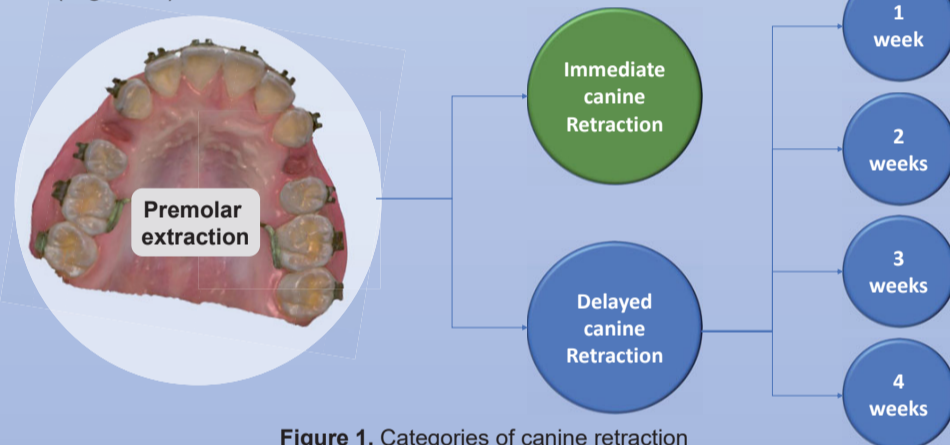


Figure 1. Categories of canine retraction

Before (T0) and after complete canine retraction (T1), 3D digital models (Figure 2) and lateral cephalograms (Figure 3) were recorded and measured.

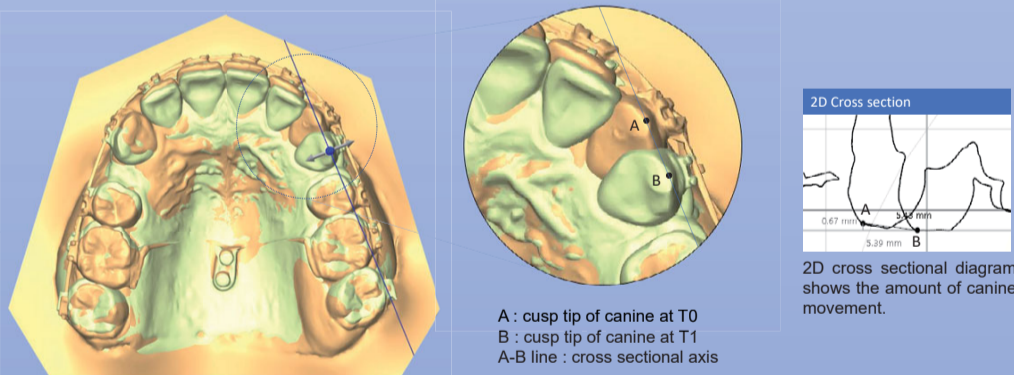


Figure 2. Measurement of tooth movement. Palatal miniscrews were used as a reference for model superimposition. The distance between the cusp tips of the canines at T0 and T1 was measured. The amount of canine movement is shown in the 2D cross-sectional diagram. The rate of canine movement per month was calculated from the total movement and duration of the canine retraction.

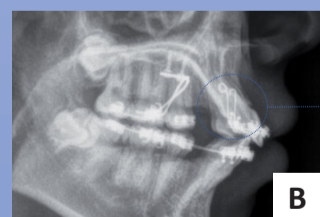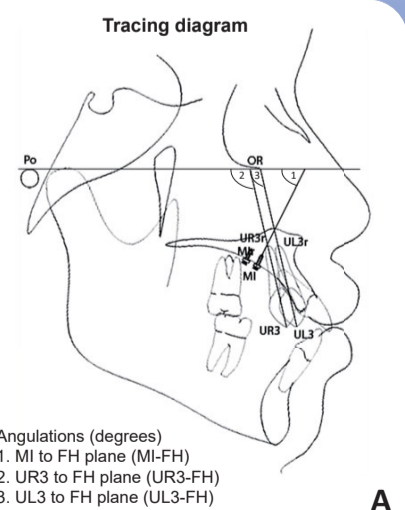


Figure 3. A: The tracings of lateral cephalograms (T0 and T1) were measured as shown in the diagram. The MI-FH angle was used to calibrate the FH plane on T0 and T1 tracings. The change in canine angulation was calculated from the UR3-FH and UL3-FH angles on T1 and T0 tracings. B: Lateral cephalogram shows the canine guiding jigs.

The rate of movement and change in angulation of each group were compared using one-way ANOVA and multiple comparisons.

## Results

The mean rate of canine movement was  $0.98 \pm 0.28$  mm/month. The mean change in angulation was  $6.01 \pm 4.01$  degrees (Figure 4 and Table 1). The rates of movement and change in angulation of the canines retracted immediately or those retracted after a delay of 1 to 4 weeks were not significantly different (Figures 5 and 6).

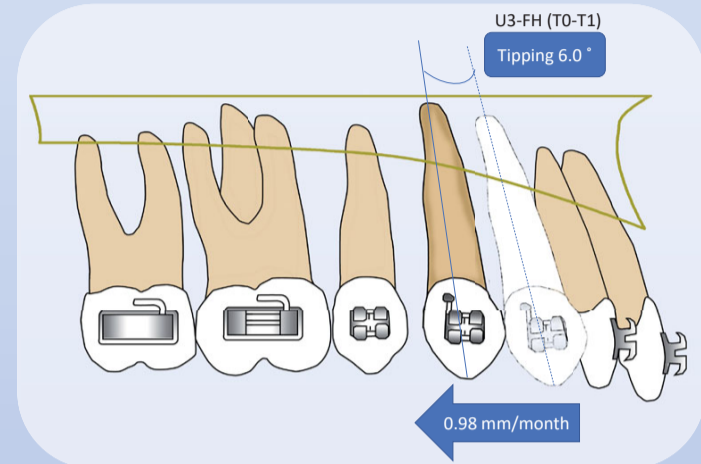


Figure 4. Diagram of canine movement following retraction with 50 gf within 4 weeks after premolar extraction

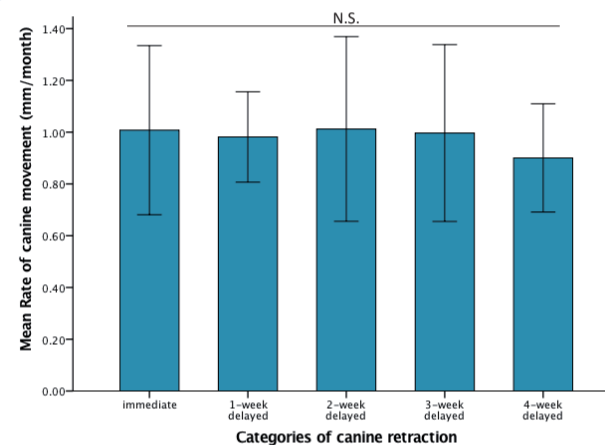


Figure 5. Mean rate of canine movement (mm/month)  
N.S. = not significantly different  
Error Bar : +/- 1 SD

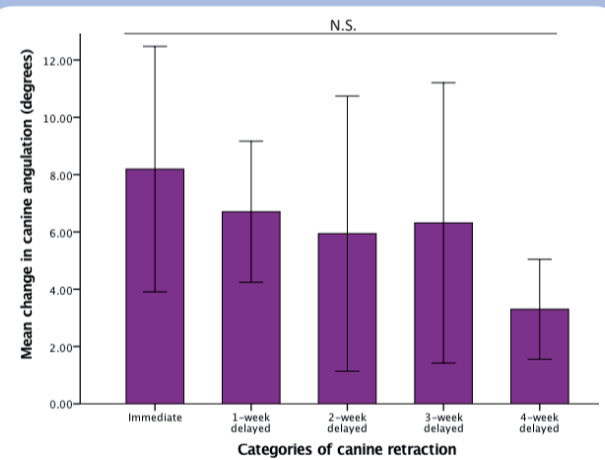


Figure 6. Mean of change in canine angulation (degrees)  
N.S. = not significantly different  
Error Bar : +/- 1 SD

## Discussion

The rate and change in angulation of canine movement in this study were less than those in a previous study which used 100 gf.<sup>4</sup> However, the movement rate was higher than that achieved in another study with delayed retraction of more than 3 months using 50 gf.<sup>5</sup>

Moreover, there was no significant difference in the rate and type of tooth movement between immediate retraction and delayed retraction for 1 to 4 weeks. Therefore, starting canine retraction can be delayed for 4 weeks to achieve the same results, to avoid applying force while the patient may be experiencing bleeding and discomfort after premolar extraction. However, the effects of delayed retraction of more than 4 weeks is still unknown. We suggest that further study should be performed to determine the difference.

## Conclusion

Immediate canine retraction and delayed retraction for 1 to 4 weeks after premolar extraction were not significantly different in the rate and type of tooth movement.

## References:

- Wilcko WM, Wilcko T, Bouquot JE, Ferguson DJ. Rapid orthodontics with alveolar reshaping: two case reports of decrowding. *Int J Periodontics Restorative Dent* 2001;21(1):9-19.
- Hoogeveen EJ, Jansma J, Ren Y. Surgically facilitated orthodontic treatment: a systematic review. *Am J Orthod Dentofacial Orthop* 2014;145(4 Suppl):S51-64.
- Verna C. Regional Acceleratory Phenomenon. *Front Oral Biol* 2016;18:28-35.
- Hasler R, Schmid G, Ingervall B, Gebauer U. A clinical comparison of the rate of maxillary canine retraction into healed and recent extraction sites—a pilot study. *Eur J Orthod* 1997;19(6):711-9.
- Yee JA, Turk T, Elekdag-Turk S, Cheng LL, Darendeliler MA. Rate of tooth movement under heavy and light continuous orthodontic forces. *Am J Orthod Dentofacial Orthop* 2009;136(2):150 e1-9; discussion 50-1.