



# Mandibular Rehabilitation With the Trefoil™ Technique Clinical Case



27º CONGRESSO  
ORDEM DOS MÉDICOS DENTISTAS  
PORTUGUESE DENTAL ASSOCIATION ANNUAL MEETING

Lucio Faria, MD (Instituto Universitário de Ciências da Saúde-CESPU)  
José Camelo Ferreira, MD (Instituto Universitário Egas Moniz)  
Alexander Salvoni, DMD, PhD (Universidade de São Paulo)  
Eugenio Miguel Pereira, DMD, PhD (Universidade de Coimbra-Faculdade de Medicina)



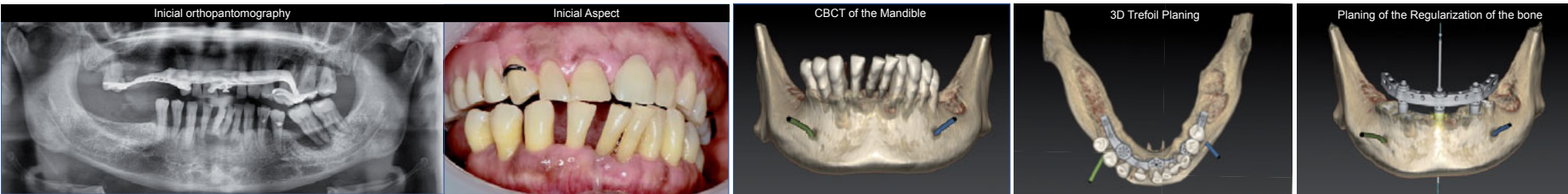
## OBJECTIVES OF THE PROCEDURE

This clinical case aims to demonstrate the clinical procedures of the application of a new implant-supported mandibular rehabilitation technique that allows the patient, with lower costs, to leave the surgery on the same day of surgery with a permanent passive prosthesis using a prefabricated titanium adaptive bar.

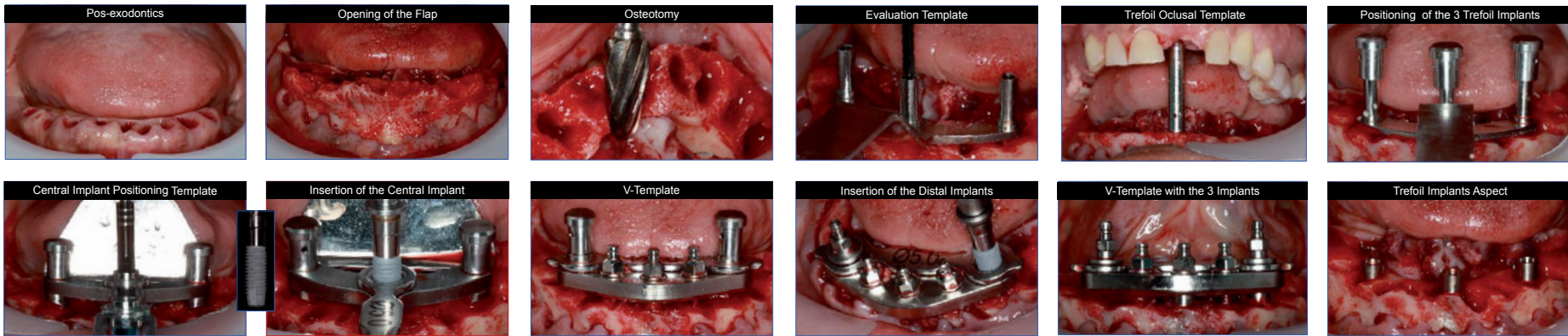
## CLINICAL CASE

A 50-year-old female patient attended the private practice with complaints of dental mobility and difficulties in chewing. After a careful intra-oral evaluation, diagnostic radiographic examinations (Orthopantomography and CBCT) were performed. It was found that all the lower teeth had a high degree of mobility (III and IV) and that any oral rehabilitation would go through total inferior extraction and posterior rehabilitation with conventional or Implant-supported prosthesis. The patient's wish was a fixed solution but there were financial limitations. After a careful 3D planning of the surgery, Trefoil™ solution was presented to the patient, based on a prefabricated titanium bar supported only by 3 implants. Initially we proceeded to take inter-maxillary registers and the vertical dimension measurement. The next day, under local anesthesia, we proceeded to the extraction of all mandibular teeth, a crestal flap was opened from seventh to seventh molar and regularization of mandibular bone according to 3D planning. Then, using the guide surgical technique we placed the central implant between mental foramina and made the initial holes for each implant. We confirmed the vertical dimension with the Trefoil™ Occlusal Guide and proceeded to the placement of the central implant, according to the surgical guidelines protocol established for the technique. The placement of the 2 distal implants was followed with the use of a V-Guide. Three Trefoil™ Implants of 5x13mm were used with a polished collar of 4.5mm. Confirmation of the passivity and adaptation with the Try-in Trefoil™ Bar was performed and then we did a check index with transfer abutments to obtain a first working model to fix the adaptive mechanisms of the definitive bar. Once locked, the bar is placed in the mouth and a waxed bite registration adapted to the bar was taken with vertical dimension confirmation. Then an impression of the bar itself was taken using an open tray technique. With this impression a final work model was made and the bite of wax allowed us to assemble the models in articulator for the production of the final prosthesis. After two hours we performed a teeth try in and then a definitive prosthesis was fabricated and placed successfully.

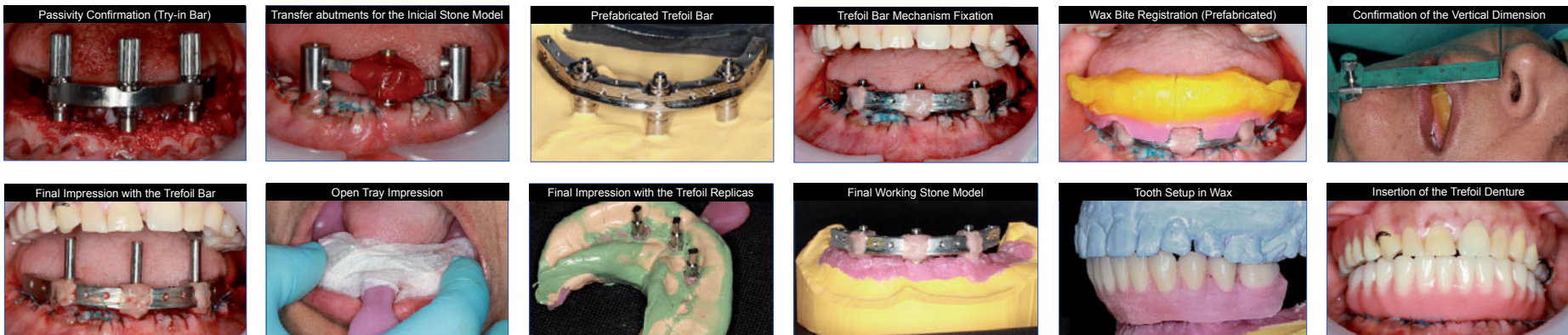## INITIAL SITUATION AND COMPUTERIZED 3D PLANNING



## SURGERY



## PROSTHETIC PHASE



## DISCUSSION

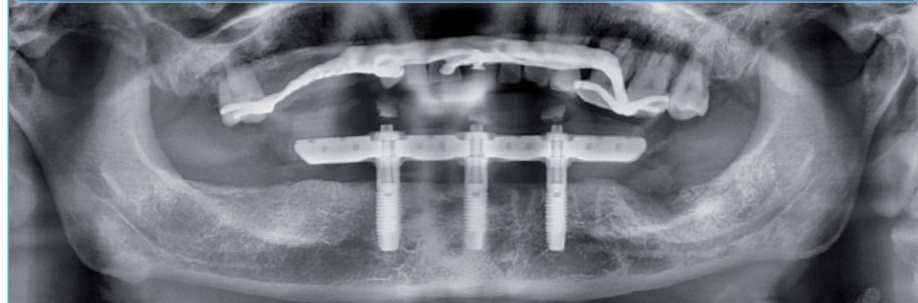
The total and immediate rehabilitation of the mandible with 3 implants using a prefabricated titanium adaptive bar is a technique with about 16 years of existence based on numerous articles and studies that prove its high success rate and the success of its bio mechanics. The key factor is the existence of a prefabricated titanium bar that allows an immediate and totally passive rehabilitation that conveys to the treatment a great predictability, from the 3D planning to the placement of the final prosthesis in the mouth and reduces the possibility of contamination to implant. Other important factors are the reduction of chair time to the patient/medical binomial and the lower number of implants used in relation to conventional techniques, which leads to a substantial decrease in final price and makes fixed implantology even more comprehensive.

## CONCLUSION

The use of only 3 implants and a prefabricated prefabricated bar for total mandibular rehabilitation is a technique already supported by numerous studies and articles since 2002. This surgical technique is effective and relatively easy to execute successfully, mainly by those who already have some practice with guided surgery. The degree of patient acceptance is very high because the technique allows the surgery and the definitive prosthesis to be performed on the same day, at the same time as the surgery.

## RESULTS

The 3 implants were placed successfully, with torques over 35 Ncm. The implants correct positioning allowed a total passivity of the prefabricated bar. At the end of 8 hours the patient left the clinic with the definitive prosthesis in immediate load.



## BIBLIOGRAPHIC REFERENCES

1- Carretta, R., Geisendorf, M., Spinner, A., Heuberger, P., Higuchi, K., and Brunski, J., *J Dent Res* 2017; 3348, 96, Special Issue A; 2- Loe H, *Sliness J Acta Odontol Scand* 1963; 21: 533-551; Mombelli, 3- A. van Oosten MA, Schurch E, Jr., Land NP. *Oral Microbiol Immunol* 1987; 2: 145-151; 4- Charette JR, Goldberg J, Harris BT, Morton D, Llop DR, Lin WS. Cone beam computed tomography imaging as a primary diagnostic tool for computer-guided surgery and CAD/CAM interim removable and fixed dental prostheses. *J Prosthet Dent*. 2016 Apr 14. pii: S0022-3913(16)00145-1; 5- Brodeur JM, Laurin D, Vallee R, Lachapelle D. Nutrient intake and gastrointestinal disorders related to masticatory performance in the edentulous elderly. *J Prosthet Dent*. 1993;70(5):468-73; 6- Feldman RS, Kapur KK, Aliman JE, Chauncey HH. Aging and mastication: changes in performance and in the swallowing threshold with natural dentition. *J Am Geriatr Soc* 1980; 28(3):97-103; 7- G. B. D. Disease Injury I, Prevalence Collaborators. Global, regional, and national incidence, prevalence, and years lived with disability for 310 diseases and injuries, 1990-2015: a systematic analysis for the Global Burden of Disease Study 2015. *Lancet* 2016;388(10053):1545-602; 8- ClinicalTrials.gov: NCT02940353. Higuchi K, et al. An adaptive prefabricated full-arch framework on three implants in the mandible- preliminary results. Oral poster presentation accepted to be presented at the 26th Annual Scientific Meeting of the European Association for Osseointegration. Saturday 7th October, 2017. IFEMA Feria de Madrid, Spain; 8- Ramesh S, Patti, V Jain, A, Gaddale, R. Immediate Implant Loading in Compromised Maxillary Partially Edentulous Arch- A Case Report. *J Clin Diagn Res* 2014 Apr; 8(4): ZD06-ZD07. <https://www.ncbi.nlm.nih.gov/pmc/articles/PMC4064926>; 9- Degidi M, Nardi D, Piattelli A. 10-Year Follow-Up of Immediately Loaded Implants with TiUnite Porous Anodized Surface. *Clin Implant Dent Relat Res* 2012; 14: 828-838; 10- Kenji Higuchi, Rubén Davó, Glen Liddelow, Massimo Albanese, and Rubén Rosenberg An adaptive prefabricated full-arch framework on three implants in the mandible: preliminary results. [dentalcongressposters.com\\_eao\\_2017\\_higuchi](https://www.dentalcongressposters.com_eao_2017_higuchi); 11- Carretta R, Geisendorf M, Spinner A, Heuberger P, Higuchi KW, Brunski JB. A Novel Prefabricated Final Fixed Solution for the Edentulous Mandible. 2017. IADR/AADR/CADR 2017 San Francisco; 12- ClinicalTrials.gov. The TREFOIL concept 5-year clinical investigation (NCT02940353). <https://clinicaltrials.gov/ct2/show/NCT02940353>. Accessed June 22, 2017. Describes the design of the ongoing 5-year study to investigate implant and prosthetic survival rates for Trefoil

Keywords: Guided Surgery; Trefoil Technique; Mandibular Immediate Load; Adaptive prefabricated Bar; Nobel Clinician; surgical guide; immediate function; CBCT; Immediate prosthesis.

Presented in XXVII CONGRESSO ANUAL da ORDEM dos MÉDICOS DENTISTAS  
8,9,10 November 2018, Porto, Portugal

