

Background

Immediate implant placement has proven to be a successful and a predictable treatment modality. Nevertheless, immediate implant placement is indicated only in cases when soft and hard tissue conditions are considered ideal at the time of implant placement. Therefore, most implant procedures in the esthetic zone necessitate pre-implant, simultaneous and/or post-implant site enhancement procedures, i.e. augmentation procedures. For this purpose, several techniques and procedures have been proposed. One of the suggested approaches is orthodontic extrusion. While this approach was originally introduced to save traumatized teeth from extraction, it has been suggested as a method to manipulate soft and hard tissues via gradual extrusion of a "hopeless" tooth and its periodontal apparatus, thereby enhancing the predictability of the implant site. A number of reports describe orthodontic extrusion as a reliable method for pre-implant site enhancement. However, no standard protocols have been provided about the application of this technique. An overview of studies available about orthodontic extrusion would enhance the knowledge about different techniques as well as provide the clinicians with guidelines that can aid in decision-making and application of this approach.

Purpose

The aim of this presentation is to provide an overview about the principles of pre-implant orthodontic extrusion, describe methods and techniques available and provide the clinicians with guidelines about its application.

Material and methods

The literature database was searched for studies involving implant site enhancement via orthodontic extrusion of teeth deemed hopeless. The search terminology included: "implant site enhancement", "implant site development", "soft tissue enhancement", "hard tissue enhancement", "orthodontic extrusion", "orthodontic extraction" and "forced eruption". Review articles, as well as references from identified studies, were also used to identify relevant articles. Information such as indications and contraindications of this method, type of anchorage, force and time were obtained from the literature. Different techniques available for this method are illustrated in the following figures.

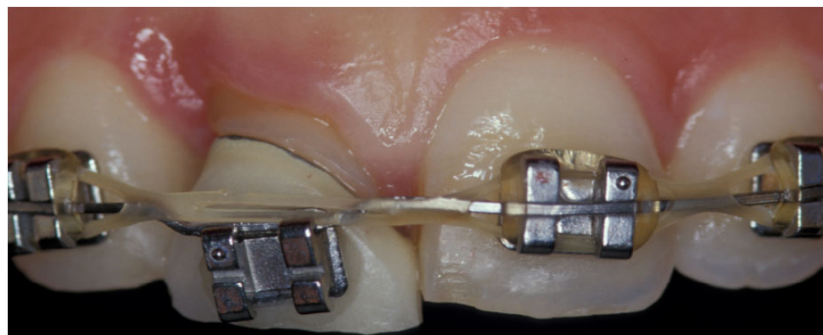


Fig.1 Clinical example of a fixed appliance for extrusion of a hopeless tooth #8.

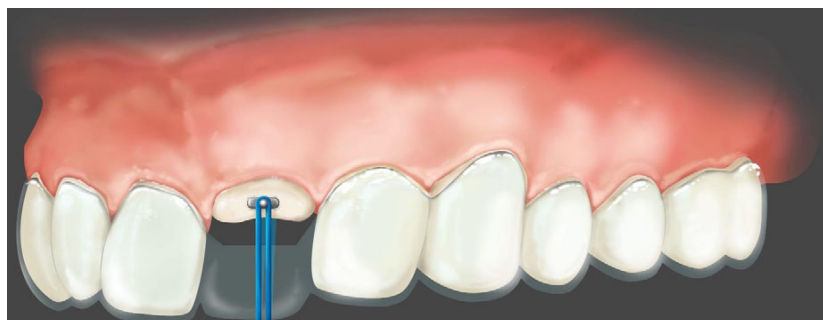


Fig.2 Example of rubber bands for orthodontic extrusion. An interocclusal appliance was used for anchorage. The patient is instructed to connect the two-cemented projecting buttons 'buccally & lingually' regularly with a rubber band.

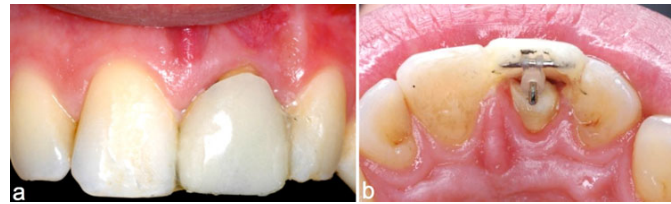


Fig.3 Combined method of a rubber band and a fixed wire used for extrusion. The rubber band runs around the wire and attaches to the hook of the cemented post.

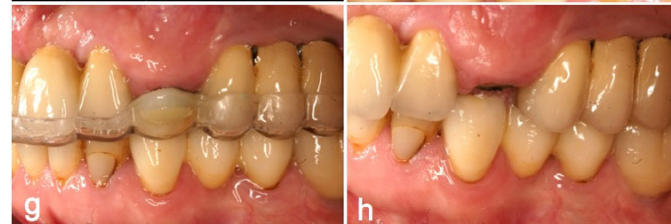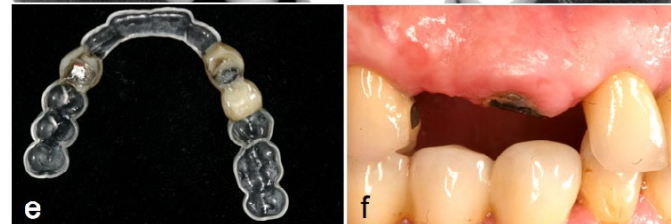
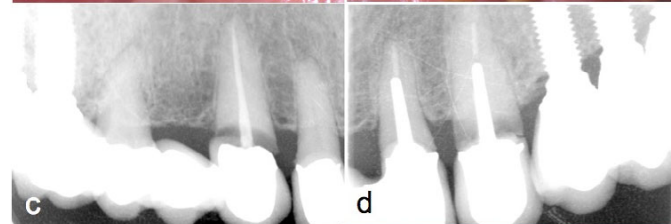

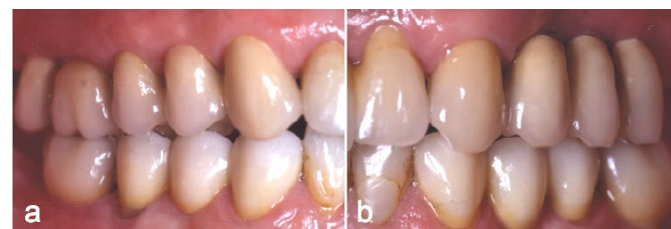
Fig.4 Clinical example of hopeless teeth; #6 #11 (a-d) that were extruded using magnets for pre-implant site enhancement (e-h).

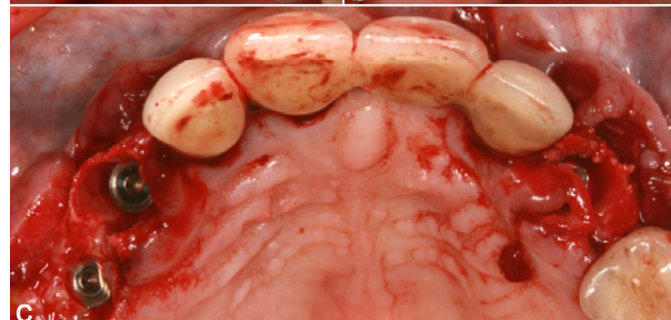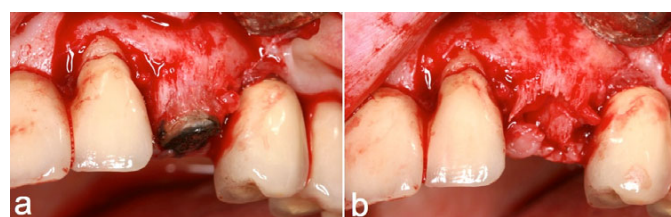


Fig.5 Images show bone level gain prior to implant placement (a & b). Extraction of teeth #6, 11 was followed by immediate implant placement 3 mm apical to the neighboring CEJ (c).

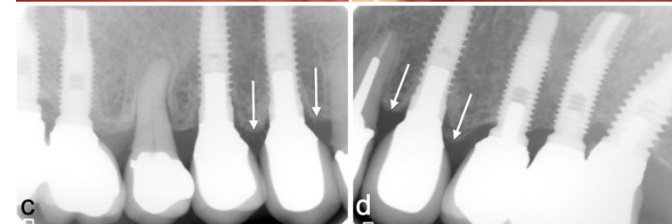
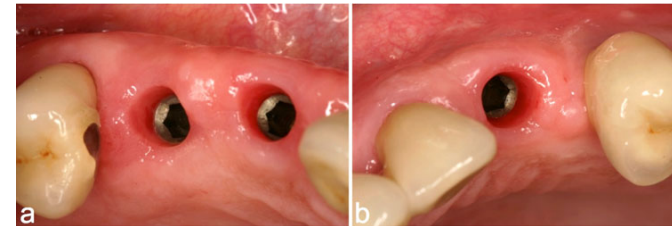


Fig.6 Clinical images showing a healthy soft tissue profile around the implants (a & b). Post-delivery radiograph showing the amount of bone level maintained around the implants (c & d).

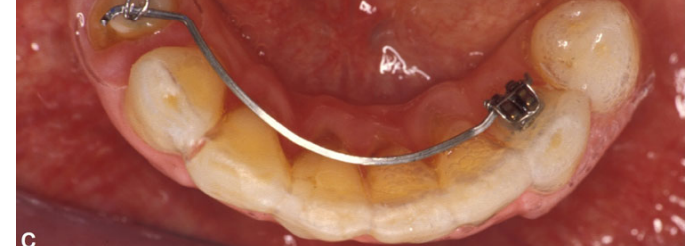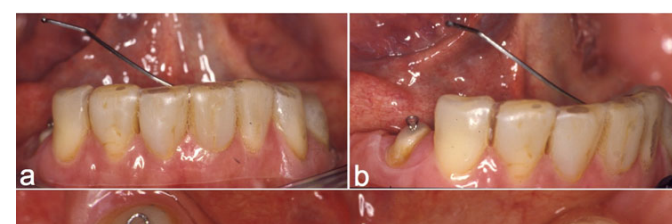


Fig.7 Example of hock and ring method for extrusion of a hopeless tooth. The flexible arm is attached to an acrylic stent with a conventional bracket (a). The ring or hock projection is cemented in the tooth to be extruded (b). The patient is instructed to connect the flexible arm with the ring (c).

Results

The outcome of this review was based on a few similarities found in the articles such as reason of tooth / teeth extraction as well as the force for extrusion with differing levels of evidence about the active extrusion and retention periods¹⁻⁴. Generally, the current data is limited to case reports and case series and therefore, no clear guidelines about orthodontic extrusion could be obtained. However, the available reports showed that orthodontic extrusion could be a reliable option to improve soft and hard tissue conditions prior to implant placement.

Discussion

The establishment of successful esthetic outcomes in implant treatment depends on thorough understanding of the relationship between hard and soft-tissue profiles, treatment planning and an accurate implementation of treatment procedures. In addition, little information was identified in the literature about a sequential step-by-step procedure on orthodontic extrusion for pre-implant site enhancement. An introduction of a workflow about the application of orthodontic extrusion as a technique for pre-implant site enhancement would be beneficial for clinicians to ease decision making (Fig.8).

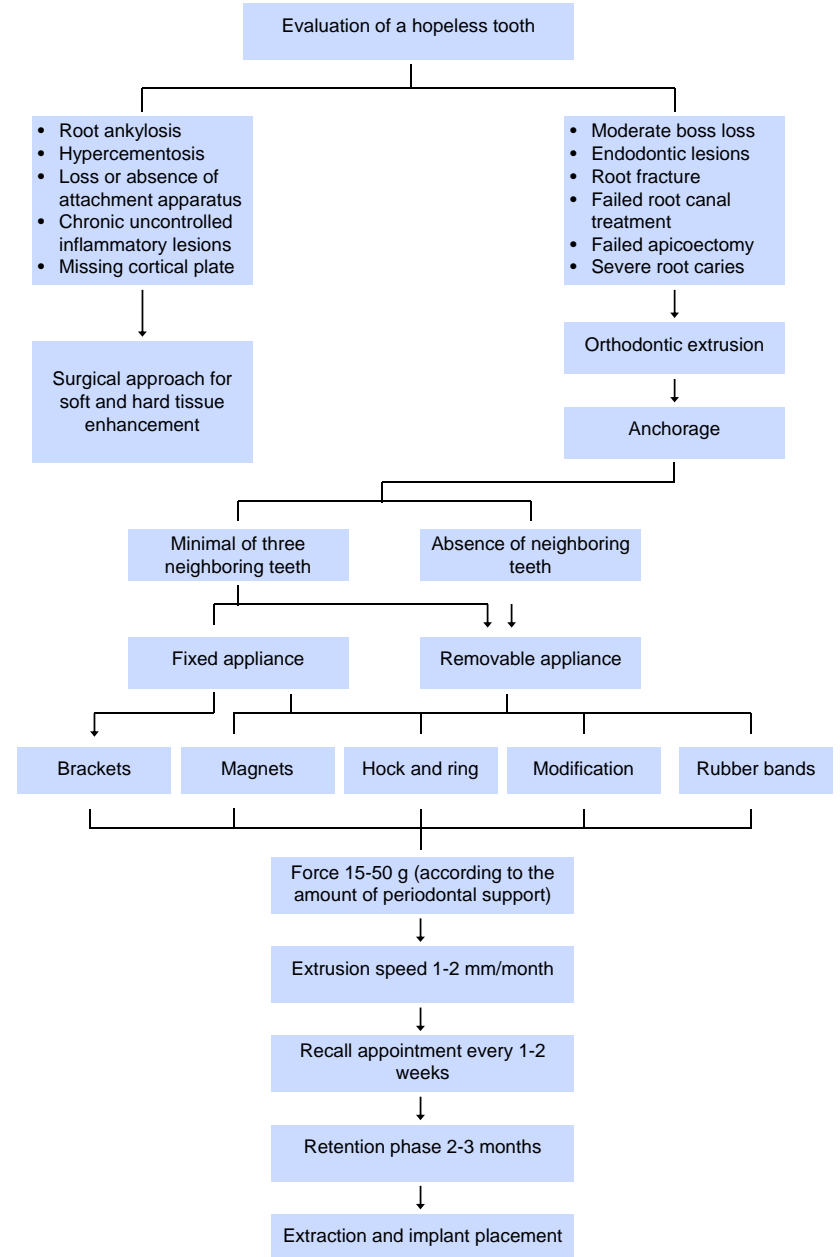


Fig.8 Summary of workflow for implant-site enhancement by means of orthodontic extrusion.

Conclusion

Orthodontic extrusion is being implemented as a treatment alternative to enhance hard and soft tissue prior to implant placement. While the current literature does not provide clear guidelines. The decision making for a specific approach seems to be based on the clinician's preferences. Clinical studies are needed to verify the validity of this treatment option.

References

- (1). Keceli HG, Guncu MB, Atalay Z, Evginer MS. Forced eruption and implant site development in the aesthetic zone: A case report. *Eur J Dent* 2014;8:269-275.
- (2). Borzabadi-Farahani A, Zadeh HH. Adjunctive orthodontic applications in dental implantology. *J Oral Implantol* 2013.
- (3). Amato F, Mirabella AD, Macca U, Tarnow DP. Implant site development by orthodontic forced extraction: a preliminary study. *Int J Oral Maxillofac Implants* 2012;27:411-420.
- (4). Mankoo T, Frost L. Rehabilitation of esthetics in advanced periodontal cases using orthodontics for vertical hard and soft tissue regeneration prior to implants - a report of 2 challenging cases treated with an interdisciplinary approach. *Eur J Esthet Dent* 2011;6:376-404.