

Int Poster J Dent Oral Med 2001, Vol 3 No 2, Poster 77

Fiber-Reinforced Inlay FPDs: Maximum Preservation of Dental Hard Tissue

Language: English

Author(s): Dr.med.dent. Till Nicolaus Göhring, Dr.med.dent. Ove Andreas Peters, David Sägesser, Prof. Dr. med. et Dr. med. dent. Felix Lutz
University of Zurich, Dental School

Date/Event/Venue:

May, 11th-13th 2000
Conseuro
Bologna, Italy

Introduction

A target of research in restorative dentistry is a defect-orientated solution to esthetically reconstruct missing teeth and to avoid tooth substance loss as in full-crown abutment preparations.

Material and Methods

In-vitro and clinically, inlay and slot-inlay FPDs made of Ceromer Targis reinforced by Vectris glass-fibers (Ivoclar, Schaan, FL), were evaluated.

A. In-vitro Study

Butt joint slot-inlay tooth preparations with cavity margins located in enamel were prepared in 18 maxillary human canines and 18 maxillary human first molars designated as abutments. Three experimental groups were formed. After mounting in a holding device (Fig. 1E), dentinal tubular fluid pressure was simulated. In group 1&2, after preparation dentin was sealed using Syntac Classic (Vivadent, Schaan, FL). After sealing procedure, preparation margins were finished and canines in group 2 were prepared with an additional 1.5 mm wide palatal bevel (Fig. 1A-D). Two premolars were replaced by lab-made prosthesis. Dentures were inserted using an ultrasonic-supported high-viscosity technique with "selective bonding" in group 1&2 (Ultraetch, Ultradent, South Jordan, UT/USA; Heliobond & Tetric Ceram, Vivadent) and "total bonding" in group 3 (Ultraetch, Syntac Classic Heliobond & Tetric Ceram). The restorations were stressed in a computer controlled masticator (Fig. 1F). Marginal quality was examined by scanning electron microscope (SEM) and marginal adaptation was measured quantitatively at a magnification of 200x (Amray 1810, Amray Inc., USA).

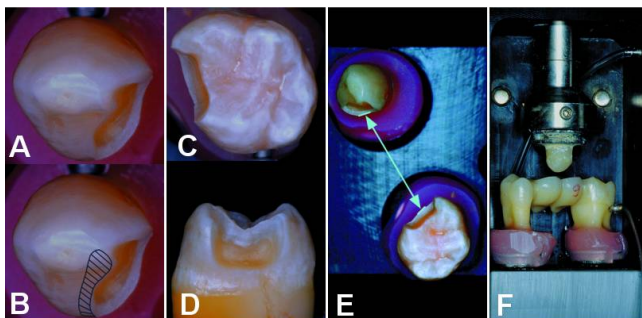


Fig. 1A-F: In-vitro experimental setup

In group 1&3 canines butt joint abutment cavities were prepared (A). In group 2, canines were bevelled 1.5 mm palatally (B). Butt joint slot-preparations were used for the molars in all groups (C&D). There was a 17 mm distance between the abutments, ensured by a holding device (E). Computer controlled masticator with a human cusp loading a four-unit inlay FPD with 1.2 Mio load cycles (49N) at 17 Hz and 3000 thermal cycles of type 5-55-5°C simultaneously (F).

B. Clinical Study

Since March 1997 56 defect-orientated inlay FPDs were inserted in 42 patients (Fig. 2A-J). 40 FPDs were examined clinically after one, 25 after two years using modified USPHS-criteria. 12 FPDs with 25 abutment inlays and 12 pontics were analysed by SEM (Fig. 3).

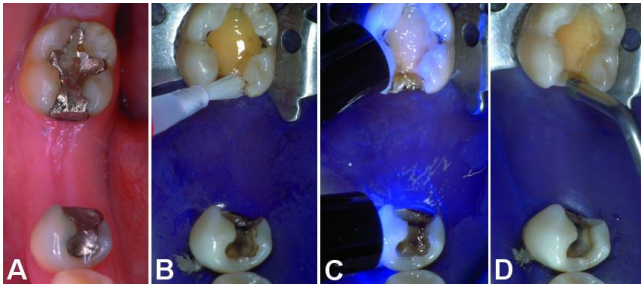


Fig. 2A-D:
After gross-preparation and caries removal dentin was sealed with Syntac Classic (B) and Heliobond (Vivadent, Schaan, FL) which was light-cured for 60s (C). Cavity margins were finished (D) with ultrasonic tips (EMS Mini-Piezon, EMS, Nyon, CH).

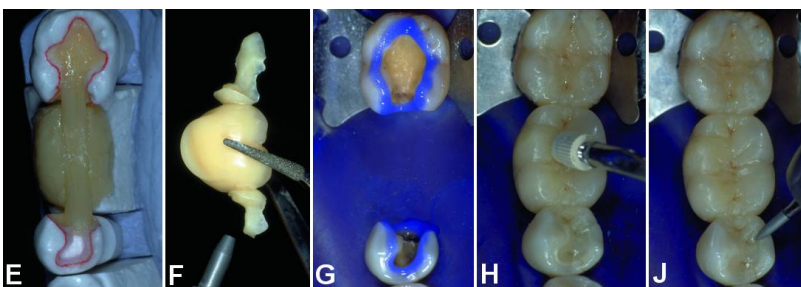
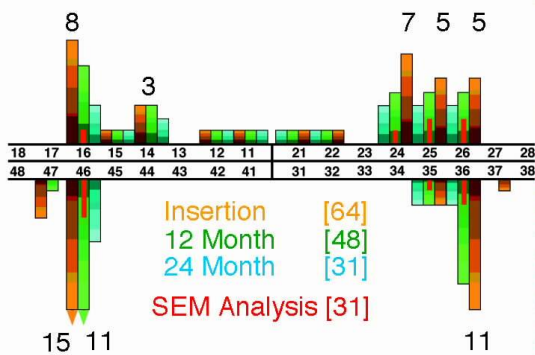


Fig. 2E-J:
With a simplified laboratory technique dentures were build up with Targis reinforced by Vectris glass-fibers (E). Before insertion, retainer-subsurfaces were sandblasted & silanated (F). Dentures were luted selectively to preparation margins, conditioned with 37% H3PO4 when located in enamel (G). A high viscous restorative composite material (Tetric, Vivadent) was used in combination with ultrasonic power (EMS SP-Tip) (H). After light-curing with *1000 mW/cm2, excess was eliminated with 8 µm diamond burs (J).

Pontics Number & Location



Abutments Total Mesial Distal

Slot	21	17	4
2 Surface Inlay	37	19	18
2 Surface Inlay (E)*	3	3	
3 Surface Inlay	32	15	17
3 Surface Inlay (E)*	5	2	3
> 3 Surface Inlay	11	3	8
> 3 Surface Inlay (E)*	2		2
Full Crown	1	1	
Full Crown (E)	1		1
Endo Crown*	4	1	3

* Root canal treated without post&core

Fig. 3:
With 28 maxillary and 28 mandibulary FPDs, mostly first molars were replaced. Most of the 117 abutments were slots, two- or three-surface inlays. In our department no post&core was used, so endodontically treated teeth were restored in the same way as vital teeth.

Results

A. In-vitro Study

Before thermomechanical loading, no significant differences in marginal adaptation were found. Canines showed 97.1 to 99.0% perfect marginal adaptation and molars 95.4 to 99.0%. The results for the tooth-composite interface after thermo-mechanical stress are illustrated in Fig. 4.

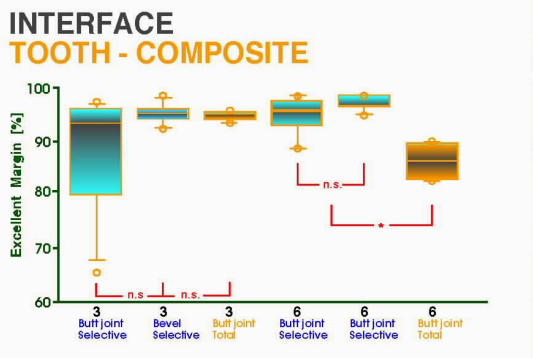


Fig. 4: ANOVA revealed no statistically significant differences between group 1 and 2. A significant decrease in marginal quality was detected when total bonding was used in box-shaped preparations ($p^*0.0001$).

B. Clinical Study

Results of clinical examination using modified USPHS-criteria are displayed in Fig. 5.

USPHS-Criteria	Baseline				14.6 ± 3.2 Months				24.9 ± 2.9 Months			
	α	β	γ	δ	α	β	γ	δ	α	β	γ	δ
TWO YEAR RECALL												
FPDs [n = 40/25]												
Fracture (Framework)	40				40				25			
Pontics [n = 48/31]												
Fracture (Delamination)	48				41	3	2	2	29	1	1	
Color Match	45	2	1		45	2	1		29	1	1	
Surface Texture	46	1	1		41	2	3	2	27	2	2	
Wear	48				46	2			29	2		
Abutments [n = 83/53]												
Fracture	83				83				53			
Color Match	79	3	1		78	4	1		51	1	1	
Surface Texture	78	4	1		77	5	1		47	5	1	
Wear	83				81	2			52	1		
Marginal Integrity	82	1			78	4	1		44	8	1	
Marginal Discoloration	83				82	1			49	4	1	
Postoperative Sensitivity	77	6			83				53			
CO Positive	72				72				43			
Recurrent Caries	83				83				53			

Fig. 5: Most clinical criteria were rated "alpha". After one year 3 infracture-lines, 2 partial and 2 total delaminations of pontic veneering material were detected. One retainer-debonding was detected at one-, and another at two-year recall.

By SEM, marginal adaptation was evaluated quantitatively at 200x (Fig. 6&7). Abutmentinlays and pontics were also scanned for signs of wear (Fig. 6).

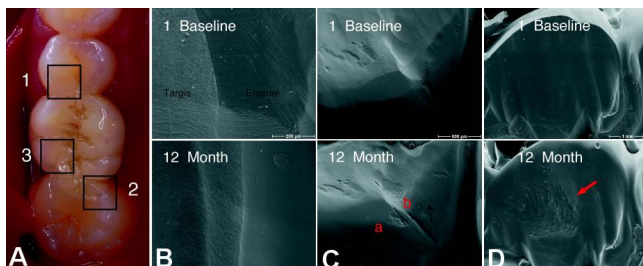
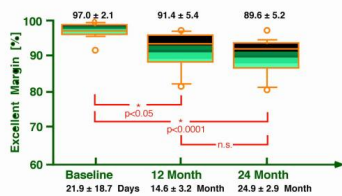


Fig. 6A-D: Slot-inlay-anchored FPD with areas of interest marked (A). Excellent marginal adaptation at baseline and at 12-month recall (B). Enamel-fracture (a) at tooth-composite- and marginal gap (b) at composite-inlay-interface(C). Pontic with undue wear in occlusal contact area (D).

INTERFACE TOOTH - COMPOSITE



INTERFACE COMPOSITE - INLAY

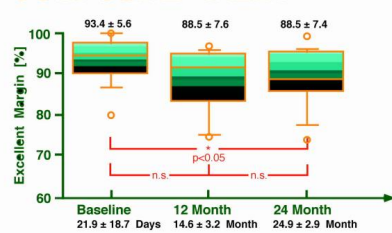


Fig. 7A+B:

Quantitative analysis of marginal adaptation. Although ANOVA revealed a significant loss of excellent margin between baseline and 12-month recall at tooth-composite interfaces, marginal quality was still very high and remained high till 24-Month recall (A). Marginal adaptation was stable at composite-inlay interfaces (B).

Discussion and Conclusions

Selectively bonded glass-fiber reinforced inlay FPDs in combination with a high viscous insertion technique were successful after two years.

Physical properties, especially wear resistance, need to be improved.

More research is necessary to optimize framework design and its copolymerization to veneering material.

Bibliography

- Göhring T, Krejci I, Lutz F: Adhäsive Inlaybrücken aus glasfaserverstärktem Komposit. Schweiz Monatsschr Zahnmed 1999; 109: 369-379.
- Göhring T, Mörmann W, Lutz F: Clinical and scanning electron microscopic evaluation of fiber-reinforced inlay FPDs: Preliminary results after one year. J Prosthet Dent 1999; 82: 662-668.
- Göhring TN, Peters OA, Lutz F: Adhäsive Inlaybrücken aus glasfaserverstärktem Komposit - Resultate der Untersuchung nach 12 Monaten. Deutsch Zahnärztl Z 1999; 54: 721-725.
- Lutz F, Göhring TN: Fiber-reinforced inlay fixed partial dentures: Maximum preservation of dental hard tissue. J Esthet Dent 2000; 12:164-171.
- Göhring TN, Peters OA, Lutz F: Marginal adaptation of bonded slot-inlays anchoring four-unit fixed partial dentures. J Prosthet Dent 2001; in press.
- Göhring TN, Schmidlin PR, Lutz F.: Glass-fiber-reinforced inlay fixed partial dentures after two years of clinical function: Clinical and scanning electron microscopic results. Am J Dent 2001; in press.

This Poster was submitted on 05/10/2001 by Dr. med. dent. Till Nicolaus Göhring.

Correspondence address:

Dr. med. dent. Till Nicolaus Göhring

University of Zurich

Departement of Preventive Dentistry, Periodontology and Cariology

Plattenstrasse 11

8028 Zurich

Switzerland



Fiber-Reinforced Inlay FPDs: Maximum Preservation of Dental Hard Tissue



T.N. Göhring*, O.A. Peters, D. Sägesser, F. Lutz

Department of Preventive Dentistry, Periodontology and Cariology, University of Zurich, Switzerland

Objectives

A target of research in restorative dentistry is a defect-orientated solution to esthetically reconstruct missing teeth and to avoid tooth substance loss as in full-crown abutment preparations.

Material and Methods

In-vitro and clinically, inlay and slot-inlay FPDs made of Ceromer Targis reinforced by Vectris glass-fibers (voclar, Schaan, FL), were evaluated.

A. In-vitro Study

Butt joint slot-inlay tooth preparations with cavity margins located in enamel were prepared in 10 maxillary human canines and 18 maxillary human first molars designated as abutments. Three experimental groups were formed. After mounting in a holding device (no. 18), distal tubular fluid pressure was simulated. In group 1&2, after preparation dentin was sealed using Syntac Classic (Vivadent, Schaan, FL). After seating procedure, preparation margins were finished and canines in group 2 were prepared with an additional 1.5 mm wide

were inserted in 42 patients (no. 24-3). 40 FPDs were examined clinically after one, 25 after two years using modified USPHS-criteria. 12 FPDs with 25 abutment inlays and 12 pontics were analysed by SEM (no. 4).

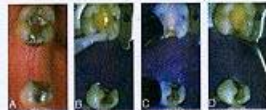


Fig. 2A-D: After gross preparation and cavity removal, dentin was sealed with Syntac Classic (B) and Heliobond (Vivadent, Schaan, FL) which was light-cured for 30s (C). Cavity margins were finished (D) with ultrasonic (EMS Mini Picojet, EMS, Nyon, CH).

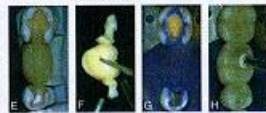

Fig. 2E-I: With a simplified laboratory technique dentures were built up with Targis reinforced by Vectris glass-fibers (E). Before insertion, retainer sub-surfaces were sandblasted & silanated (F). Dentures were luted selectively to preparation margins, conditioned with 27% H₂O₂, which located in enamel (G). A high viscous resin composite material (Cerac, Vivadent) was used in combination with ultrasonic power (EMS SP-70) (H). After light-curing with 2000 mW/cm², excess was eliminated with 8 µm diamond burs (I).

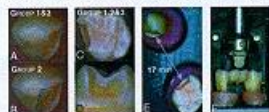


Fig. 2A-F: In-vitro experimental setup. In group 1&3 canines but joint abutment cavities were prepared (A). In group 2, canines were bevelled 1.5 mm proximally (B). Butt joint slot-preparations were used for the molars in all groups (C&D). There was a 17 mm distance between the abutments, ensured by a holding device (E). Computer controlled mesialator with a human cuspal loading a four-unit inlay FPD with 1.2 Mio load cycles (400 at 17 Hz and 3000 flexural cycles of type 5-55-5°C simultaneously) (F).

palatal bevel (no. 14-6). Two premolars were replaced by lab-made prosthesis. Dentures were inserted using an ultrasonic-supported high-viscosity technique with "selective bonding" in group 1&2 (Ultraetch, Ultradent, South Jordan, UT/USA; Heliobond & Tetric Ceram, Vivadent) and "total bonding" in group 3 (Ultraetch, Syntac Classic Heliobond & Tetric Ceram). The restorations were stressed in a computer controlled mesialator (no. 17). Marginal quality was examined by scanning electron microscope (SEM) and marginal adaptation was measured quantitatively at a magnification of 200x (Amray 1810, Amray Inc., USA).

B. Clinical Study

Since March 1997 56 defect-orientated inlay FPDs




Fig. 4: ANOVA revealed no statistically significant differences between group 1 and 2. A significant decrease in marginal quality was detected when total bonding was used in both-stair preparations (p<0.0001).

B. Clinical Study

Results of clinical examination using modified USPHS-criteria are displayed in no. 5.

USPHS-Criteria	Baseline	12 Months	24 Months
1. Marginal Adaptation	2.1	1.8	1.5
2. Marginal Stain	0.5	0.4	0.3
3. Marginal Discoloration	0.2	0.1	0.1
4. Marginal Wear	0.1	0.1	0.1
5. Marginal Fracture	0.1	0.1	0.1
6. Marginal Chipping	0.1	0.1	0.1
7. Marginal Cracks	0.1	0.1	0.1
8. Marginal Roughness	0.1	0.1	0.1
9. Marginal Porosity	0.1	0.1	0.1
10. Marginal Discoloration	0.1	0.1	0.1
11. Marginal Stain	0.1	0.1	0.1
12. Marginal Discoloration	0.1	0.1	0.1
13. Marginal Fracture	0.1	0.1	0.1
14. Marginal Chipping	0.1	0.1	0.1
15. Marginal Cracks	0.1	0.1	0.1
16. Marginal Roughness	0.1	0.1	0.1
17. Marginal Porosity	0.1	0.1	0.1
18. Marginal Discoloration	0.1	0.1	0.1
19. Marginal Stain	0.1	0.1	0.1
20. Marginal Discoloration	0.1	0.1	0.1
21. Marginal Fracture	0.1	0.1	0.1
22. Marginal Chipping	0.1	0.1	0.1
23. Marginal Cracks	0.1	0.1	0.1
24. Marginal Roughness	0.1	0.1	0.1
25. Marginal Porosity	0.1	0.1	0.1

Fig. 5: Most clinical criteria were rated "optimal". After one year 3 inlay-retainers, 2 partial and 2 total delaminations of pontic veneering material were detected. One restorer debonding was detected at one, and another at two-year recall.

By SEM, marginal adaptation was evaluated quantitatively at 200x (no. 8&9). Abutmentinlays and pontics were also scanned for signs of wear (no. 4).




Fig. 8A-D: Slot-inlay-anchored FPD with areas of interest marked (A). Excellent marginal adaptation at baseline and at 12-month recall (B). Densification (C) of both-core/veneering and marginal gap (D) at composite-inlay-interface (C). Pontic with undetectable wear in occlusal contact area (E).

Pontics	Number/Location	Abutments	Site	Max	Min	Mean
			Dist	21	17	4
			Dist	17	18	18
			2 Distal Inlay	3	3	3
			2 Distal Inlay (E)	32	15	17
			2 Inlay-retainer	3	3	3
			2 Inlay-retainer (E)	3	3	3
			Full-Crown	1	1	1
			Full-Crown (E)	1	1	1
			Preparation	1	1	1
			Preparation (E)	1	1	1
			Preparation	1	1	1
			Preparation (E)	1	1	1

Fig. 6: With 20 maxillary and 28 mandibular FPDs, exactly first molars were replaced. More of the 117 abutments were slots, two- or three-surface inlays. In our department no postcores was used, so endodontically treated teeth were restored in the same way as vital teeth.

Results

A. In-vitro Study

Before thermomechanical loading, no significant differences in marginal adaptation were found. Canines showed 97.1 to 99.0% perfect marginal adaptation and molars 95.4 to 99.0%. The results for the tooth-composite interface after thermo-mechanical stress are illustrated in no. 4.



Fig. 7: Quantitative analysis of marginal adaptation. Although ANOVA revealed a significant loss of excellent margin between baseline and 12-month recall at tooth-composite interfaces, marginal quality was still very high and remained high 18-24-Months recall (A). Marginal adaptation was stable at composite-inlay interfaces (B).

Conclusions

Selectively bonded glass-fiber reinforced inlay FPDs in combination with a high viscous insertion technique were successful after two years. Physical properties, especially wear resistance, need to be improved. More research is necessary to optimize framework design and its copolymerization to veneering material.