

Bone Remodeling and Bone Loss Around Subcrestal Implants: Two Distinct Entities

Peri-implant marginal bone stability is one of the main features used to evaluate the long-term success of implant therapy. Radiographic marginal bone loss (MBL) up to 2 mm during the first year of function, followed by a maximum of 0.2 mm of loss annually, was among the traditionally accepted criteria defining implant success.¹ Nowadays, improvements in implant design and clinical protocols allow for better preservation of peri-implant bone levels during the physiologic bone remodeling phase.

Exposing the microrough implant surface to the oral cavity favors bacterial biofilm adhesion and accumulation, influencing the subsequent biologic response of peri-implant soft and hard tissues. Numerous studies showed a direct correlation between physiologic bone remodeling and the risk of future peri-implant disease. In 2015, Galindo-Moreno et al identified peri-implant bone loss > 0.44 mm at 6 months postloading as a predictor of further bone loss progression over time.² In 2021, a long-term prospective study by Windael et al showed that marginal bone resorption ≥ 0.5 mm after 1 year of function increases the odds of peri-implantitis over a 10-year period by 5.43 times.³ Recently, radiographic MBL ≤ 0.5 mm after 6 months of prosthetic loading has been proposed as a success criterion for osseointegrated implants.⁴

For implants placed equicrestally or supracrestally, the method for measuring peri-implant MBL on peri-apical radiographs can be determined as the vertical distance between the implant-abutment junction (IAJ) and the most coronal bone-to-implant contact visible on radiographs.

In recent years, subcrestal implant positioning has been adopted as a clinical strategy to prevent unwanted colonization of oral microbial biofilm on the microrough implant surface⁵ and to avoid esthetic complications when a long prosthetic abutment is used.^{6,7}

For implants placed subcrestally, however, the aforementioned method for measuring MBL is conceptually inappropriate, as bone is also present coronal to the IAJ.

Characteristics and clinical relevance of bone coronal to the IAJ should be entirely distinguished from bone apical to the IAJ. Both of these regions of bone undergo dynamic changes in response to different stimuli, which have not been sufficiently investigated and are probably associated with different biologic behaviors.

Early bone resorption coronal to the IAJ is a process that involves both peri-implant soft tissue and bone changes. It is possible to assume that this remodeling phenomenon may involve supracrestal tissue height for-

mation and may even modify the vertical mucosal thickness around transmucosal implant components. Once this remodeling process has been completed, the portion of bone coronal to the IAJ supports the peri-implant mucosa, improving the tissue stability around the prosthetic abutment. Nevertheless, this kind of bone remodeling does not typically reduce the support of the microrough implant surface in normal conditions.

On the other hand, early bone resorption apical to the IAJ is a process that involves partial exposure of the implant surface. This can be considered as true MBL, as it affects the implant's osseous support and, more importantly, is a more insidious process because exposing the implant surface to the oral environment may be a risk factor for the onset and progression of peri-implant pathosis.²⁻⁴

Based upon these premises, for implants placed subcrestally, peri-implant bone resorption should be evaluated considering two different entities, as suggested elsewhere⁵: (1) bone remodeling, calculated as the distance between the bone crest and the IAJ; and (2) bone loss, calculated as the distance between the IAJ and the first radiographically visible bone-to-implant contact. These measurements are shown schematically and radiographically in Figs 1 and 2, respectively.

A critical appraisal of these two distinct factors could help clinicians select appropriate operative strategies and help researchers design studies focused on relevant clinical outcomes.

Sergio Spinato, DDS, PhD¹

Teresa Lombardi, DDS²

Claudio Stacchi, DDS, MSc³

¹Private Practice, Sassuolo, Modena, Italy.

²Department of Health Sciences, Magna Græcia University, Catanzaro, Italy.

³Department of Medical, Surgical, and Health Sciences, University of Trieste, Trieste, Italy.

References

- Albrektsson T, Zarb G, Worthington P, Eriksson AR. The long-term efficacy of currently used dental implants: A review and proposed criteria of success. *Int J Oral Maxillofac Implants* 1986;1:11–25.
- Galindo-Moreno P, León-Cano A, Ortega-Oller I, Monje A, O'Valle F, Catena A. Marginal bone loss as success criterion in implant dentistry: Beyond 2 mm. *Clin Oral Implants Res* 2015;26:e28–e34.
- Windael S, Collaert B, De Buyser S, De Bruyn H, Vervaeke S. Early peri-implant bone loss as a predictor for peri-implantitis: A 10-year prospective cohort study. *Clin Implant Dent Relat Res* 2021;23:298–308.
- Galindo-Moreno P, Catena A, Pérez-Sayáns M, Fernández-Barbero JE, O'Valle F, Padial-Molina M. Early marginal bone loss around dental implants to define success in implant dentistry: A retrospective study. *Clin Implant Dent Relat Res* 2022;24:630–642.
- Spinato S, Bernardello F, Lombardi T, et al. Influence of apico-coronal positioning of tissue-level implants on marginal bone stability during supracrestal tissue height establishment: A multi-center prospective study. *Clin Implant Dent Relat Res* 2022;24:611–620.
- Spinato S, Stacchi C, Lombardi T, Bernardello F, Messina M, Zaffe D. Biological width establishment around dental implants is influenced by abutment height irrespective of vertical mucosal thickness: A cluster randomized controlled trial. *Clin Oral Implants Res* 2019;30:649–659.
- Muñoz M, Busoms E, Vilarrasa J, Albertini M, Ruiz-Magaz V, Nart J. Bone-level changes around implants with 1- or 3-mm-high abutments and their relation to crestal mucosal thickness: A 1-year randomized clinical trial. *J Clin Periodontol* 2021;48:1302–1311.
- Linkevicius T, Puisys A, Linkevicius R, Alkimavicius J, Gineviciute E, Linkeviciene L. The influence of submerged healing abutment or subcrestal implant placement on soft tissue thickness and crestal bone stability. A 2-year randomized clinical trial. *Clin Implant Dent Relat Res* 2020;22:497–506.

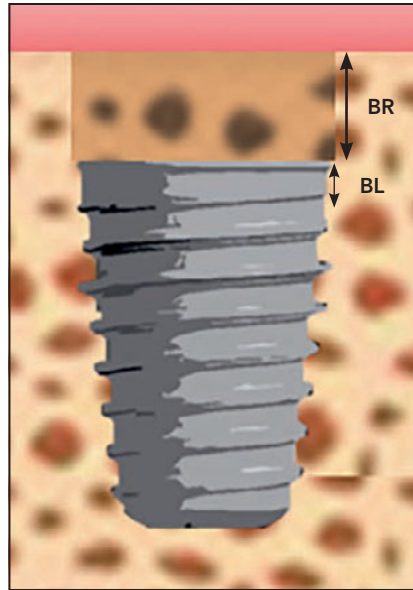


Fig 1 Bone resorption around subcrestal implants first involves bone coronal to the implant-abutment junction (bone remodeling; BR). It may continue below the implant-abutment junction, exposing the treated implant surface (bone loss; BL).

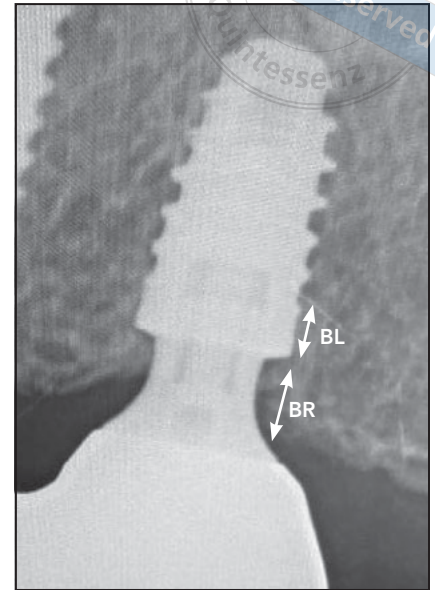


Fig 2 A radiographic view highlights the bone remodeling area (BR; coronal to the implant-abutment junction) and bone loss area (BL; apical to the implant-abutment junction).

In Memoriam: Lori Bateman



Quintessence Publishing has lost a dear friend and valued colleague in the passing of Lori Bateman. Lori was part of the Quintessence family for over 30 years and retired in 2022 as the director of journal publications. While her retirement was cut short due to her lung cancer diagnosis, she still got to enjoy some time in her garden, in yoga class, and with her daughter, Anna.

During her time at Quintessence, Lori developed invaluable relationships with our authors and editors-in-chief as well as with industry partners, and she leaves a legacy in the journals she helped to build: *The International Journal of Oral and Maxillofacial Implants*, *the Journal of Oral & Facial Pain and Headache* (formerly *Journal of Orofacial Pain*), *The International Journal of Periodontics & Restorative Dentistry*, and *The International Journal of Prosthodontics*. She also had an indelible impact on countless staff, including the many editors she developed to work alongside her as well as others who have come and gone over the years. She planted the seeds for a department built on thoughtfulness, care, and of course editorial precision, and those seeds have taken root and continue to sprout in her absence.

For the staff at Quintessence, Lori was a colleague and a friend, but for me personally, Lori was a heart and a compass. In business, there are always the hard decisions that need to be made, but Lori helped me to temper them with empathy and understanding for our editors-in-chief, our contributors, and our authors. Lori cared so much for the people she worked with.

Lori will always be part of our Quintessence family, even if she is no longer with us. She will be remembered as a sharp mind, a kind soul, and a trusted friend. Rest in peace, Lori.

William Hartman
Executive Vice President & Director
Quintessence Publishing