

# 3D model analysis of the orthopaedic effect of the drink plate in patients with unilateral cleft lip and palate

Eisele, S.<sup>1</sup>, Botzenhart, U.U.<sup>1</sup>

<sup>1</sup>Department of Orthodontics, Medical Faculty Carl Gustav Carus, TU Dresden, Fetscherstrasse 74, 01307 Dresden, Germany



## Introduction

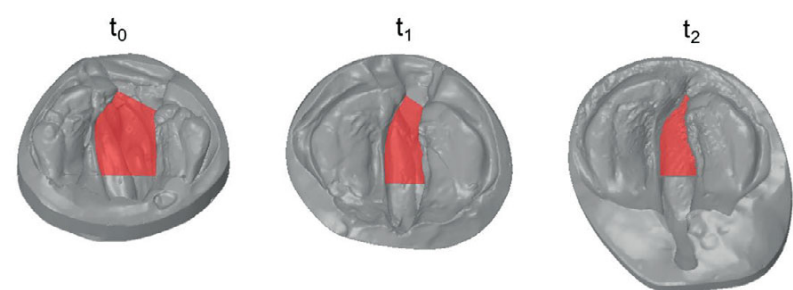
Cleft lip and palate (CLP) are one of the most common congenital malformations of the orofacial system with a prevalence of approximately 1:500 live births<sup>1</sup>. Early pre-surgical orthopaedics (PSO) of these infants using a drink plate has been established in the interdisciplinary therapy concept at many cleft centers worldwide<sup>2</sup>, which is intended to reduce scar tissue formation inevitably arising due to the surgical cleft closure by early reduction of the cleft width<sup>3</sup>. Currently, however, there is no uniform consensus in the scientific community regarding this early intervention<sup>4,5,6</sup>.

**The aim of this retrospective study** was a three-dimensional evaluation of the orthopedic effect of the drink plate from birth to surgical palatal closure, taking into account individual maxillary growth in patients with unilateral non-syndromic cleft lip and palate (UCLP).

## Material und Methods

Out of the patient population of infants with unilateral non-syndromic unilateral cleft lip and palate treated in the Department of Orthodontics, Medical Faculty Carl Gustav Carus, TU Dresden, in the period in of 1991-2016, model casts taken immediately after birth (t<sub>0</sub>), before surgical lip closure (t<sub>1</sub>) and/or closure of the soft palate (t<sub>2</sub>) were evaluated, of which n=27 patients (n=70 model casts) fulfilled the inclusion criteria (**Table 1**), which were then digitised using a 3D scanner (OrthoScan, Dentauro, Ispringen, Germany) and measured three-dimensionally (CleftDynamic, S.K.M. Informatik GmbH, Schwerin, Germany). In addition to the morphological changes of the maxilla and cleft dimension during drink plate therapy, a possible correlation of these to the cleft expression at birth was also analysed (**Figure 1**). For this purpose, an individual growth area was also determined for each patient/ model cast in order to be able to make corresponding statements. Statistical analysis was performed using Microsoft Excel 2018 (Microsoft Corporation, Redmond, USA), paired and unpaired t-test, Pearson and Spearman correlation coefficient analysis, respectively, and regression analysis (p = 0.05).

time of assessment		t <sub>0</sub>	t <sub>1</sub>	t <sub>2</sub>
frequency		27	27	16
gender	♂	16	16	10
	♀	11	11	6
location of the cleft	left	17	17	9
	right	10	10	7



tab. 1: Overview of the composition of the investigated cleft collective (t<sub>0</sub>; t<sub>1</sub>; t<sub>2</sub> = immediately after birth, before lip closure, before closure of the soft palate). A total of n=27 patients and n=70 cleft models were measured, respectively.

fig. 1: Exemplary 3D model series (upper jaw, top view) of a patient with left-sided non-syndromic UCLP at the time immediately after birth (t<sub>0</sub>), under drink plate therapy: before lip closure (t<sub>1</sub>) and before closure of the soft palate (t<sub>2</sub>). In each case the cleft area is shown in red.

## Results

During the observation period t<sub>0</sub>-t<sub>2</sub>, the cleft expression at birth decreased significantly by a total of 56%, and taking into account the individual maxillary growth, a significant decrease of 31% and 25% for the time interval: t<sub>0</sub>-t<sub>1</sub> and t<sub>1</sub>-t<sub>2</sub>, respectively, as well as a significant linear correlation between the cleft expression at birth and the decrease of the cleft area during PSO was observed for both investigation periods (**Figure 2,3**).

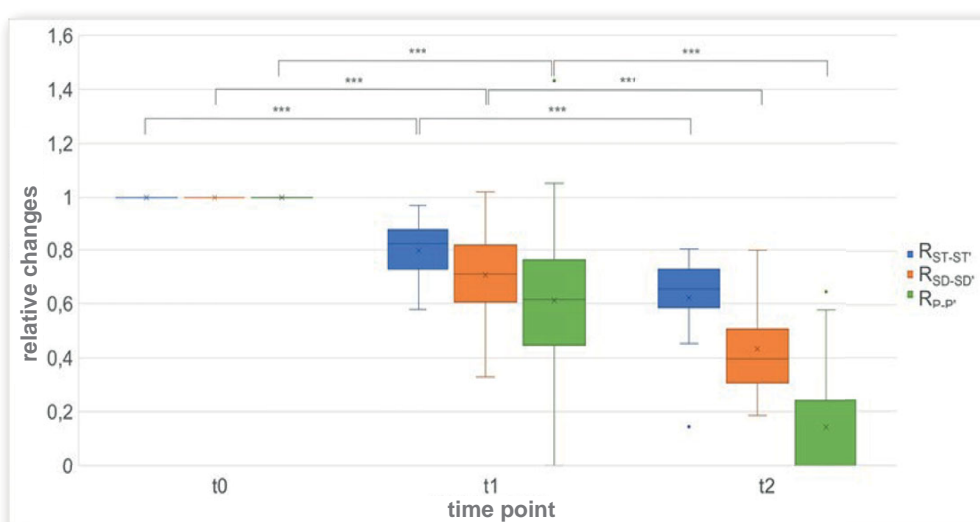


fig. 2: Boxplot diagram of the cleft widths. Plot of the relative changes in the posterior cleft width R<sub>(ST-ST)</sub>, the central cleft width R<sub>(SD-SD)</sub>, and the anterior cleft width R<sub>(P-P)</sub> at time t<sub>0</sub> (birth), t<sub>1</sub> (before lip closure), and t<sub>2</sub> (before closure of the soft palate); \*p ≤ 0.05, \*\*p ≤ 0.01, \*\*\*p ≤ 0.001.

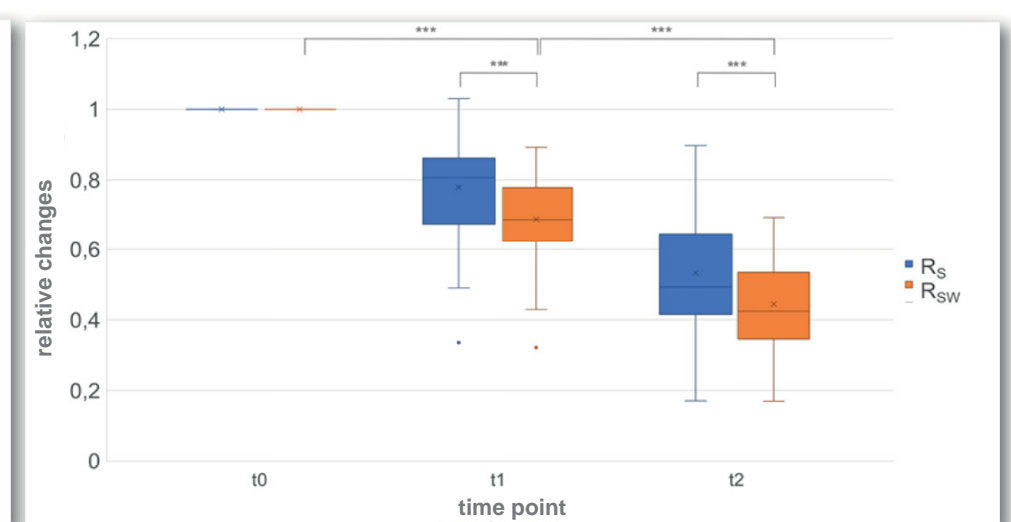


fig. 3: Boxplot diagram of cleft surface (RS) and cleft surface considering growth (RSW). Comparison of the relative changes in the cleft area (RS) and cleft area considering growth (RSW) at time t<sub>0</sub> (birth), t<sub>1</sub> (before lip closure), and t<sub>2</sub> (before closure of the soft palate); \*p ≤ 0.05, \*\*p ≤ 0.01, \*\*\*p ≤ 0.001.

## Conclusion

Even if surgical lip closure increased the convergence of the cleft segments (t<sub>1</sub>-t<sub>2</sub>), considering individual maxillary growth, a significant decrease of the cleft area could be found during drink plate therapy until lip closure (t<sub>0</sub>-t<sub>1</sub>), suggesting an orthopaedic effect of this treatment with convergence of the cleft segments.

## Literature

- <sup>1</sup>Epidemiology of oral clefts 2012: an international perspective (Review). Mossey PA, Modell B. *Front Oral Biol.* 2012;16:1-18.
- <sup>2</sup>Comparison of two treatment protocols in children with unilateral complete cleft lip and palate: Tridimensional evaluation of the maxillary dental arch. Jorge PK, Gnoinski W, Vaz Laskos K, Felício Carvalho Carrara C, Gamba Garib D, Okada Ozawa T, Andrade Moreira Machado MA, Pinelli Valarelli F, Oliveira TM. *J Craniomaxillofac Surg.* 2016 Sep;44(9):1117-22.
- <sup>3</sup>Transverse maxillary arch changes with the use of preoperative orthopaedics in unilateral cleft palate infants. Ball JV, DiBiase DD, Sommerlad BC. *Cleft Palate Craniofac J.* 1995 Nov;32(6):483-8.
- <sup>4</sup>Effectiveness of pre-surgical infant orthopedic treatment for cleft lip and palate patients: a systematic review and meta-analysis. Papadopoulos MA, Koumridou EN, Vakalis ML, Papageorgiou SN. *Orthod Craniofac Res.* 2012 Nov;15(4):207-36.
- <sup>5</sup>Cleft Lip – A Comprehensive Review. Shkoukani MA, Chen M, Vong A. *Front Pediatr.* 2013 Dec 27;1:53.
- <sup>6</sup>Treatment outcomes of pre-surgical infant orthopaedics in patients with non-syndromic cleft lip and/or palate: A systematic review and meta-analysis of randomized controlled trials. Hosseini HR, Kaklamanos EG, Athanasiou AE. *PLoS One.* 2017 Jul 24;12(7):e0181768.