

Gabriel Krastl, Kerstin Galler, Till Dammaschke, Edgar Schäfer

# Is pulpotomy a valid treatment option for irreversible pulpitis?

## Scientific Communication of the German Society of Endodontology and Dental Traumatology

**Summary:** Based on the current state of knowledge, vital pulp treatment on teeth with deep carious lesions is indicated only in vital teeth which are asymptomatic, or at the most, show symptoms of reversible pulpitis. In cases of irreversible pulpitis, vital pulp extirpation and root canal treatment constitutes a reliable and established method that should still be considered the gold standard. However, recently published clinical studies show that, despite the diagnosis of “irreversible pulpitis”, surprisingly high success rates can be achieved after partial or full pulpotomy. These findings do not only challenge the current treatment concepts for teeth affected by pulpitis, but also the current system for diagnosing different stages of the disease. Although the diagnosis of “irreversible pulpitis” is consistent with histologically detectable areas of bacterially infected or already necrotic tissue, these areas are localized beneath the carious lesion in the coronal pulp and do not affect the entire pulp tissue.

Pulpotomy involves the complete removal of inflamed, and therefore heavily bleeding, pulp tissue up to the level where the remaining pulp tissue is healthy in order to create the necessary conditions for healing. To date, a total of 12 clinical studies with a focus on vital pulp treatment in teeth with deep carious lesions and irreversible pulpitis have been published. Success rates after observation periods of 1 to 5 years range between 85 % and 95 % in most studies, regardless of patient age and type of pulpotomy (partial or full). However, it must be taken into account that long-term studies are lacking, and the significance of the individual studies is limited by various qualitative deficits. In spite of these shortcomings, based on the current data, pulpotomy can be regarded as a valid treatment option for irreversible pulpitis and it certainly represents an alternative to vital pulp extirpation. Whereas the correct indication is critical, the success of a pulpotomy procedure mainly relies on the adequate performance of the necessary treatment steps. This includes, in addition to the aseptic treatment concept in combination with the consistent use of rubber dam and sterile instruments, the use of magnifying aids to enable a sufficiently precise amputation procedure, the endodontic expertise to assess the exposed pulp tissue, the application of appropriate disinfection measures and capping of the tissue with a bioactive material followed by an immediate coronal seal.

**Keywords:** partial pulpotomy; pulpitis; vital pulp treatment; full pulpotomy

---

Department for Conservative Dentistry and Periodontology, University Hospital Würzburg: Prof. Dr. Gabriel Krastl  
Department for Conservative Dentistry and Periodontology, University Hospital Regensburg: Prof. Dr. Kerstin Galler  
Department of Periodontology and Operative Dentistry, University Hospital Münster: Prof. Dr. Till Dammaschke  
Central Interdisciplinary Outpatient Clinic, Münster University Hospital: Prof. Dr. Edgar Schäfer  
Translation from German: Cristian Miron

**Citation:** Krastl G, Galler K, Dammaschke T, Schäfer E: Is pulpotomy a valid treatment option for irreversible pulpitis? *Dtsch Zahnärztl Z Int* 2021; 3: 80–87

**Peer-reviewed article:** submitted: 30.08.2020, revised version accepted: 12.10.2020

**DOI.org/10.3238/dzz-int.2021.0010**

## Introduction

The high success rate of correctly performed root canal treatment has been proven in many studies. This is particularly true for teeth that require treatment, but do not exhibit signs of a preoperative apical periodontitis [45]. Even though the success rates 5 years after vital pulp extirpation and root canal treatment are around 90 % [22], the complete loss of pulpal tissue function is an imperative consequence [18]. This leads to several disadvantages, including an increased risk of fracture due to hard tissue removal during preparation as well as morphological and structural changes of dentin that occur during treatment, and possibly, to an increased maximum loading owing to the partial loss of proprioceptive protective mechanisms [23, 36]. Other potential drawbacks after root canal treatment include coronal discolorations [29], higher susceptibility to caries as a consequence of accelerated biofilm formation due to alterations of the microflora [41], the lack of defensive capacity of the pulp-dentin complex as well as the absence of a functional pain response system. Endodontic treatment often proves to be more complex than anticipated initially, which can significantly impair the treatment outcome. In case of failure, subsequent therapies to preserve the tooth (e.g. root canal retreatment or apicoectomy) are associated with significantly increased efforts.

The above-mentioned problems can be avoided if the vitality of the pulp is maintained. Procedures that aim for the preservation of pulp vitality are conservative measures which can be performed with considerably less time expenditure than root canal treatment [6]. If correctly indicated and implemented, vital pulp treatment is associated with high success rates [18] and is cost-effective in the long term [52, 63].

Moreover, in recent years, the dental literature shows a clear trend in favor of preserving tooth vitality which is scientifically pursued in different dental specialties [10, 18, 21, 51].

For an overview of vital pulp treatment subsequent to pulp exposure, the position paper "Current recommendations for vital pulp treatment" by

the German Society of Endodontology and Dental Traumatology (DGET) should be referred to [18].

The present article focuses exclusively on vital pulp treatment and in particular on partial removal of pulp tissue in teeth that require root canal treatment according to current standards, which are based on the belief that preservation of pulp vitality was not possible. Thus, partial pulpotomy (partial amputation of the coronal pulp) and full pulpotomy (complete amputation of the coronal, but preservation of the radicular pulp) are discussed here.

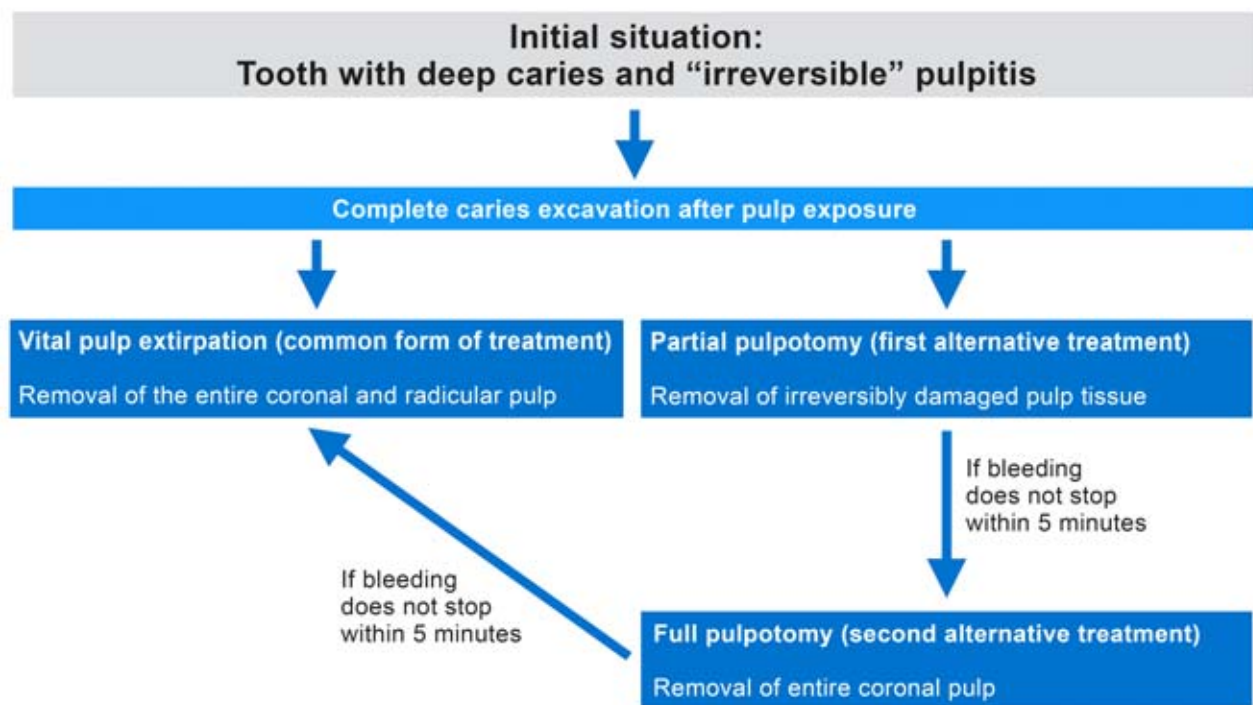
Vital pulp treatment after traumatic exposure (by direct pulp capping and partial pulpotomy following complicated crown fractures) are not considered in this publication, as preservation of pulp vitality in such cases is implicit and can be achieved predictably and successfully [24, 30]. Likewise, cases with deep carious lesions but without signs of irreversible pulpitis are excluded as these neither represent a primary indication for root canal treatment.

## 1. Biological background regarding pulpotomy in cases of carious exposure

In the majority of cases, inflammatory reactions in the pulpal tissue develop due to microbial irritation originating from carious lesions, but may also occur after mechanical, thermal or chemical irritation or due to traumatic damage. Depending on the intensity of the stimulus, the inflamed tissue may either heal or increase in intensity to take on acute or chronic forms. The inflammation spreads from the site of injury into the pulp tissue. During this process, both healthy and affected tissue with varying degrees of inflammation, can be present concomitantly. Furthermore, changes occur constantly as the inflammatory process progresses. Various classification systems have been developed over time in order to adequately describe the pulpal status; either based on clinical or histological observations. Histologically, a large variety of pulp tissue states can be described, whereas the currently available clinical diagnostic tools allow only a rough classification. Since the histopathol-

ogical condition of the pulp cannot be evaluated clinically, the therapeutic decision must be based on the clinical diagnosis. The AAE (American Association of Endodontists) has adhered to the current consensus to classify pulpitis clinically as reversible and irreversible [1, 2]. Whereas in teeth with reversible pulpitis, pain is most often induced upon stimulation only, irreversible pulpitis is typically associated with lingering pain induced by thermal stimuli, spontaneous (unprovoked) pain and possibly by the patient's inability to precisely localize which tooth is the culprit and source of the pain.

According to the current state of knowledge, vital pulp therapy in teeth with deep caries is indicated only if the pulp is vital pulp and the tooth is asymptomatic, or at the very most, shows symptoms of reversible pulpitis [21]. This applies to selective caries excavation, too [10]. Up to now, vital pulp treatment is considered to be contraindicated if there is already evidence of irreversible pulpitis, due to the belief that the tissue cannot heal predictably after the removal of the triggering stimulus. Surprisingly, several recent clinical studies have shown high success rates after partial and full pulpotomy in cases of irreversible pulpitis [3–6, 31, 33, 39, 47, 56–58, 60]. This challenges the suitability of the current classification system of pulpal diseases to adequately describe the condition of the pulp and accordingly, its clinical relevance [62]. Some studies suggest that the histological condition of the pulp correlates with the clinical diagnosis in many cases [15, 48], especially in healthy teeth and teeth with reversible pulpitis [48], which display a moderate chronic inflammatory reaction. Furthermore, in the majority of cases in which an "irreversible pulpitis" was diagnosed clinically, areas of necrotic and infected pulp were actually detected histologically. In the presence of bacteria in the pulp chamber, microabscesses and tissue necrosis can be found, which are engulfed by polymorphonuclear neutrophilic granulocytes, and inflammatory infiltrates are present at the periphery [48]. However, this histologic condition does not affect the entire pulp tissue, but remains restricted to the areas beneath the carious lesion, while the radicular pulp ap-



**Figure 1** Treatment options for irreversible pulpitis

pears unchanged apart from a partial loss of the odontoblast layer [48, 50]. Thus, the term irreversible pulpitis is misleading as the clinical diagnosis cannot be equated with the tissue's ability to heal after therapeutic intervention. Vital tissue may still be present in the root canal even in cases with radiographic signs of an initiating periapical lesion, which is regarded as a local immune reaction in the periapical tissue triggered by inflammatory mediators [55]. Therefore, it may not represent an absolute contraindication for vital pulp treatment [56].

Yet, irreversible pulpitis can be completely asymptomatic. According to histological findings, teeth which displayed an immune reaction as described above were clinically symptom-free in 14–60 % of cases [42, 53]. Another study showed that in 15.6 % of cases, the clinical and histological diagnoses did not correspond [48]. Moreover, a significant correlation between spontaneous pain prior to treatment, which suggests irreversible pulpitis, and the success of vital pulp treatment is not necessarily existent [40]. When diagnosing “irreversible pulpitis”, it must be considered that pain sensation is always subjective, does not correlate with the extent of

the inflammation, and cannot be detected histologically. The treatment of pulpitis should thus be based on the extent of the bacterial infection; unfortunately, in a clinical scenario, this cannot be determined precisely due to the insufficient correlation of clinical symptoms and histological findings.

There is, however, a good correlation between the depth of bacterial penetration into dentin and the histologically detectable pulpal response to the carious lesion [38]. Thus, the clinical classification of the symptoms in terms of reversible or irreversible pulpitis has nothing to say about the regenerative capacity of the tissue [11]. In contrast, the assessment of tissue bleeding after pulp exposure is a more reliable diagnostic procedure compared to the sensitivity test and pain symptoms. In cases of mild inflammation, less profuse bleeding occurs, especially in the case of reversible pulpitis. However, if bacteria have penetrated deeper into the pulp tissue, the more pronounced inflammatory reaction causes more severe bleeding from the tissue, particularly in the case of irreversible pulpitis. Pulpal bleeding thus reflects the degree of inflammation and the chance of healing; heavy or prolonged bleeding indicates

significant damage of the affected pulp tissue and reduced chances of healing [14, 28, 34, 40]. As a consequence, inflamed and heavily bleeding pulp tissue needs to be removed completely up to the level where healthy tissue remains in order to create the necessary conditions for successful pulp preservation. Similarly to an acute infection in the fingernail area, for example, in which a targeted excision of the infected tissue is performed rather than the amputation of the entire finger [35], the exclusive excision of the irreversibly damaged areas of the pulp would also be sufficient to allow healing in cases of pulpitis.

Pulpotomy has been considered an established emergency treatment measure for irreversible pulpitis for decades. Recently, two randomized controlled trials have shown that pain relief after pulpotomy is as reliable as after vital pulp extirpation [19, 20]. In this manner, the noticeably more time-consuming root canal treatment including chemo-mechanical preparation can be performed at a subsequent point. In these cases, the idea of using pulpotomy, not only as a temporary measure, but rather as a definitive endodontic treatment is not new and dates back to the last century [12].

However, this topic has been researched more extensively only in recent years, on the one hand due to advances in the field of pulp biology, on the other hand the availability of new bioactive materials [54].

Furthermore, in countries where root canal treatment is not accessible to the general public for cost-related reasons, pulpotomy has been considered to be a less costly alternative to avoid an otherwise necessary extraction [3, 63]. In fact, the treatment duration of a pulpotomy procedure amounts to about one-third of that of a root canal treatment [6].

## 2. Pulpotomy as a clinical procedure after carious exposure

The starting point for performing a pulpotomy is a tooth with a deep lesion with pulp exposure in carious dentin and/or symptoms of irreversible pulpitis (Fig. 1). After isolation with rubber dam and disinfection of the tooth crown, complete caries excavation has to be performed, beginning from the periphery towards the center, ideally using optical magnification devices. This is followed by an initial examination of the pulp tissue at the exposure site. Infected dentin chips, which were transported into the pulp tissue during excavation, can often be observed. Hyperemic and necrotic pulp areas may be found contiguously; a pale-yellow color indicates absent blood circulation and necrosis, occasionally, micro-abscesses are present [49]. The aim of a pulpotomy procedure is to remove damaged tissue and to lay open healthy pulp by means of amputation. For this purpose, a water-cooled, high-speed diamond bur is used.

From a technical standpoint, the full (= cervical) pulpotomy is the easiest to perform because the end-point of amputation is clearly defined by reaching the root canal orifices. Given that significantly more tissue is removed in a full compared to a partial pulpotomy, the probability of leaving behind only healthy tissue that is capable of healing is increased, meaning that the prospect of success is high. However, this procedure also comes with disadvantages. For instance, in the context of clinical fol-

low-up examinations, the sensitivity test is inconclusive and the success of treatment can only be assessed radiologically – with the corresponding limitations. Moreover, in contrast to partial pulpotomy, the risk of root canal obliteration after full pulpotomy is increased [18].

Within this framework, the extent of amputation should be based on the depth at which healthy pulp tissue can be identified and bleeding can be controlled. While inflammatory changes within the pulp tissue remain limited to the coronal 2 mm after trauma-related pulp exposure and subsequent contact with the oral milieu for up to 7 days [17, 26], the depth of tissue destruction that results from a carious process is significantly more variable. In this case, a reliable assessment of the tissue condition is only possible by use of using sufficient magnification and illumination.

Sodium hypochlorite (NaOCl) is recommended for rinsing and disinfection of the amputation site whereby the concentration of the endodontic irrigant (1–5.25 %) does not appear to be a prognostically decisive factor [43]. Careful compression using a cotton pellet soaked in NaOCl may facilitate further hemostasis. The use of a hemostatic agent is not recommended as it would “mask” the true inflammatory state of the pulp [64]. Also, the use of a laser is not recommended due to insufficient evidence. In a recent randomized controlled trial, the supplementary use of an Er,Cr:YSGG laser for pulpotomy after carious exposure of asymptomatic immature teeth was not beneficial [59].

After amputation and rinsing, bleeding should stop within 5 minutes. However, this time frame is only a reference value because, in some studies, significantly longer bleeding times (15 minutes and longer) have led to successful treatment [47]. Persistent bleeding indicates that the reduction of pulpal tissue was not sufficient to reach the level of healthy tissue [64]; in this case, a deeper pulpotomy or even a full pulpotomy can be considered. Although reports of successful deeper pulpotomies can be found in the literature, in which the amputation site was up to several millimeters below the root canal orifices, in the authors' view,

there is no discernible decisive advantage compared to vital pulp extirpation and subsequent root canal treatment, at least in mature teeth.

The exposed pulp surface should be capped with an aqueous suspension of calcium hydroxide or preferably a hydraulic calcium silicate cement, the cap can be coated with a thin layer of a fast-setting material [16]. There is clear evidence for the superiority of hydraulic calcium silicate cements compared to calcium hydroxide when used for vital pulp treatment after carious pulp exposure [13, 27, 32, 37, 58]. Within the group of hydraulic calcium silicate cements, distinct clinical differences do not seem to exist [37], however, the discoloration potential of the respective product has to be considered. The application of light-curing flowable materials with additives of MTA in direct contact with the pulp is not recommended due to their limited biocompatibility [7, 46]. After the pulp capping procedure, an adhesive seal and coronal restoration should be placed immediately, since this step is critical for the success of the treatment.

## 3. State of evidence: chance of success in cases of irreversible pulpitis and potential influencing factors

Compared to teeth with traumatic damage, it can be assumed that the pulp of teeth with carious exposure is significantly pre-damaged, as the pulp has already been in contact with bacterial toxins or even with the bacteria themselves for a considerable amount of time. The lesion size, bacterial spectrum, and the speed at which the lesion progresses affect the pulpal status [18]. Thus, it can be expected that the high success rates of over 90 % after partial pulpotomy in teeth with complicated crown fractures [24] are considerably higher than after carious pulp exposure. In spite of this, more than 10 current clinical studies have focused on vital pulp treatment measures in carious teeth with a diagnosis of “irreversible pulpitis”. High success rates ranging between 85 % and 95 % after observation periods of 1 to 5 years have been recorded in most studies, regardless of whether a

Study	Study type	Patient age	Number of treated teeth	Initial diagnosis of the pulp	Observation period	Treatment measure	Capping material	Success	Age influence
(Asgary & Eghbal 2013)	RCT	9–65 years ø 27 years	413	Irreversible pulpitis	1 year	Full pulpotomy	CEM MTA	92 % (CEM) 95 % (MTA)	N/S
(Asgary & Eghbal 2014)	RCT	9–65 years	407	Irreversible pulpitis	2 years	Full pulpotomy vital pulp extirpation	CEM	86 % (full pulpotomy) 80 % (vital pulp extirpation)	N/S
(Asgary et al. 2015)	RCT	9–65 years	407	Irreversible pulpitis	5 years	Full pulpotomy vital pulp extirpation	CEM	71 % (full pulpotomy) 66 % (vital pulp extirpation)	none
Kunert et al. 2015	Retrospect.	8–79 years	273	Not explicitly specified but referred for root canal treatment	5 years (1–29 years)	Full pulpotomy	KH	89 % (1 year) 63 % (10 years)	none
Kumar et al. 2016	RCT	14–32 years	54	Irreversible pulpitis	1 year	Full pulpotomy	MTA KH PRF+MTA	44 % (MTA) 38 % (CH) 36 % (PRF+MTA)	N/S
(Taha, Ahmad et al. 2017)	Prosp.	11–51 years	52	Irreversible pulpitis (> 80 %)	3 years	Full pulpotomy	MTA	92,7 %	none
(Qudeimat et al. 2017)	Prosp.	7–13 years ø 10.7 years	23	Irreversible pulpitis	5 years (19–74 months)	Full pulpotomy	MTA	100 %	N/S
(Linsuwantont et al. 2017)	Retrospect.	7–68 years ø 29 years	55	Irreversible pulpitis	3 years (8–62 months)	Full pulpotomy	MTA	84 %	none
Asgary, Eghbal 2017	RCT	9–65 years	412	Irreversible pulpitis	5 years	Full pulpotomy	MTA CEM	85 % (MTA) 78 % (CEM)	none
Taha, Khazali et al. 2017)	RCT	20–52 years ø 30 years	50	Irreversible pulpitis	2 years	Partial pulpotomy	MTA KH	85 % (MTA) 43 % (CH)	N/S
Taha et al. 2018	Prosp.	19–69 years	52	Irreversible pulpitis	1 year	Full pulpotomy	Biod.	98 %	N/S
Uesrichai et al. 2019	RCT	6–18 years ø 10 years	69	Irreversible pulpitis	32,2 ± 17,9 months	Partial pulpotomy	MTA Biod.	92 % (MTA) 87 % (Biod.)	N/S

(**Abbreviations:** RCT = randomized control trial; Retrospect. = retrospective clinical study; Prosp. = prospective clinical study; N/S = not specified; CH = calcium hydroxide; PRF = platelet-rich fibrin; **abbreviations of hydraulic calcium silicate cements:** MTA = mineral trioxid aggregate); CEM = calcium enriched mixture; Biod. = Biodentine)

**Table 1** Overview of clinical studies investigating vital pulp treatment on permanent teeth with “irreversible pulpitis”.

(Fig. 1 and Tab. 1: G. Krastl)



partial or full pulpotomy was performed (Tab. 1).

Half of the studies as mentioned are randomized controlled trials, and therefore regarded at the highest level of evidence among all primary study types. Still, it must be taken into consideration that even this type of study design can only generate robust results if the planning, conduct and evaluation are methodologically correct and appropriately tailored to the research question. In general, the validity of single studies may be limited by various qualitative deficiencies such as the lack of blinding of the investigators as well as by inaccurately and inconsistently defined success criteria [8]. In most studies, pulpotomy procedures are categorized as successful if there is no clinical or radiological evidence of pulp necrosis. However, the actual condition of the remaining pulp tissue is difficult to assess. The lack of response to sensitivity testing, at least in the case of complete pulpotomy, has to be attributed to the treatment itself and cannot be considered a criterion for failure. Since the most frequent cause of failure after pulpotomy is assumed to be asymptomatic apical periodontitis [31], it must be assumed that pulp necrosis remains undetected and is considered a failure only when radiological signs of apical periodontitis are present. For this reason, long-term studies that span more than 5 years are critical because the success of pulpotomy procedures in cases of irreversible pulpitis has only been proven clinically, but not histologically.

In a randomized, controlled, multicenter study, where pulpotomy was compared to root canal treatment in teeth with irreversible pulpitis, no significant difference between the two treatment options (vital pulp extirpation vs. pulpotomy) were found [5]. However, the success rate for endodontic treatment after vital pulp extirpation after 5 years in this study was 66 %, which is significantly lower than the reported success rates of over 90 % in other studies [22]. Furthermore, a comparison between success rates of pulpotomy and root canal treatment may not be feasible, as, in case of failure, the conditions for long-term preservation of the tooth

are different. If vital pulp treatment fails, root canal treatment can still be performed with high success rates, whereas retreatment shows significantly reduced success rates.

Among the factors that potentially influence the prognosis of vital pulp treatment, patient age is frequently discussed. Favorable conditions for pulp preservation are found in young patients with a high potential for regeneration, provided that the pulp tissue has not been damaged previously [61]. In particular, teeth with immature roots benefit the most from vital pulp treatment which enables continued formation of dentin and cementum and thus further root development. With increasing age, a reduced regenerative capacity is expected due to changes such as a reduced cell number and increased content of fibrous tissue [25, 44]. Nevertheless, patient age does not seem to have a decisive influence on the success rate: In the existing clinical studies on vital pulp treatment of permanent teeth with irreversible pulpitis, patients up to the age of 79 years were included (Table 1).

The question whether teeth after (partial) preservation of pulp vitality after pulpotomy procedures indeed have a better prognosis compared to teeth treated with vital pulp extirpation and subsequent root canal treatment remains unanswered. This would be the case if – given that tooth vitality is preserved in the long-term – the susceptibility to fracture does not increase after this type of treatment. In this respect, the critical long-term data are not available. However, it can be conjectured that the biomechanical stability of a tooth after partial pulpotomy with the preservation of most of the coronal pulp is more similar to a sound and vital tooth compared to a tooth with remnants of vital pulp only in the root canals up to the level of the canal orifices after a full pulpotomy.

#### 4. Conclusion

From a patient's perspective, teeth with deep carious lesions and symptoms of irreversible pulpitis need to be treated in a way that is most likely to keep the affected tooth free of symptoms in the long term and the periradicular tissue healthy. Root canal

treatment subsequent to vital pulp extirpation is a reliable and established method in these cases, which is undoubtedly still to be considered the gold standard. In comparison, the evidence for vital pulp treatment in teeth with irreversible pulpitis is rather sparse at present, especially because long-term data is missing.

In spite of this, based on the current data, pulpotomy can be considered a valid treatment option for irreversible pulpitis and it surely represents an alternative to vital pulp extirpation [37]. In the context of treatment concepts for inflammatory pulp diseases, the shortcomings of the current classification of pulpitis should also be emphasized. A more precise and treatment-oriented classification that reflects the possibilities for tissue preservation would be desirable.

In addition to the correct indication, the success of a (partial or full) pulpotomy to a large extent depends on whether the necessary measures are performed adequately. This implies an aseptic treatment concept with the consistent use of rubber dam and sterile instruments, the use of appropriate magnification aids in order to be able to precisely perform the pulp amputation, thorough endodontic knowledge to assess the condition of the exposed pulp, disinfection and capping of the tissue with a suitable bioactive material and an immediate adhesive seal and permanent coronal restoration. Recent data show that deviations from these requirements significantly reduce the success of vital pulp treatment measures after pulp exposure [9].

Given that every dentist should be familiar with pulpotomies as emergency treatment for irreversible pulpitis, a next step would be to establish pulpotomy as a definitive measure (under the condition of an enhanced treatment protocol) besides root canal treatment. Especially in young patients with immature teeth, long-term pulp preservation would be most beneficial.

However, the effort required to correctly perform a (partial or full) pulpotomy as a definitive measure is unfortunately not sufficiently reflected in the payment system of health insurance companies in Germany.

The present position paper is based on the current state of scientific

knowledge. As this field is actively researched, the necessity of updates in the near future is anticipated.

### Conflicts of interest

Till Dammaschke states that he has received honoraria from Septodont for lectures. The authors G. Krastl, K. Galler, and E. Schäfer declare that there is no conflict of interest as defined by the guidelines of the International Committee of Medical Journal Editors.

### References

- American Association of Endodontists: AAE Consensus conference recommended diagnostic terminology. *J Endod* 2007; 35: 1634
- American Association of Endodontists: Glossary of endodontic terms. 10th Edition. 2020. (<https://www.aae.org/specialty/clinical-resources/glossary-endodontic-terms/>)
- Asgary S, Eghbal MJ: Treatment outcomes of pulpotomy in permanent molars with irreversible pulpitis using biomaterials: a multi-center randomized controlled trial. *Acta Odontol Scand* 2013; 71: 130–136
- Asgary S, Eghbal MJ, Bagheban AA: Long-term outcomes of pulpotomy in permanent teeth with irreversible pulpitis: a multi-center randomized controlled trial. *Am J Dent* 2017; 30: 151–155
- Asgary S, Eghbal MJ, Fazlyab M, Bagheban AA, Ghoddsi J: Five-year results of vital pulp therapy in permanent molars with irreversible pulpitis: a non-inferiority multicenter randomized clinical trial. *Clin Oral Investig* 2015; 19: 335–341
- Asgary S, Eghbal MJ, Ghoddsi J: Two-year results of vital pulp therapy in permanent molars with irreversible pulpitis: an ongoing multicenter randomized clinical trial. *Clin Oral Investig* 2014; 18: 635–641
- Bakhtiar H, Nekoofar MH, Aminshakib P et al.: Human pulp responses to partial pulpotomy treatment with TheraCal as compared with Biodentine and ProRoot MTA: a clinical trial. *J Endod* 2017; 43: 1786–1791
- Bjørndal L: Is pulpotomy preferable to root treatment where there is pulp exposure? *Evid Based Dent* 2019; 20: 117–118
- Bjørndal L, Fransson H, Bruun G et al.: Randomized clinical trials on deep carious lesions: 5-year follow-up. *J Dent Res* 2017; 96: 747–753
- Buchalla W, Frankenberger R, Galler KM et al.: Aktuelle Empfehlungen zur Kariesexkavation. *Wissenschaftliche Mitteilung der Deutschen Gesellschaft für Zahnerhaltung (DGZ). Deutsche Zahnärztliche Zeitschrift* 2017; 72: 484–494
- Bürklein S, Sabandal M, Dammaschke T: Pulp: Beurteilung von Vitalität und Sensibilität. *Zahnmedizin up2date* 2019; 13: 355–369
- Chatterton DB: Pulp curettage. *J Am Dent Assoc* 1952; 45: 462–465
- Cho SY, Seo DG, Lee SJ, Lee J, Lee SJ, Jung IY: Prognostic factors for clinical outcomes according to time after direct pulp capping. *J Endod* 2013; 39: 327–331
- Christensen GJ: Pulp capping 1998. *J Am Dent Assoc* 1998; 129: 1297–1299
- Cisneros-Cabello R, Segura-Egea JJ: Relationship of patient complaints and signs to histopathologic diagnosis of pulpal condition. *Aust Endod J* 2005; 31: 24–27
- Cohenca N, Paranjpe A, Berg J: Vital pulp therapy. *Dent Clin North Am* 2013; 57: 59–73
- Cvek M, Cleaton-Jones PE, Austin JC, Andreasen JO: Pulp reactions to exposure after experimental crown fractures or grinding in adult monkeys. *J Endod* 1982; 8: 391–397
- Dammaschke T, Galler KM, Krastl G: Current recommendations for vital pulp treatment. *Dtsch Zahnärztl Z Int* 2019; 1: 43–52
- Eghbal MJ, Haeri A, Shahravan A, et al.: Postendodontic pain after pulpotomy or root canal treatment in mature teeth with carious pulp exposure: a multicenter randomized controlled trial. *Pain Res Manag* 2020; 2020: 5853412
- Eren B, Onay EO, Ungor M: Assessment of alternative emergency treatments for symptomatic irreversible pulpitis: a randomized clinical trial. *Int Endod J* 2018; 51 (Suppl 3): e227–e237
- Duncan HF, Galler KM, Tompson PL et al.: European Society of Endodontology position statement: management of deep caries and the exposed pulp. *Int Endod J* 2019; 52: 923–934
- Friedman S, Abitbol S, Lawrence HP: Treatment outcome in endodontics: the Toronto study. Phase 1: initial treatment. *J Endod* 2003; 29: 787–793
- Fuss Z, Lustig J, Katz A, Tamse A: An evaluation of endodontically treated vertical root fractured teeth: impact of operative procedures. *J Endod* 2001; 27: 46–48
- Galler KM, Dammaschke T, Krastl G: Vitalerhaltung der Pulpa nach Trauma. *Die Quintessenz* 2019; 70: 1042–1048
- Goodis HE, Kahn A, Simon S: Aging and the pulp. In: Hargreaves K, Goodis HE, Tay F (Hrsg): *Seltzer and Bender's dental pulp*. Quintessenz, Berlin 2012
- Heide S, Mjør IA: Pulp reactions to experimental exposures in young permanent monkey teeth. *Int Endod J* 1983; 16: 11–19
- Hilton TJ, Ferracane JL, Mancl L: Northwest practice-based research collaborative in evidence-based D. Comparison of CaOH with MTA for direct pulp capping: a PBRN randomized clinical trial. *J Dent Res* 2013; 92: 165–225
- Kang CM, Sun Y, Song JS et al.: A randomized controlled trial of various MTA materials for partial pulpotomy in permanent teeth. *J Dent* 2017; 60: 8–13
- Krastl G, Allgayer N, Lenherr P, Filippi A, Taneja P, Weiger R: Tooth discoloration induced by endodontic materials: a literature review. *Dent Traumatol* 2013; 29: 2–7
- Krastl G, Weiger R: Vital pulp therapy after trauma. *ENDO (Lond Engl)* 2014; 8: 293–300
- Kumar V, Juneja R, Duhan J, Sangwan P, Tewari S: Comparative evaluation of platelet-rich fibrin, mineral trioxide aggregate, and calcium hydroxide as pulpotomy agents in permanent molars with irreversible pulpitis: a randomized controlled trial. *Contemp Clin Dent* 2016; 7: 512–518
- Kundzina R, Stangvaltaite L, Eriksen HM, Kerosuo E: Capping carious exposures in adults: a randomized controlled trial investigating mineral trioxide aggregate versus calcium hydroxide. *Int Endod J* 2017; 50: 924–932
- Kunert GG, Kunert IR, da Costa Filho LC, de Figueiredo JAP: Permanent teeth pulpotomy survival analysis: retrospective follow-up. *J Dent* 2015; 43: 1125–1131
- Langeland K: Management of the inflamed pulp associated with deep carious lesion. *J Endod* 1981; 7: 169–181
- Langer M, Wieskötter B, Oeckenpöhler S, Breiter S: Akute Infektionen im Bereich des Fingernagels – die akuten Paronychien. *Handchirurgie Scan* 2014; 03: 69–85
- Lertchirakarn V, Palamara JE, Messer HH: Patterns of vertical root fracture: factors affecting stress distribution in the root canal. *J Endod* 2003; 29: 523–528
- Li Y, Sui B, Dahl C et al.: Pulpotomy for carious pulp exposures in permanent teeth: A systematic review and meta-analysis. *J Dent* 2019; 84: 1–8
- Lin LM, Ricucci D, Saoud TM, Sigurdsson A, Kahler B: Vital pulp therapy of mature permanent teeth with irreversible pulpitis from the perspective of pulp biology. *Aust Endod J* 2020; 46: 154–166
- Linsuwanont P, Wimonsutthikul K, Pothimoke U, Santiwong B: Treatment outcomes of mineral trioxide aggregate pulpotomy in vital permanent teeth with carious pulp exposure: the retrospective study. *J Endod* 2017; 43: 225–230
- Matsuo T, Nakanishi T, Shimizu H, Ebisu S: A clinical study of direct pulp cap-

ping applied to carious-exposed pulps. *J Endod* 1996; 22: 551–556

41. Merdad K, Sonbul H, Bukhary S, Reit C, Birkhed D: Caries susceptibility of endodontically versus nonendodontically treated teeth. *J Endod* 2011; 37: 139–142

42. Michaelson PL, Holland GR: Is pulpitis painful? *Int Endod J* 2002; 35: 829–832

43. Munir A, Zehnder M, Rechenberg DK: Wound lavage in studies on vital pulp therapy of permanent teeth with carious exposures: a qualitative systematic review. *J Clin Med* 2020; 9: 984. doi: 10.3390/jcm 9040984

44. Murray PE, Stanley HR, Matthews JB, Sloan AJ, Smith AJ: Age-related odontometric changes of human teeth. *Oral Surg Oral Med Oral Pathol Oral Radiol Endod* 2002; 93: 474–482

45. Ng YL, Mann V, Rahbaran S, Lewsey J, Gulabivala K: Outcome of primary root canal treatment: systematic review of the literature – part 2. Influence of clinical factors. *Int Endod J* 2008; 41: 6–31

46. Nilsen BW, Jensen E, Ortengren U, Michelsen VB: Analysis of organic components in resin-modified pulp capping materials: critical considerations. *Eur J Oral Sci* 2017; 125: 183–194

47. Qudeimat MA, Alyahya A, Hasan AA: Mineral trioxide aggregate pulpotomy for permanent molars with clinical signs indicative of irreversible pulpitis: a preliminary study. *Int Endod J* 2017; 50: 126–134

48. Ricucci D, Loghin S, Siqueira JF, Jr: Correlation between clinical and histologic pulp diagnoses. *J Endod* 2014; 40: 1932–1939

49. Ricucci D, Siqueira JF, Jr, Li Y, Tay FR: Vital pulp therapy: histopathology and histobacteriology-based guidelines to treat teeth with deep caries and pulp exposure. *J Dent* 2019; 86: 41–52

50. Ricucci D, Siqueira JF, Jr, Loghin S, Lin LM: Pulp and apical tissue response to deep caries in immature teeth: a histologic and histobacteriologic study. *J Dent* 2017; 56: 19–32

51. Schwendicke F, Frencken JE, Bjørndal L et al.: Managing carious lesions: consensus recommendations on carious tissue removal. *Adv Dent Res* 2016; 28: 58–67

52. Schwendicke F, Stolpe M: Direct pulp capping after a carious exposure versus root canal treatment: a cost-effectiveness analysis. *J Endod* 2014; 40: 1764–1770

53. Seltzer S, Bender IB, Ziontz M: The dynamics of pulp inflammation: correlations between diagnostic data and actual histologic findings in the pulp. *Oral Surg Oral Med Oral Pathol* 1963; 16: 846–871

54. Simon S, Perard M, Zanini M, et al: Should pulp chamber pulpotomy be seen as a permanent treatment? Some prelimi-

nary thoughts. *Int Endod J* 2013; 46: 79–87

55. Stashenko P, Teles R, D’Souza R: Periapical inflammatory responses and their modulation. *Crit Rev Oral Biol Med* 1998; 9: 498–521

56. Taha NA, Abdelkhalder SZ: Outcome of full pulpotomy using Biodentine in adult patients with symptoms indicative of irreversible pulpitis. *Int Endod J* 2018; 51: 819–828

57. Taha NA, Ahmad MB, Ghanim A: Assessment of mineral trioxide aggregate pulpotomy in mature permanent teeth with carious exposures. *Int Endod J* 2017; 50: 117–125

58. Taha NA, Khazali MA: Partial pulpotomy in mature permanent teeth with clinical signs indicative of irreversible pulpitis: a randomized clinical trial. *J Endod* 2017; 43: 1417–1421

59. Tozar KN, Erkmen Almaz M: Evaluation of the efficacy of erbium, chromium-doped yttrium, scandium, gallium, and garnet laser in partial pulpotomy in permanent immature molars: a randomized controlled trial. *J Endod* 2020; 46: 575–583

60. Uesrichai N, Nirunsittirat A, Chuveera P, Srisuwan T, Sastraruji T, Chompu-Inwai P:

Partial pulpotomy with two bioactive cements in permanent teeth of 6- to 18-year-old patients with signs and symptoms indicative of irreversible pulpitis: a noninferiority randomized controlled trial. *Int Endod J* 2019; 52: 749–759

61. Wang G, Wang C, Qin M: Pulp prognosis following conservative pulp treatment in teeth with complicated crown fractures-A retrospective study. *Dent Traumatol* 2017; 33: 255–260

62. Wolters WJ, Duncan HF, Tomson PL et al.: Minimally invasive endodontics: a new diagnostic system for assessing pulpitis and subsequent treatment needs. *Int Endod J* 2017; 50: 825–829

63. Yazdani S, Jadidfard MP, Tahani B, Kazemian A, Dianat O, Alim Marvasti L: Health technology assessment of CEM pulpotomy in permanent molars with irreversible pulpitis. *Iran Endod J* 2014; 9: 23–29

64. Zanini M, Hennequin M, Cousson PY: Which procedures and materials could be applied for full pulpotomy in permanent mature teeth? A systematic review. *Acta Odontol Scand* 2019; 77: 541–551



(Photo: Gabriel Krastl)

**PROF. DR. GABRIEL KRASTL**  
 Department for Conservative Dentistry  
 and Periodontology  
 University Hospital Würzburg  
 Pleicherwall 2, 97070 Würzburg  
 Germany  
 Krastl\_G@ukw.de



(Photo: T. Dammaschke)

**PROF. DR. TILL DAMMASCHKE**  
 Department of Periodontology and  
 Operative Dentistry  
 University Hospital Münster  
 Albert-Schweitzer-Campus 1,  
 Building W 30  
 48149 Münster, Germany  
 tillda@uni-muenster.de



(Photo: UKR)

**PROF. DR. KERSTIN GALLER**  
 Department for Conservative Dentistry  
 and Periodontology  
 Regensburg University Hospital  
 Franz-Josef-Strauß-Allee 11  
 93053 Regensburg, Germany  
 Kerstin.Galler@klinik.uni-regensburg.de



(Photo: UKM)

**PROF. DR. EDGAR SCHÄFER**  
 University Clinic for Dental Medicine  
 Polyclinic for Dental Preservation  
 Waldeyerstr. 30, 48149 Münster,  
 Germany  
 eschaefer@uni-muenster.de