

INTRODUCTION

Pleomorphic adenoma, also known as benign mixed tumour, is the most common salivary tumor, constituting up to two-thirds of all salivary gland neoplasms. It shows a female predilection of 2:1.

CASE REPORT

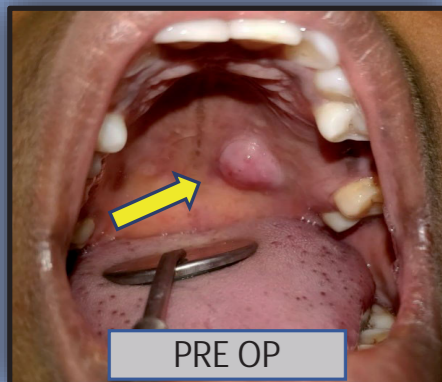
A 40-year-old female presented with a painless swelling in the posterior palate for 2 months. It was a slow growing, painless swelling which gradually increased in size to attain its current size.

ON EXAMINATION

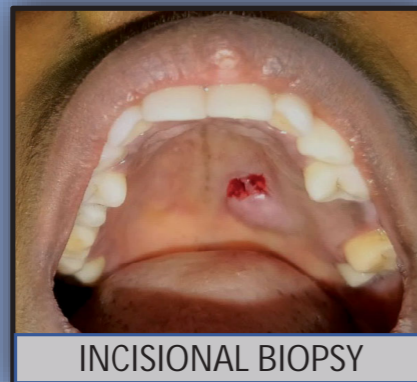On intra oral examination, a single ovoid-shaped swelling was noted in the left posterior part of the hard palate measuring 1.5cm x 2cm

The overlying mucosa appeared healthy and smooth without secondary changes.

On palpation, the swelling was unilocular, nontender, non pulsatile, firm, and immovable with well-defined margins. The mucosa over the lesion was stretched and non pinchable.



PRE OP



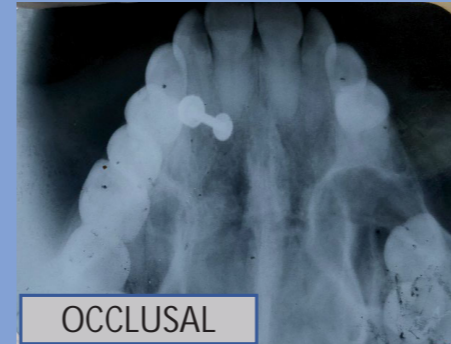
INCISIONAL BIOPSY

INVESTIGATIONS

IOPA and occlusal radiographs did not reveal any pathologic change in bone structure. Aspiration with a wide bore needle did not reveal any aspirate. Incisional biopsy was performed



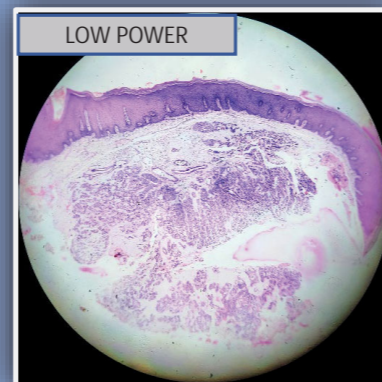
IOPA



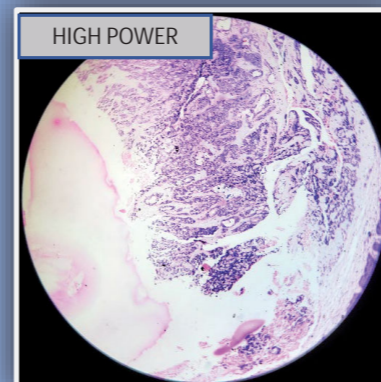
OCCLUSAL

HISTOPATHOLOGY

Glandular lesion which is partially encapsulated by fibrous tissue. Glandular epithelium proliferates in the form of ductal structures with eosinophilic coagulum, sheets, cords, and strands with intervening myxoid stroma. The cells are round to ovoid with vesicular nuclei and eosinophilic cytoplasm. Myoepithelial cells show spindle, plasmacytoid, and clear cell differentiation.



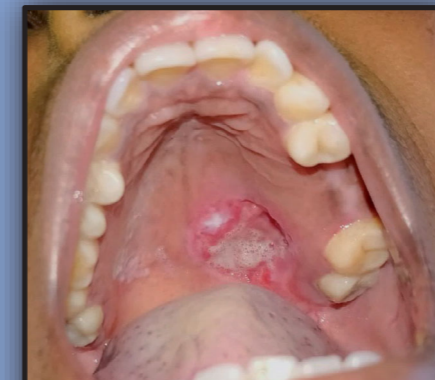LOW POWER



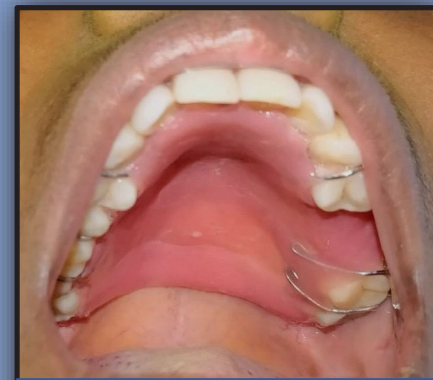HIGH POWER

TREATMENT

Wide local excision was done under GA and a palatal plate was given.



2 WEEKS POST OP



PALATAL PLATE

DISCUSSION

The treatment of PA is essentially surgical excision. Because these tumours are radioresistant, radiation therapy is contraindicated. The recurrence of PA is attributed to implantation from capsule rupture, islands of tumor tissue left behind after surgery. Therefore, long-term follow-up is required

REFERENCE

Arumugam P, Christopher PJ, Kumar S, Kengasubbiah S, Shenoy V. Pleomorphic adenoma of the palate: A case report. Cureus. 2019 Mar 25;11(3).

Kayal L, Jayachandran S, Niranzana PA. A rare case of sclerosing mucoepidermoid carcinoma of minor salivary gland-A diagnostic enigma. Int J Dent Case Rep. 2011;1:43-8.