


Autologous bone block graft with xeno-enxerto and PRGF for premolar maxillar rehabilitation - Case report



2019
Gomes da Silva, A.*
Alves, M.**
Amorim, M.***

* DDS. Oral surgery specialist. Coordinator of the Dental Medicine Unit of the Clinical Center of Lisbon - SSCGD.
**DDS. Exclusive practice in oral rehabilitation. Dental Medicine Unit of the Clinical Center of Lisbon - SSCGD.
*** DDS. Dental Medicine Unit of the Clinical Center of Lisbon - SSCGD.

The authors present a clinical case of bone atrophy at the level of premolars of the 2nd Q, regenerated with autograft in a block collected from the mandible body (oblique line), xenograft, PRGF and collagen membrane fixed with metal pins. Various types of bone substitutes are available for this type of surgery. For many authors, the autograft is considered the ideal graft. In this case, given the great bone atrophy in thickness and height and the demanding aesthetic component (high smile line), exactly this type of graft was chosen.

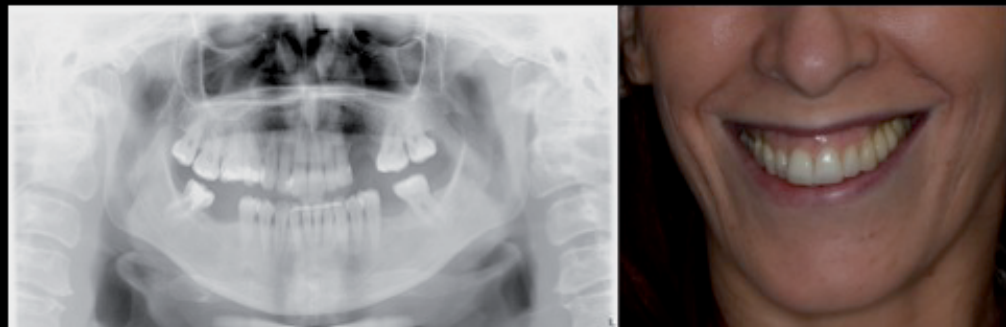

Fig. 1 - Orthopantomography.

Fig. 2 - High smile line

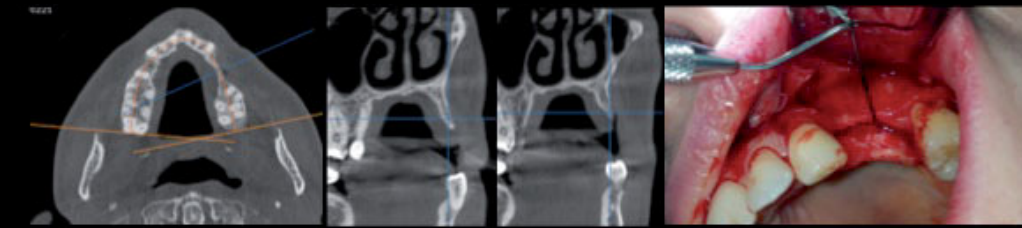


Fig. 3, 4 e 5 - CBCT

Fig. 6 - Intra-oral bone defect

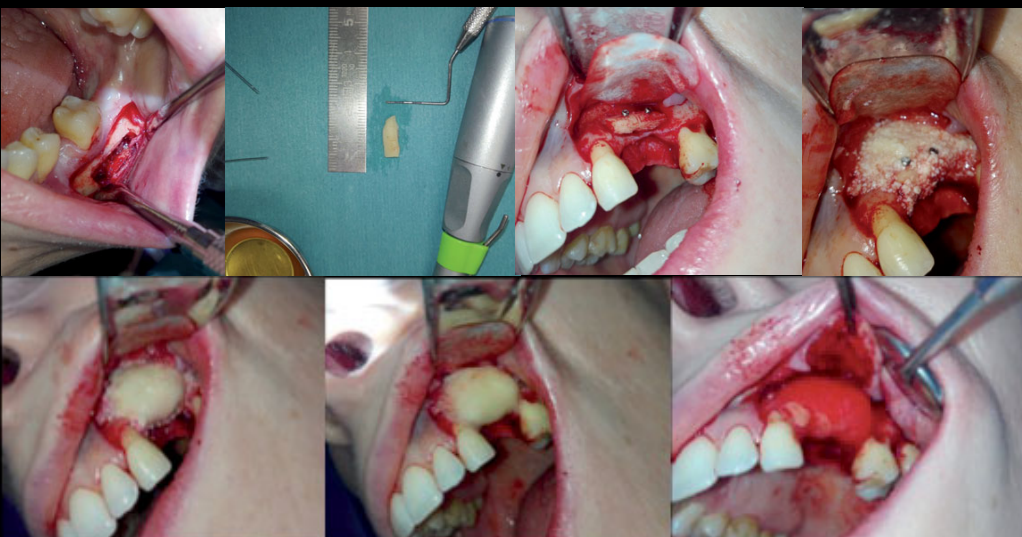

Fig. 7, 8, 9, 10, 11, 12, 13 - intraoperative photographs (surgery 1).

Clinical case:

Female patient, 38 years old, leukodermal and without personal history of relevance, is referred to an oral implantology appointment to rehabilitate the edentulous region of the 2nd Q. Previous history of orthodontic treatment and surgical extractions of 24 and 25.

In the absence of 24 and 25 with an evident and important defect in this area, CBCT was requested, which confirms the great bone atrophy. We opted for a mixed autograft bone graft collected from the mandible (external oblique line) and xenograft with PRGF (plasma rich in growth factors) and resorbable collagen membrane fixed with metal pins.

After infiltrative anesthesia of the area to be operated and of the molar area of the mandible, osteotomy with piezosurgery was performed with the collection of a bone block (1.5x0.6 cm) which was reserved in plasma rich in growth factors (fraction 2). Then, a full-thickness flap was performed with canine mesial and distal 1st molar discharge, cortical perforations were made and with two osteosynthesis screws, the graft block was fixed in the receiving area, xenograft was added and covered first with PRGF membrane fraction 2, followed by PRGF membrane fraction 1 and finally with resorbable collagen membrane fixed with metal pins and direct closure of the flap with 5/0 nylon suture.

After 7 months, surgery for placing two implants (4/10 and 4.5/10 BTI) was performed with the removal of the osteosynthesis screws. At the end of 3 months, these same implants were rehabilitated with metal-ceramic fixed prosthesis.

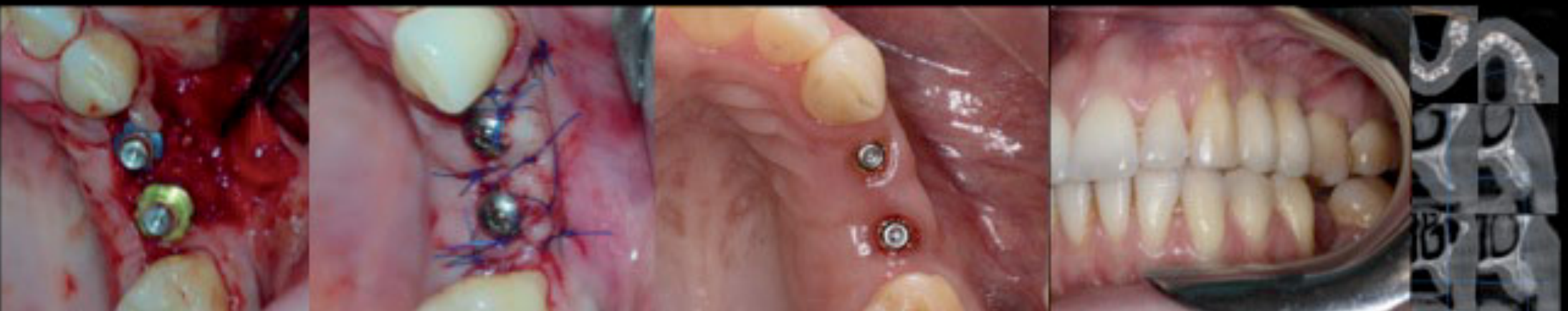

Fig. 14, 15 e 16 - Intraoperative photographs (surgery 2).

Fig. 17 - Final photograph.

Fig. 18 - CBCT (before and after).

Conclusion:

In the absence of quantity and quality of bone for rehabilitation with dental implants, the surgeon has available surgical techniques and varied bone substitutes. One of these techniques is the autograft, considered by many to be the "Gold Standard" of bone grafting.

In this case and in view of the need for a significant horizontal increase, as well as the desirable vertical increase and the availability of intraoral donors, this type of graft was obtained. The result obtained is predictable and with very satisfactory results.