

The iSy - Implant Concept

1-year data - integration in daily practice - case report

ULRICI S, BARTH TH, BARTH C

DENTALE - dental medical competence center - Leipzig - Germany

Implantation has become established in dentistry and the osseointegration of dental implants is regarded as assured (1). New concepts aim to simplify and shorten the treatment process. The application of the iSy Implant Concept, which has been used in our practice since 2013, enables a simplified treatment of standard implant prosthetic cases, in accordance with the ITI SAC - Classification (2), using standardized processes, and provides a lower-cost, high-quality implant therapy.

In our view the iSy concept is, given optimal hard and soft tissue conditions, applicable in function-related cases of

- 1) single tooth and edentulous spaces in the posterior region
- 2) free distal ends
- 3) edentulous jaw

In accordance with the iSy- and our concept, this applies to cases without augmentation procedures and open healing processes. This conceptual open healing has reduced the effort of surgical exposure. The open healing implants have a similar success rate to submerged healing implants (3).

Also with the prosthetic treatment we are pursuing a simple, standardized approach. For single-tooth restorations this is realized via a so-called hybrid-abutment-crown. Which is a full-ceramic-, occlusal screwed, lithium disilicate crown, bonded to the titanium base CAD/CAM. In edentulous jaw conditions the prosthetic connection takes place via LOCATOR® Implant Attachments.

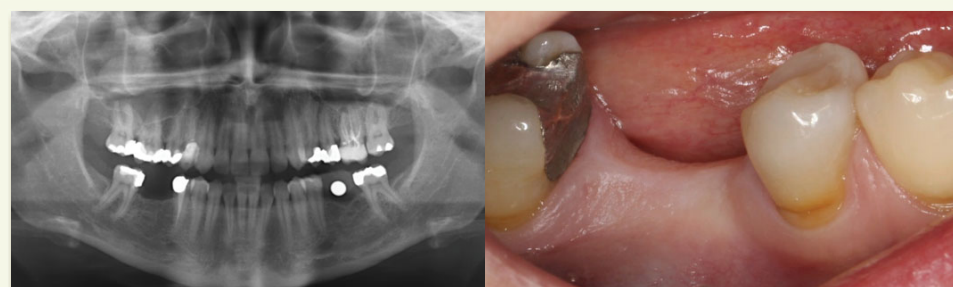1- year data

	patients		implants		20 - 40 y				40 - 60 y				> 60 y			
	total		total		patients	implants	patients	implants	patients	implants	patients	implants	patients	implants		
total	51	100 %	99	100 %	13	25 %	15	15 %	10	20 %	15	15 %	28	55 %	69	70 %
single tooth (1)	28	55 %	33	33 %	13	25 %	15	15 %	8	16 %	9	9 %	7	14 %	9	9 %
free-end-sit (2)	7	14 %	15	15 %	0	0 %	0	0 %	1	2 %	2	2 %	6	12 %	13	13 %
edentulous (3)	16	31 %	51	52 %	0	0 %	0	0 %	1	2 %	4	4 %	15	29 %	47	47 %

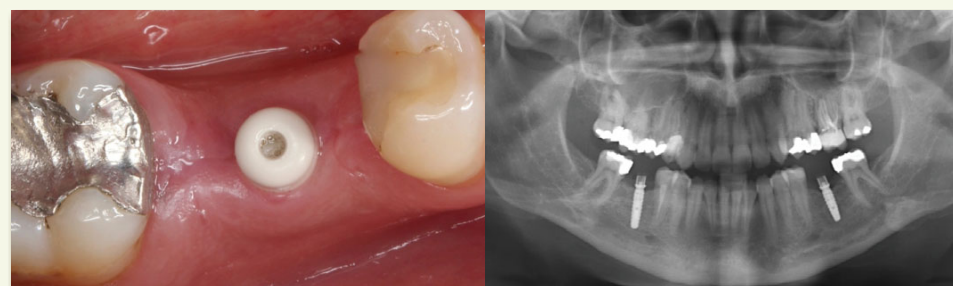
- (1) For 52 patients we implanted 99 iSy implants in the three standard indications; until now no implant failure
- (2) A single tooth restoration took place at about half of our patients
- (3) About 50% of the implants were placed in the edentulous jaw
- (4) 70% of the implants were placed in patients of advanced age (> 60 y)
- (5) More than half of the patients were over 60 years old

Conclusion

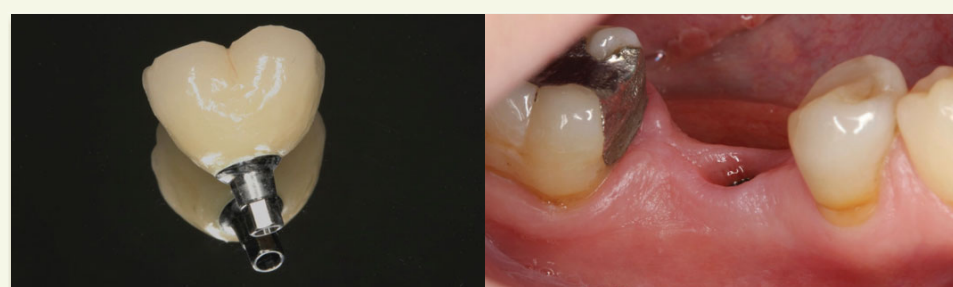We see the iSy implant system as a complementary implant for standard indications. At a consistent application of this concept, cases, primarily in older patients with the clinical finding of single-tooth gaps or edentulous jaws, to be treated with implant-prosthetic procedures, which could not have been treated otherwise, mainly for financial reasons. Any modification of this standardized simple implant-prosthetic treatment leads to extra effort and increases costs. This is contrary to the innovative basic idea of this easy implant-concept.



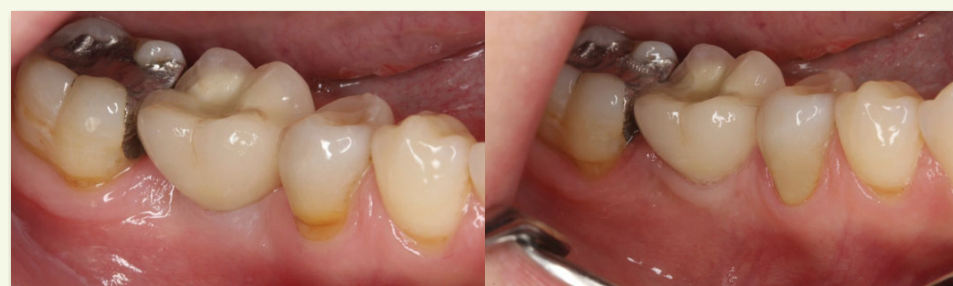Single tooth replacement | initial situation: Orthopantomography (OPT), clinical



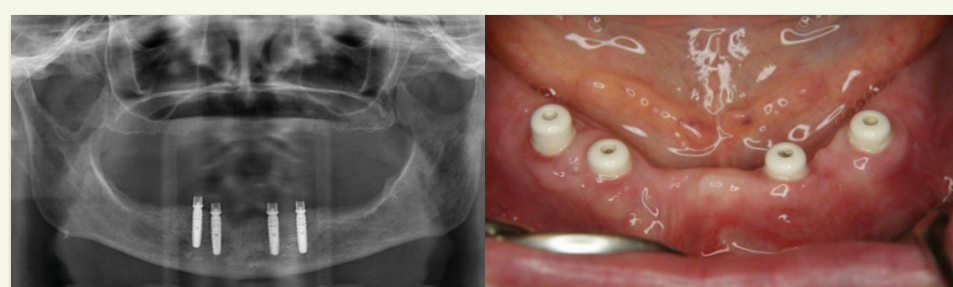
Single tooth replacement | after surgery: clinical healing after 12d, OPT postOP



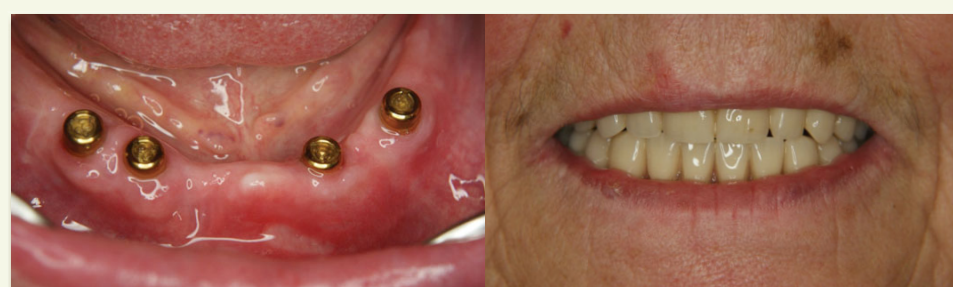Single tooth replacement | Hybrid-abutment-crown, emergence profile



Single tooth replacement | Prosthodontics: completion, 1-year-situation



edentulous mandible | situation after surgery: OPT, clinical



edentulous mandible | Prosthodontics: clinical with Locator®, Overdenture view

References:

- (1) Albrektsson T, Zarb G, Worthington P, Eriksson AR: The long-term efficacy of currently used dental implants: a review and proposed criteria of success., The International Journal of Oral- and Maxillofacial Implants, 1986 (1) 11-25
- (2) Dawson A; Chen S: The SAC Classification in Implant Dentistry, Quintessence Publishing, 2009
- (3) Abrahamsson I, Berglundh T, Moon IS, Lindhe J: Peri-implant tissues at submerged and non-submerged titanium implants., Journal of Clinical Periodontology, 1996 26(9) 600-607

Stefan Ulrici

DENTALE-Leipzig

Prager Strasse 2

04103 Leipzig - Germany

Email: stefan.ulrici@dentale.de