

BIOESTHETICS – NATURAL LASTING BEAUTY

Language: English

Authors:

P.G.Student Dr.Deepti Pitalia, Prof. Dr. Shashit Shetty B., H.O.D, Assoc. Prof. Dr. Gurudutt Nayak, Reader Dr. Manoj Hans, Dr. B.R. Ambedkar University Agra, K.D. Dental college and hospital, Department of Conservative Dentistry and Endodontics, Mathura, Uttar Pradesh, India

Date/Event/Venue:

9th to 12th December, 2010
25th FODI and 18th IES National Conference
Chennai (Tamil Nadu,India)

BIOESTHETICS – NATURAL LASTING BEAUTY

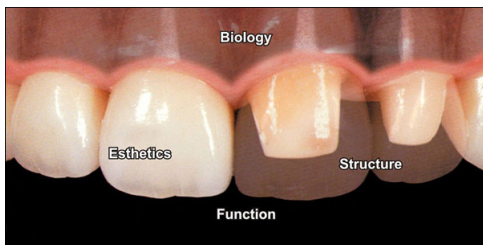


Fig. 1: Bioesthetics is a conservative interdisciplinary approach to the restoration of dentition in its natural form and function. I.2-The more natural each component of the dental system is, the more alive it is. The more alive the oral system is, the healthier it is. The more natural the form, the more effective the function of the entire oral system. Natural form and function create the quality of beauty.

PRINCIPLES OF BIOESTHETICS PROPER FORM AND GOOD CROWN MORPHOLOGY

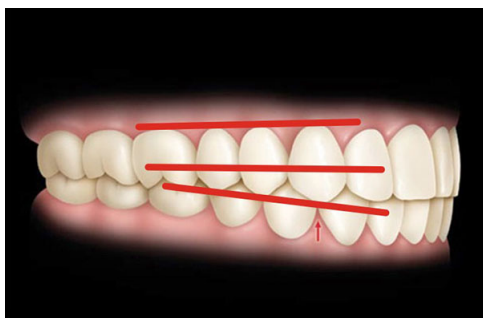


Fig. 2: GRADUATION EFFECT Posterior converging lines produced by joining cusp tips, cemento enamel junction, contact areas of canine, 1st PM, 2nd PM. II.1a -When mandibular canine move medially about 1 mm in lateral chewing function the buccal cusp of I premolar aid the canine due to graduation effect.

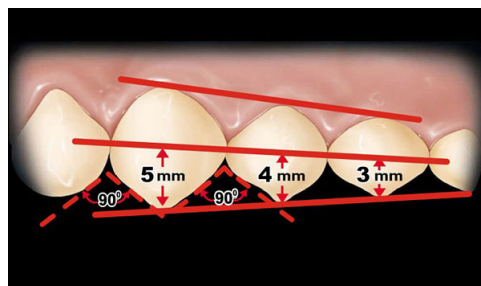


Fig. 3: The mesial and distal embrasures of the canine should be about 90° generally which allow space for more natural (sharper) cusp forms of the mandibular posterior teeth.

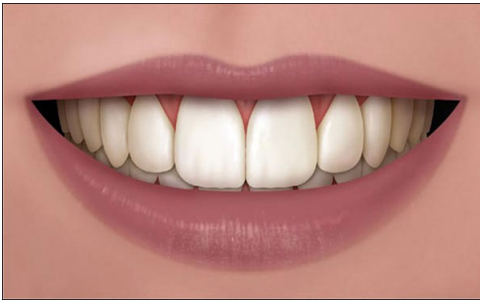

Fig. 4: SMILE LINE Ideal smile line allow the mandibular canines to pass freely during the incisive movements.

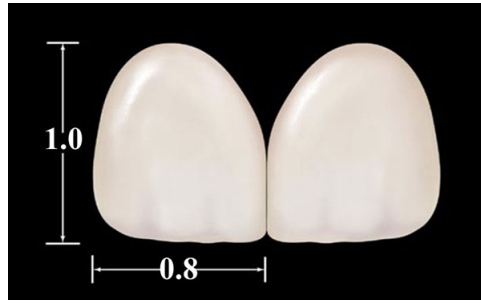

Fig. 5: PRINCIPLES OF PROPORTION AND CENTRAL DOMINANCE The width to length ratio (4:5) of the two maxillary central incisors is to provide maximum functional contact with the four mandibular incisors when the mandible move forward in incisive guidance.

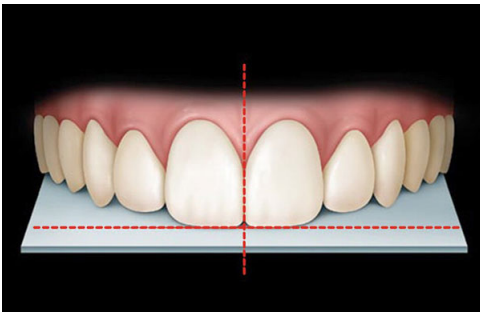


Fig. 6: MIDLINE The midline of maxillary CI should be perpendicular to the incisal plane without which an even contact with the lower incisors is not possible in incisive function.

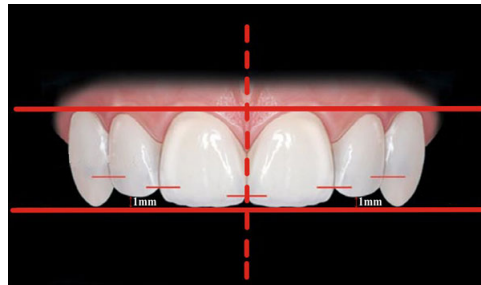


Fig. 7: INCISAL EDGE POSITION The incisal edge position of the maxillary lateral incisor should be approximately 1 mm apical to the incisal edges of the central incisors and canine to provide space for cusp tips of mandibular canine in protusion.

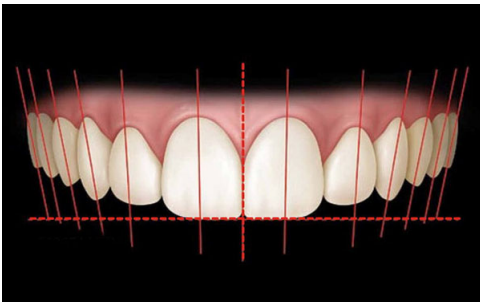


Fig. 8: AXIAL INCLINATION From the central incisor to the canine, there should be a natural progressive increase in the mesial inclination of each subsequent anterior tooth. This allows compensation for the arch width difference between the maxillary and the mandibular teeth permitting the correct anterior coupling of the incisors.

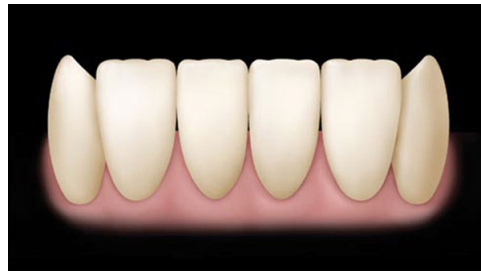

Fig. 9: MANDIBULAR ANTERIOR The mandibular canine should be slightly longer than the mandibular incisors. This maximizes anterior guidance. The incisal embrasures should be minimized, creating a wider masticatory blade.

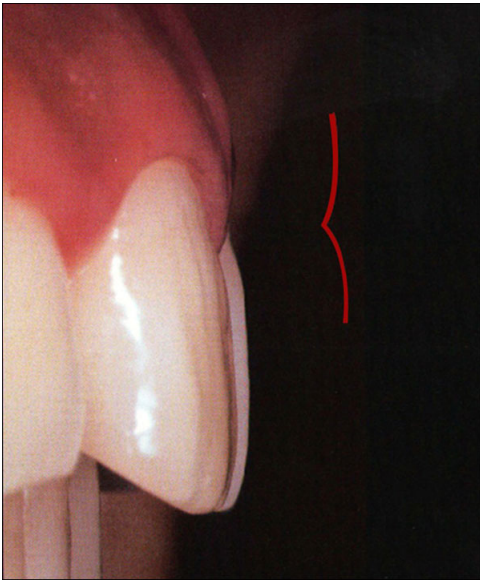


Fig. 10: AXIAL CROWN CONTOUR Cervical coronal contour should be symmetrical to apical contour- "Gull wing pattern"

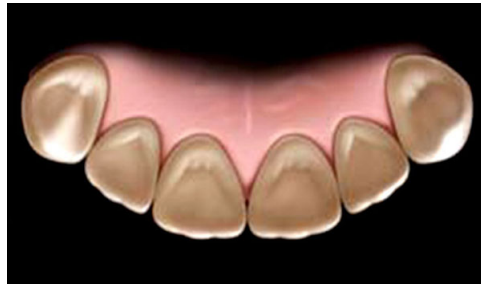

Fig. 11: MAXILLARY ANTERIOR Mesial and distal marginal ridges - strengthen the tooth against off-axis loads. The prominent lingual lobe of the maxillary canine maximizes the canine guidance.

GOOD OCCLUSION

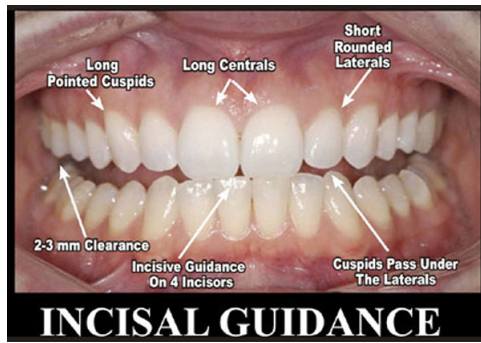
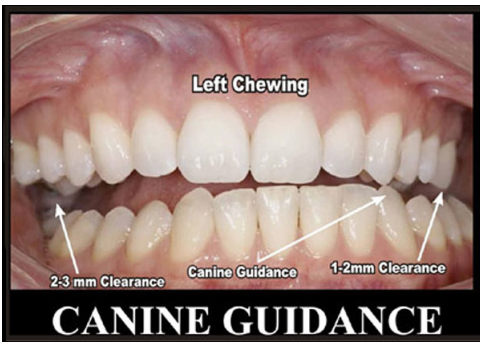

Fig. 12a+b: HARMONIZED ANTERIOR GUIDANCE Proper anterior guidance result in proper posterior clearance which allows: Efficient sharp cusp form without interferences in function and physiologic flexure of mandible under masticatory load.

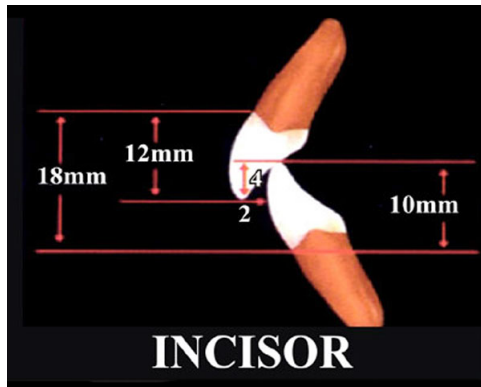
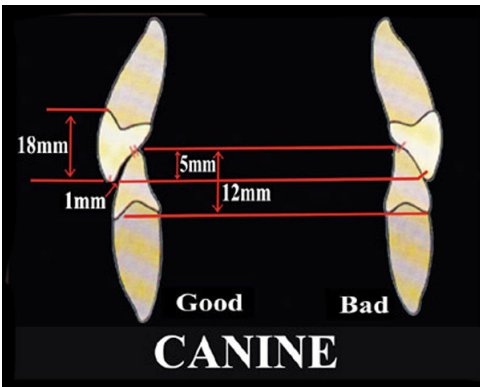


Fig. 13a+b: PROPER OVERJET AND OVERBITE Proper overjet and overbite with proper axial inclination facilitates the guidance of the posterior teeth with the condyles in centric relationship.

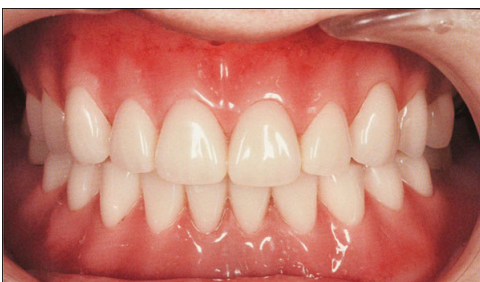

Fig. 14: STABLE CENTRIC RELATION CONTACTS This help in maintaining total craniomandibular stability which is important to comfort,function and longevity of dental restoration.

PERIODONTAL LIGAMENT-MUCOSA-LIPS-TONGUE-CHEEKS-MUSCLES-TMJ

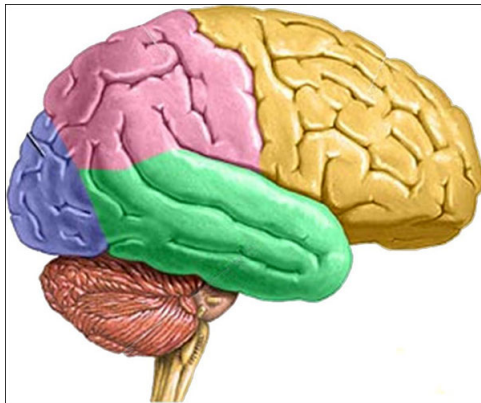
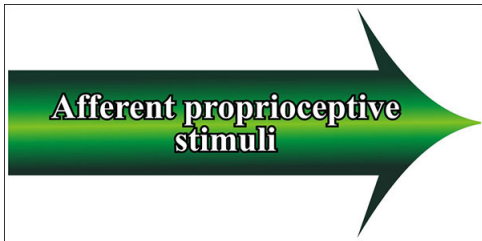


Fig. 15

Fig. 16: Brain

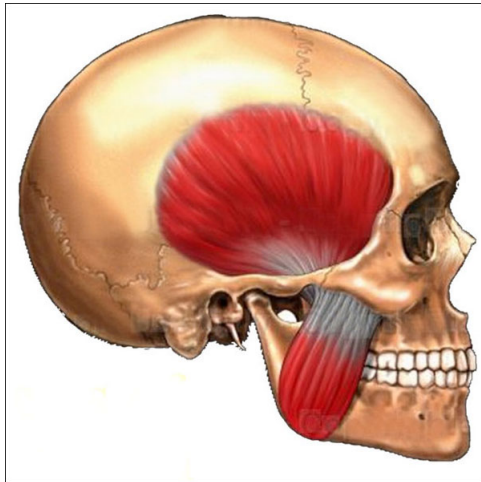
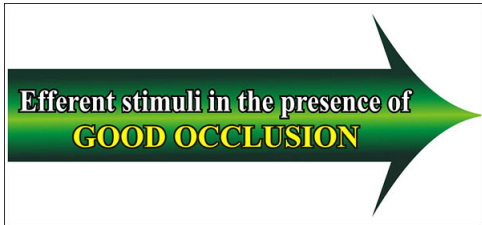

Fig. 17

Fig. 18: Muscles of mastication



Fig. 19: Hence by applying the principles of bioesthetics the function of restoration can be enhanced

Literature

1. Kenley Hunt, Mitch Turk: Correlation of the AACD Accrediation criteria and the Human Biologic Model. The Journal of cosmetic Dentistry 2005;21(3).
2. Lee RL. Esthetics and its relationship to function.In:Rufenacht CR. Fundamental of esthetics,Chicago IL;Quitessence publishing Co. 1990;137-208.
3. Kenley H Hunt:Full Mouth Multidisciplinary restoration using the biological approach;a case report.Pract Proced Aesthet dent 2001;13(5):399-406.
4. Hal Steward:Conservative dentistry and bioesthetic principles. Contemporary esthetics;June 2007.

This Poster was submitted by Dr. Deepti Pitalia.

Correspondence address:

Dr. Deepti Pitalia

K.D. Dental College and Hospital, Department of Conservative Dentistry and Endodontics

P.O. Chittikara, NH-2, Delhi-Mathura Highway

Mathura, Uttar Pradesh-281001

India

Poster Faksimile:

BIOESTHETICS

NATURAL LASTING BEAUTY

Bioesthetics is a conservative interdisciplinary approach to the restoration of dentition in its natural form and function.


The more natural each component of the dental system is, the more alive it is. The more alive the oral system is, the healthier it is. The more natural the form, the more effective the function of the entire oral system. Natural form and function create the quality of beauty.

PRINCIPLES OF BIOESTHETICS

PROPER FORM AND GOOD CROWN MORPHOLOGY


GRADUATION EFFECT

Posterior converging lines produced by joining cusp tips, cementocamel junction, contact areas of canine. 1° PM, 2° PM.




When mandibular canine move medially about 1 mm in lateral chewing function the buccal cusp of 1 premolar aid the canine due to graduation effect.

SMILE LINE




Ideal smile line allow the mandibular canines to pass freely during the incisive movements.

PRINCIPLES OF PROPORTION AND CENTRAL DOMINANCE




The width to length ratio (4:5) of the two maxillary central incisors is to provide maximum functional contact with the four mandibular incisors when the mandible move forward in incisive guidance.

MIDLINE




The midline of maxillary CI should be perpendicular to the incisal plane without which an even contact with the lower incisors is not possible in incisive function.

INCISAL EDGE POSITION




The incisal edge position of the maxillary lateral incisor should be approximately 1 mm apical to the incisal edges of the central incisors and canine to provide space for cusp tips of mandibular canine in protrusion.

AXIAL INCLINATION




From the central incisor to the canine, there should be a natural progressive increase in the mesial inclination of each subsequent anterior tooth. This allows compensation for the arch width difference between the maxillary and the mandibular teeth permitting the correct anterior coupling of the incisors.

MANDIBULAR ANTERIOR




The mandibular canine should be slightly longer than the mandibular incisors. This maximizes anterior guidance. The incisal embrasures should be minimized, creating a wider masticatory blade.

AXIAL CROWN CONTOUR



Cervical coronal contour should be symmetrical to apical contour. "Gull wing pattern".


MAXILLARY ANTERIOR



Mesial and distal marginal ridges - strengthen the tooth against off-axis loads. The prominent lingual lobe of the maxillary canine maximizes the canine guidance.

GOOD OCCLUSION


HARMONIZED ANTERIOR GUIDANCE



CANINE GUIDANCE **INCISAL GUIDANCE**

Proper anterior guidance result in proper posterior clearance which allows: Efficient sharp cusp form without interferences in function and physiologic flexure of mandible under masticatory load.


PROPER OVERJET AND OVERBITE



CANINE **INCISOR**

Proper overjet and overbite with proper axial inclination facilitates the guidance of the posterior teeth with the condyles in centric relationship.


STABLE CENTRIC RELATION CONTACTS



This help in maintaining total craniomandibular stability which is important to comfort, function and longevity of dental restoration.


Periodontal ligament
Mucosa
Lips
Tongue
Cheeks
Muscles
TMJ

Afferent proprioceptive stimuli



Brain

Effluent stimuli in the presence of GOOD OCCLUSION



Muscles of mastication

PROPER FUNCTION

Hence by applying the principles of bioesthetics the function of restorations can be enhanced.