

Int Poster J Dent Oral Med 2001, Vol 3 No 3, Poster 86

DNA-Image-Cytometry: Diagnostic aid in brush cytology of oral cancer.

Language: English

Authors: Torsten W. Remmerbach^a, Horst Weidenbach^b, Alexander Hemprich^a, Alfred Böcking^c

^aDepartment of Oral, Maxillofacial and Facial Plastic Surgery, University of Leipzig, Nürnberger Straße 57, D-04103 Leipzig, Germany.

^bInstitute of Pathology, University of Leipzig, Liebigstraße 26, D-04103 Leipzig, Germany.

^cInstitute of Cytopathology, Heinrich Heine University, Moorenstraße 5, D-40225 Düsseldorf.

Date/Event/Venue:

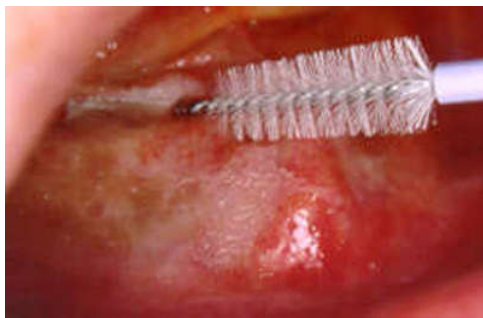March 7-10, 2001

30th Meeting of the AADR

Chicago, IL

Objective

The aim of this double blind and prospective study was to report on the diagnostic accuracy of conventional oral exfoliative cytology taken from white-spotted, ulcerated or other suspicious oral lesions in our clinic. In addition we checked DNA-image cytometry as an adjuvant diagnostic tool. Our hypothesis is that DNA-aneuploidy is a sensitive and specific marker for the early identification of tumor cells in oral brushings.



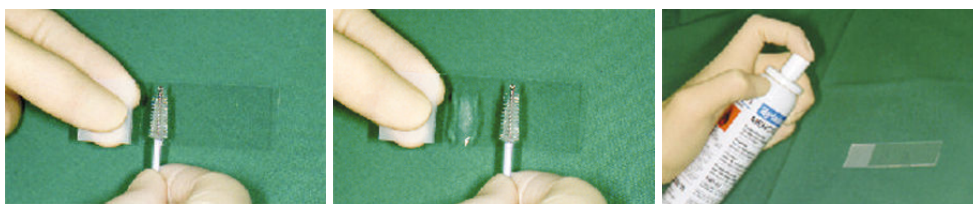
Cell Collector Cytobrush GT in situ.

Study Design

300 cytological diagnoses (including 60 patients with histologically proven cancer) obtained from macroscopically suspicious lesions of the oral mucosa were compared with histological and/or clinical follow-ups of the respective patients. Additionally nuclear DNA-contents were measured after Feulgen restaining using a TV image analysis system.

Clinical Procedure

At least four cytological smears were obtained from the suspicious or pathological area using a cytobrush cell collector (Cytobrush GT, Med-Scand Medical, Malmo, Sweden) [9].



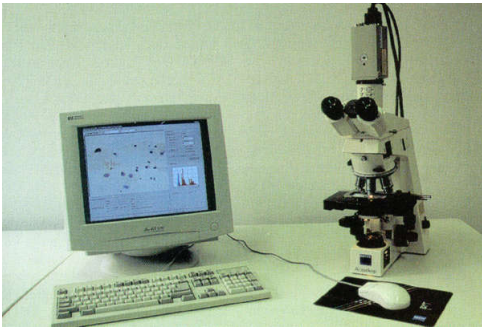
The cytobrush was rolled on the glass slide. The slide must be fixed immediately with Merckofix-spray (Merck, Darmstadt, Germany).

Staining an mode of interpretation

The slides were stained according to Papanicolaou [7]. The specimens were evaluated according to generally accepted diagnostic criteria [1,7] by an experienced cytopathologist. Additionally nuclear DNA-contents were measured after Feulgen restaining using a TV image analysis system [4].

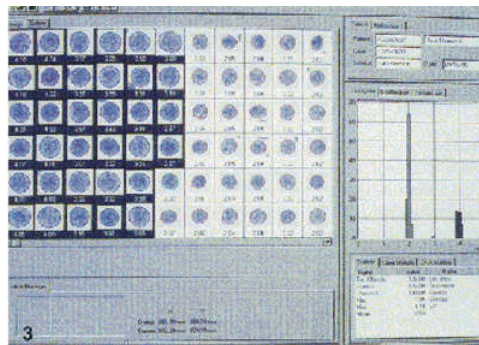
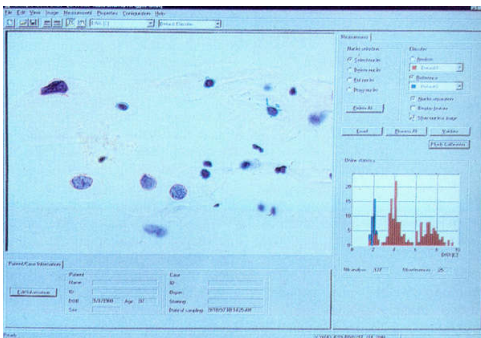
DNA-Measurements

The normal 2c reference value was established by measuring 30 cytologically normal squamous epithelial cells or lymphocytes in each slide as an internal reference (mean values of integrated optical densities (IOD)). CVs (=coefficient of variation) of reference cells were below 5%. If present, three hundred atypical epithelial or carcinoma cells per specimen were measured interactively at random. The performance of the system meets the standards of the European Society for Analytical Cellular Pathology (ESACP) task force on standardization of diagnostic DNA-image cytometry [2,5,6].

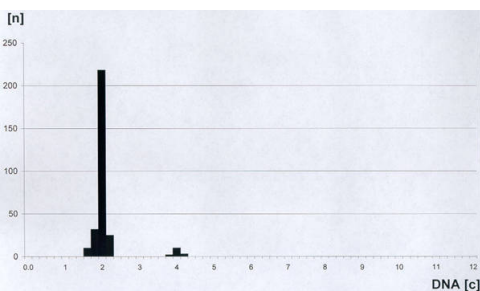


The AutoCyte QUIC-DNA-workstation (AutoCyte, Burlington N.C., USA) was used for the measurements. It consists of a conventional light microscope Axioplan 2, Zeiss, Germany).

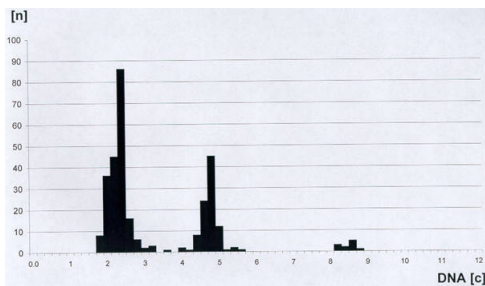
We assumed DNA-aneuploidy if (1) the DNA index of the stemline was $<0,90>1,10$ or $<1,80>2,20$ or $<3,60>4,40$ or (2) cells $>9c$ occurred (9c exceeding events [9cEE]) [3,8].



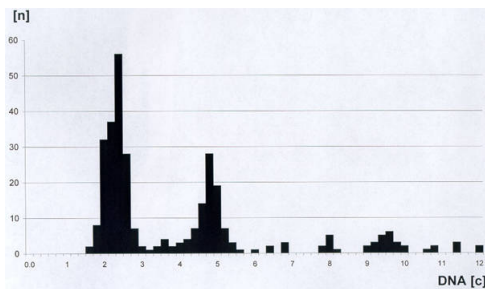
AutoCyte workstation: 2 Screen selection



DNA-histogram of a smear from a histologically proven hyperkeratosis without dysplasia, showing number of cells measured (n) and their corresponding DNA-content (c) and a (normal) diploid stemline at 2.0c.



DNA-histogram of a smear from a squamous cell carcinoma of the tongue. Abnormal stemlines at 2.3c and 4,8c can be detected as one aspect of DNA-aneuploidy.



DNA-histogram of a smear from a squamous cell carcinoma of the buccal mucosa. Different aspects of DNA-aneuploidy can be detected: abnormal stemlines at 2.4c, 4.8c and 29 cells greater 9c (9cEE).

Results

Sensitivity of our cytological diagnosis on oral smears for the detection of cancer cells was 95,0%, specificity 99,6%, positive predictive value 98,3% and negative predictive value 99,8%. On this basis the prevalence of DNA-aneuploidy in smears of oral squamous cell carcinomas in situ or invasive carcinomas was 96,6%. Sensitivity of DNA-aneuploidy in oral smears for the detection of cancer cells was 96,6%, specificity 100%, positive predictive value 100% and negative 99,2%. The combination of both techniques increased the sensitivity to 98,3%, specificity to 100%, positive predictive value to 100% and negative to 99,6%.

	Cytology	DNA-Cytometry	DNA-Cytometry
Sensitivity	95,0%	96,6%	98,3%
Specificity	99,6%	100%	100%
Positive Predictive Value	98,3%	100%	100%
Negative Predictive Value	99,8%	99,2%	99,6%

Conclusion

Smears from brushings of all visible oral lesions, if they are clinically considered as suspicious for cancer, are an easily practicable, cheap, non-invasive, painless, safe and accurate screening method for detection of oral precancerous lesions, carcinoma in situ or invasive squamous cell carcinoma in all stages. We conclude that DNA-image cytometry is a very sensitive and highly specific and objective adjuvant tool for the early identification of neoplastic epithelial cells in oral smears.

Bibliography

1. M. Bibbo, Comprehensive Cytopathology, WB Saunders Company, Philadelphia, 1991: 541-614.
2. A. Böcking, G. Haroske, A. Reith, F. Girod, P. Spieler, A.A. Gschwendtner, Fourth Updated ESACP Consensus Report on DNA Image Cytometry, Anal. Quant. Cytol. Histol. (2001), in process.
3. R. Chatelain, T. Schunck, E.M. Schindler, A.E. Schindler, A. Böcking, Diagnosis of prospective malignancy in koilocytic dysplasia of the cervix with DNA Cytometry, J. Reprod. Med. 34 (1989), 505-510.
4. K. Feulgen, H. Rossenbeck, Mikroskopisch-chemischer Nachweis einer Nucleinsäure vom Typus des Thymonucleinsäure und die darauf beruhende elektive Färbung von Zellkernen in mikroskopischen Präparaten. Hoppe Seyler Z. Physiol. Chem. 135 (1924), 203-248.
5. F. Giroud, G. Haroske, A. Reith, A. Böcking, 1997 ESACP consensus report on diagnostic DNA image cytometry. Part II: Specific recommendation for quality assurance. European Society for Analytical Cellular Pathology, Anal. Cell. Pathol. 17 (4) (1998), 89-200.
6. G. Haroske, W. Meyer, M. Oberholzer, A. Böcking, K.D. Kunze, Competence on demand in DNA image cytometry, Pathol. Res. Pract. 196 (5) (2000), 285-291.

7. L.G. Koss, Diagnostic Cytology and its histopathologic bases. 4th ed., Lippincott Company, Philadelphia, 1992:1082-1184.
8. H.W. Müller, A. Böcking, H. Auer, TV Cytometer CM1 for computer aided tumor diagnosis, in: Compendium on the computerized cytology and histology laboratory. Tutorials in Cytology. Edited by Wied L, Bartels PH, Rosenthal DL, Schenck U, Chicago, Illinois, USA 1994: 376-387.
9. G.R. Ogden, J.G. Cowpe, M. Green, Cytobrush and wooden Spatula for Oral Exfoliative Cytology. A comparison, Acta cytol. 36 (1992), 706-710.

This Poster was submitted by Dr. med. dent. Torsten W. Remmerbach.


Correspondence address:

Dr. med. dent. Torsten W. Remmerbach
 Department of Oral, Maxillofacial and Facial Plastic Surgery
 University of Leipzig
 Nürnberger Straße 57
 D-04103 Leipzig
 Germany

Poster Faksimile:

1372

AAADR
Chicago
2001



DNA-Image-Cytometry: Diagnostic aid in brush cytology of oral cancer.


T.W. Remmerbach^{a,*}, H. Weidenbach^b, A. Hemprich^a and A. Böcking^c

UNIVERSITÄT LEIPZIG

Department of Oral, Maxillofacial and Plastic Surgery
Head: Professor Dr. Dr. A. Hemprich

Objective

The aim of this double blind and prospective study was to report on the diagnostic accuracy of conventional oral exfoliative cytology taken from white-softened, ulcerated or other suspicious oral lesions in our clinic. In addition we checked DNA-image cytometry as an adjunct diagnostic tool. Our hypothesis is that DNA-aneuploidy is a sensitive and specific marker for the early identification of tumor cells in oral brushings.




Staining and mode of interpretation

The slides were stained according to Papanicolaou [7]. The specimens were evaluated according to generally accepted diagnostic criteria [1,7] by an experienced cytopathologist. Additionally nuclear DNA-contents were measured after Feulgen restaining using a TV image analysis system [4].


DNA-Measurements

The normal 2c reference value was established by measuring 30 cytologically normal squamous epithelial cells or lymphocytes in each slide as an internal reference (mean values of integrated optical densities (IOD)). CVs (coefficient of variation) of reference cells were below 5%. If present, three hundred atypical epithelial or carcinoma cells per specimen were measured interactively at random. The performance of the system meets the standards of the European Society for Analytical Cellular Pathology (ESACP) task force on standardization of diagnostic DNA-image cytometry [2,5,6].



The AutoCyte QUIC-DNA-workstation (AutoCyte, Burlington N.C., USA) was used for the measurements. It consists of a conventional light microscope, Axioptan 2, Zeiss, Germany.

We assumed DNA-aneuploidy if (1) the DNA index of the stemline was $>0.90 > 1.10$ or $< 1.00 > 2.20$ or $< 3.00 > 4.43$ or (2) cells $> 5c$ occurred [9c exceeding events (9cEE)] [3,8].



AutoCyte workstation: Screen selection

DNA-histogram of a smear from a histologically proven hyperkeratosis without dysplasia showing number of cells measured (n) and their corresponding DNA-content (c) and a (normal) diploid stemline at 2.0c.

DNA-histogram of a smear from a squamous cell carcinoma of the tongue. Abnormal stemlines at 2.3c and 4.8c can be detected as one aspect of DNA-aneuploidy.

DNA-histogram of a smear from a squamous cell carcinoma of the buccal mucosa. Different aspects of DNA-aneuploidy can be detected: abnormal stemlines at 2.4c, 4.8c and 2c cells greater 9c (9cEE).

We assumed DNA-aneuploidy if (1) the DNA index of the stemline was $>0.90 > 1.10$ or $< 1.00 > 2.20$ or $< 3.00 > 4.43$ or (2) cells $> 5c$ occurred [9c exceeding events (9cEE)] [3,8].

Results

Sensitivity of our cytological diagnosis on oral smears for the detection of cancer cells was 95.0%, specificity 99.6%, positive predictive value 98.3% and negative predictive value 99.6%. On this basis the prevalence of DNA-aneuploidy in smears of oral squamous cell carcinomas in situ or invasive carcinomas was 99.6%. Sensitivity of DNA-aneuploidy in oral smears for the detection of cancer cells was 96.6%, specificity 100%, positive predictive value 100% and negative 99.2%. The combination of both techniques increased the sensitivity to 99.3%, specificity to 100%, positive predictive value to 100% and negative to 99.6%.

	Cytology	DNA-Cytometry	Cytology & DNA-Cytometry
Sensitivity	95.0%	96.6%	99.3%
Specificity	99.6%	100%	100%
Positive Predictive Value	98.3%	100%	100%
Negative Predictive Value	99.2%	99.2%	99.6%

Conclusion

Smears from brushings of all visible oral lesions, if they are clinically considered as suspicious for cancer, are an easily practicable, cheap, non-invasive, painless, safe and accurate screening method for detection of oral precancerous lesions, carcinoma in situ or invasive squamous cell carcinoma in all stages. We conclude that DNA-image cytometry is a very sensitive and highly specific and objective adjunct tool for the early identification of neoplastic epithelial cells in oral smears.

1. M. Bibbo, Comprehensive Cytotechnology, WB Saunders Company, Philadelphia, 1991, 54-61A.

2. A. Böcking, G. Hasecke, A. Reith, P. Giro, P. Speiser, A.A. Gschwendtner, Fourth Updated ESACP Consensus Report on DNA Image Cytometry, Anal. Quant. Cytol. Histol. (2001), in press.

3. K. Christian, T. Böhm, E.M. Rühmke, A.C. Schneider, A. Böcking, Diagnosis of presneoplastic malignancy in keratocystic dysplasia of the cervix with DNA Cytometry, J. Reprod. Med. 34 (1999), 505-510.

4. H. Faulgen, H. Rosenbeck, Mikroskopisch-chemischer Nachweis einer Nucleinsäure vom Typus des Thyminocyclonucleosids und die darauf beruhende exaktive Färbung von Zellkernen in mikroskopischen Präparaten, Hoppe-Seyler Z. Physiol. Chem. 133 (1924), 223-248.

5. F. Göttsch, G. Hasecke, A. Reith, A. Böcking, 1997 ESACP consensus report on diagnostic DNA image cytometry, Part II: Specific recommendations for quality assurance, European Society for Analytical Cellular Pathology, Anal. Cell Pathol. 11 (4) (1998), 89-92.

6. G. Hasecke, W. Meyer, M. Oberholzer, A. Böcking, E.O. Kofler, Competence in demand in DNA image cytometry, Pathol. Res. Pract. 196 (5) (2000), 385-391.

7. L.G. Koss, Diagnostic Cytology and its histopathologic bases, 4th ed., Lippincott Company, Philadelphia, 1992:1082-1184.

8. H.W. Müller, A. Böcking, H. Auer, TV Cytometer CM1 for computer aided tumor diagnosis, in: Compendium on the computerized cytology and histology laboratory, Tutorials in Cytology, Edited by Wied L, Bartels PH, Rosenthal DL, Schenck U, Chicago, Illinois, USA 1994: 376-387.

9. G.R. Ogden, J.G. Cowpe, M. Green, Cytobrush and wooden Spatula for Oral Exfoliative Cytology. A comparison, Acta cytol. 36 (1992), 706-710.

* Department of Oral, Maxillofacial and Plastic Surgery, University of Leipzig, Nürnberger Straße 57, D-04103 Leipzig, Germany.

^b Institute of Pathology, University of Leipzig, Liebigstraße 26, D-04103 Leipzig, Germany.

^c Institute of Cytopathology, Heinrich Heine University, Moorenstraße 5, D-40225 Düsseldorf, Germany.

* Address reprint request to: Dr. Torsten W. Remmerbach,
 Tel.: +49 (0) 3419721100; Fax: +49 (0) 3419721109; email: remmi@medizin.uni-leipzig.de