

## Intraoral wound closure with tissue engineered mucosa - new perspectives for urethra reconstruction

**Language:** English

**Authors:** Ronald Schimming\*, Alexander Frankschmidt\*\*, Günter Lauer\*

Depts. of \*Oral and Maxillofacial Surgery and \*\*Urology, University Hospital of Freiburg, Germany

**Date/Event/Venue:**

November, 25-27th 1999

2<sup>nd</sup> Bio Valley Tissue Engineering Symposium

Freiburg im Breisgau, Germany

### Introduction

Reconstruction of the male urethra is required for a multitude of congenital anomalies, such as hypospadias and epispadias, as well for acquired lesions, such as stricture disease. Most of these patients require a free tissue graft to create a neourethra. Different sources of nongenital skin have been described. Initially, full-thickness skin grafts from hair-bearing sites provided a reasonable success rate. However, over time, complications such as strictures and balanitis xerotica obliterans have occurred. Other tissue sources have been used, including nonhair-bearing skin, ureter, tunica vaginalis and cultured urethral epithelium. All have had their limitations, which have restricted widespread use. More than 50 years after Humby, in 1992 Bürger et al. and Dessanti et al. reported their first clinical experience in urethral reconstruction with buccal mucosal grafts. Their excellent results stimulated a lot of different working groups and today urethra reconstruction with buccal mucosa grafts represents the standard procedure.

### Objective

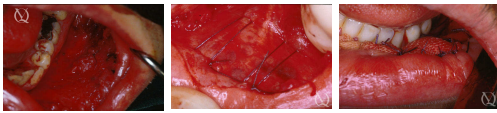
Buccal mucosa is a markedly resistant non keratinizing epithelium with a thin and highly vascularized lamina propria. The flexibility of the graft, easy trimming and good long term urethral results also emphasize its clinical rating. Whereas urethra reconstruction profits from buccal mucosa local sequelae at the donor site especially in case of multiple operated patients may negatively influence the clinical outcome. Submucosal scarring with contracture and subsequent web formation, limitation of movement of the mandible and injuries of the parotid duct with decreased parotid salivary flow may impact the success and require further surgery eg. to release mucosal tension. These possible complications limit the buccal mucosa graft size to 3x7 cm and can be of paramount importance in cases where multiple reconstruction procedures including buccal mucosa grafts have already been performed. In order to avoid these complications and to provide alternative therapy concepts for the patients mentioned above the application of tissue engineered oral mucosa for covering of donor side defects was discussed and a prospective study was initiated.

### Material and Methods

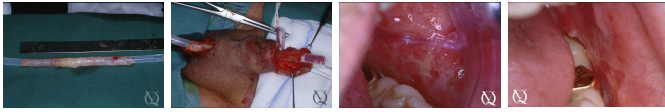
To tissue engineer mucosa grafts a biopsy from the hard palate, diameter size 4 mm, was taken approximately 4 weeks before the operation. In addition, 30 ml autogenous serum were produced out of a venous whole blood sample. The primary cultures were incubated in Dulbecco's modified Eagles Medium, Nutrient Factor F 12 containing the usual additives as well as autogenous serum. After a period of 3 weeks mucosa transplants subcultivation was performed to engineer a consisting of several layers of keratinocytes on a support foil. After thorough intraoperative blood coagulation, the cultured mucosa graft on the carrier foil was applied on the wound surface and fixed by single sutures (4/0 Vicryl). Additionally, the cultured mucosa graft was covered by an intraoral dressing for 8-10 days which was also fixed onto the wound surface by single suture loops. After the removal of the dressing no further special wound treatment was performed.

### Results

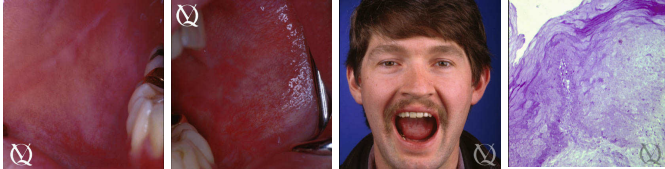Fig. 1-3 display the intraoperative situation intraorally. Fig.1: Situation after taking of mucosa graft, Fig. 2: Fixed cultured mucosa graft, Fig. 3: Intraoral wound dressing fixed with sutures. Fig. 5 and 6 show the use of oral mucosa graft for urethra reconstruction. Fig. 7 and 8: Clinical situation 10 days postoperatively, no signs of tissue shrinkage. Fig. 8-10: Clinical situation 3 months postoperatively without any signs of scars strictures and no limiting of mouth opening. Local oral mucosa and transplanted tissue engineered mucosa graft are clinically not distinguishable. A biopsy of the transplanted mucosa taken 3 months postoperatively shows histologically well differentiated stratified mucosa tissue. ( Fig.11)



Figures 1-3 (1<sup>st</sup> series)



Figures 4-7 (2<sup>nd</sup> series)



Figures 8-11 (3<sup>rd</sup> series)

## Discussion and Conclusions

Primary intraoral wound closure with tissue engineered mucosa is possible to cover defect sizes up to 11.0 x 3.5 cm. This new method provides better perspectives for both urethra reconstruction and reconstruction of intraoral tissue defects. Intraoral scars strictures are diminished. This is of special interest for the reconstruction of the functional unit oral cavity including soft tissue and cosmetic conditions (e.g. in case of prosthetic rehabilitation). In comparison to primary wound closure with local tissue or secondary healing this technique reduces postoperative pain and allows faster rehabilitation of the patients basing on a better wound healing process. Furthermore, better mobility of intraoral soft tissue structures is achieved. Tissue engineered mucosa grafts still require a considerable amount of preoperative work and lab preparations. At present this limits the application of the method to selected cases and treatment centers providing adequate facilities. Further developments in tissue engineering may reduce this disadvantage, e.g. when the mucosa layer can be engineered directly on carrier material. The use of collagen matrix may allow the engineering of complete mucosa - submucosa grafts as already described for skin layers.

## Bibliography

- Bürger RA, Müller SC, El-Damanhoury H, Tschakaloff A, Riedmiller H, Hohenfellner R: The buccal mucosal graft for urethral reconstruction: a preliminary report. *Journal of Urology* 1992, 147, p662-664.
- Dessanti A, Rigamonti W, Merulla V, Falchetti D, Caccia G: Autologous buccal mucosa graft for hypospadias repair: an initial report. *Journal of Urology* 1992, 147, p1083-1084.
- Lauer G: Autografting of feeder-cell free cultured gingival epithelium - Method and clinical application. *Journal of Cranio-Maxillofacial Surgery* 1994, 22, p18-22.

*This Poster was submitted on 04.02.00 by Dr. Dr. Ronald Schimming.*

## Correspondence address:

*Dr. Dr. Ronald Schimming*  
 Universitätsklinik Freiburg  
 Univ-Klinik und Poliklinik für MKG-Chirurgie  
 Hugstetter Str. 55  
 D-79106 Freiburg



**INTRAORAL WOUND CLOSURE WITH TISSUE ENGINEERED MUCOSA –  
NEW PERSPECTIVES FOR URETHRA RECONSTRUCTION**

<sup>1</sup>Ronald Schimming, <sup>2</sup>Alexander Frankenschmidt, <sup>3</sup>Günter Lauer  
Depts. of <sup>1</sup>Oral and Maxillofacial Surgery and <sup>2</sup>Urology, University Hospital of Freiburg, Germany



**Introduction:**

In urethra reconstruction, the forming of a new urethra from a free oral mucosa graft is an established surgical technique. The oral mucosa is taken simultaneously during the urethra correction procedure.

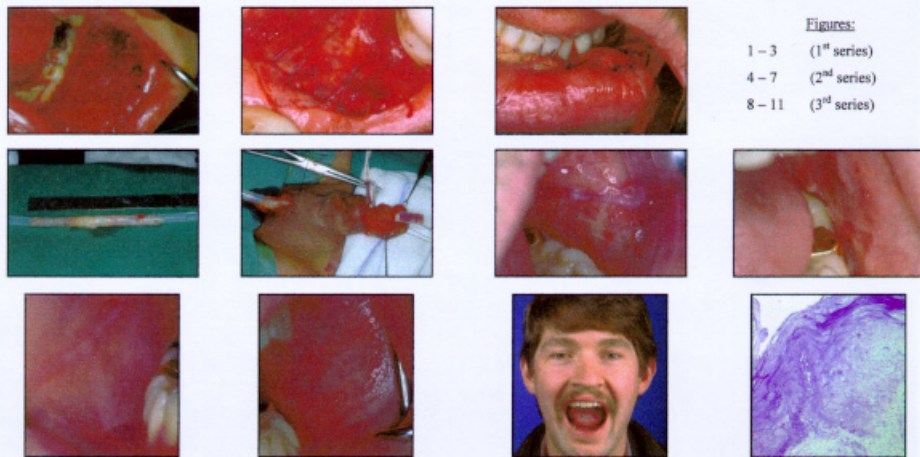
Depending on the size of graft required, the intraoral wound is closed primarily or left to secondary healing. The latter limits this technique leading to scars strictures which have a negative impact on the intraoral soft tissue condition. Therefore, in a pilot study tissue engineered mucosa was tested for covering intraoral defects in order to avoid drawbacks mentioned above.

**Material and Methods:**

To tissue engineer mucosa grafts a biopsy from the hard palate, diameter size 4 mm, was taken approximately 4 weeks before the operation. In addition, 30 ml autogenous serum were produced out of a venous whole blood sample. The primary cultures were incubated in Dulbecco's modified Eagles Medium, Nutrient Factor F 12 containing the usual additives as well as autogenous serum. After a period of 3 weeks mucosa transplants subcultivation was performed to engineer a consisting of several layers of keratinocytes on a support foil. After thorough intraoperative blood coagulation, the cultured mucosa graft on the carrier foil was applied on the wound surface and fixed by single sutures (4/0 Vicryl). Additionally, the cultured mucosa graft was covered by an intraoral dressing for 8-10 days which was also fixed onto the wound surface by single suture loops. After the removal of the dressing no further special wound treatment was performed.

**Results:**

Fig. 1-3 display the intraoperative situation intraorally. Fig. 1: Situation after taking of mucosa graft, Fig. 2: Fixed cultured mucosa graft, Fig. 3: Intraoral wound dressing fixed with sutures. Fig. 4 and 5 show the use of oral mucosa graft for urethra reconstruction (defatting of the graft and forming of a tube). Fig. 6: Clinical situation 10 days postoperatively after removing of wound dressing, minimal superficial scar formation. Fig. 7: Clinical situation 1 month postoperatively, no signs of tissue shrinkage. Fig. 8-10: Clinical situation 3 months postoperatively without any signs of scars strictures and no limiting of mouth opening. Local oral mucosa and transplanted tissue engineered mucosa graft are clinically not distinguishable. A biopsy of the transplanted mucosa taken 3 months postoperatively shows histologically well differentiated mucosa tissue. ( Fig.11)



**Figures:**

- 1 – 3 (1<sup>st</sup> series)
- 4 – 7 (2<sup>nd</sup> series)
- 8 – 11 (3<sup>rd</sup> series)

**Discussion:**

Primary intraoral wound closure with tissue engineered mucosa is possible to cover defect sizes up to 11.0 x 4.0 cm. This new method provides better perspectives for both urethra reconstruction and reconstruction of intraoral tissue defects. Intraoral scars strictures are diminished. This is of special interest for the reconstruction of the functional unit oral cavity including soft tissue and cosmetic conditions (e.g. in case of prosthetic rehabilitation). In comparison to primary wound closure with local tissue or secondary healing this technique reduces postoperative pain and allows faster rehabilitation of the patients basing on a better wound healing process. Furthermore, better mobility of intraoral soft tissue structures is achieved.

**References:**

Bürger, R.A., Müller, S.C., El-Damanhoury, H., Tschakaloff, A., Riedmiller, H., and Hohenfellner, R. The buccal mucosal graft for urethral reconstruction: a preliminary report. *J Urol* 147: 662, 1992  
 Dessanti, A., Rigamonti, W., Merulla, V., Falchetti, D., and Caccia, G. Autologous buccal mucosa graft for hypospadias repair: an initial report. *J Urol* 147: 1081, 1992  
 Lauer G: Autografting of feeder-cell free cultured gingival epithelium - Method and clinical application. *J Cranio Maxillofac Surg* 22: 18, 1994  
 Lauer G: Autoenous serum for culturing keratinocyte autografts. In: Phillis GO, von Versen R, Strone DM, Nather A: *Advances in Tissue Bankine* Vol 1: 1997, o 183