

Osteoblastoma of the Maxilla and Mandible: A Report of 2 Cases and Literature Review

Bo LIN¹, Zhi Gang CAI¹, Guang Yan YU¹, Ling Fei JIA¹

Osteoblastoma is a very rare primary bone tumour in the maxillofacial region. We report 2 cases of osteoblastoma in the maxilla and mandible, respectively. Histologically, the tumour is composed of small, irregular bony trabeculae and osteoids that are separated by a vascular stroma, and it should be considered in the differential diagnosis of an osteoblastic lesion. Total surgical resection is recommended. The absence of recurrence is largely due to adequate initial treatment.

Key words: osteoblastoma, bone tumors, mandible, maxilla, orthopaedic oncology

Osteoblastoma is a rare benign tumour, characterised by high vascularity and proliferation of osteoblasts. It accounts for approximately 1% of all primary bone tumors¹. It usually involves the vertebral column and the long, tubular bones of the lower extremities. This tumour rarely develops in the maxillofacial region. Two cases of osteoblastoma arising in the maxilla and mandible, respectively, were reported here with a literature review.

Case reports

Case 1

A 10-year-old boy complained of intermittent pain and swelling of the left side of his face in the preceding 18 months. Enucleation was performed 1.5 years ago and repeated six months later due to the recurrence of swelling, with a diagnosis of 'osteoblastoma' post-operative-

ly. The initial presentation or detailed surgical information was inadequate. Physical examination revealed an edentulous region from tooth 23 to 27, which was accompanied by a hard mass. Tenderness to palpation was noted. Radiographs showed that teeth 23 to 27 and the alveolar process were missing. A radiopaque mass was noted with an irregular border and an ill-defined margin, measuring 4 × 3 cm. Computerised tomography (CT) scans revealed an uneven, hyperdense, calcified mass in the left half of the maxillary alveolar bone and hard palate. A diagnosis of recurrence of osteoblastoma was established. The lesion was excised and submitted for histopathologic evaluation. The lesion was composed mostly of solid osteoid and granulation tissue, and was not enveloped and could not be separated from the surrounding normal bone tissue. The final histologic report confirmed the diagnosis of osteoblastoma. The patient had an uneventful postoperative course and there was no recurrence within the 1-year follow-up.

Case 2

A 26-year-old Chinese female presented with pain and swelling in the anterior mandible for 2 months. Her lower incisors bit uncomfortably and felt slightly painful at first, then increased in painfulness. She has been healthy previously and denied any history of trauma, smoking or medication. A physical examination revealed a large

¹ Department of Oral and Maxillofacial Surgery, Peking University School and Hospital of Stomatology, Beijing, P.R. China.

Corresponding author: Dr Zhi Gang CAI, Department of Oral and Maxillofacial Surgery, Peking University School and Hospital of Stomatology, #22 Zhongguancun Nandajie, Haidian District, Beijing 100081, P.R. China. Tel: 86-10-82195273; Fax: 86-10-62173402; Email: czg4209@126.com

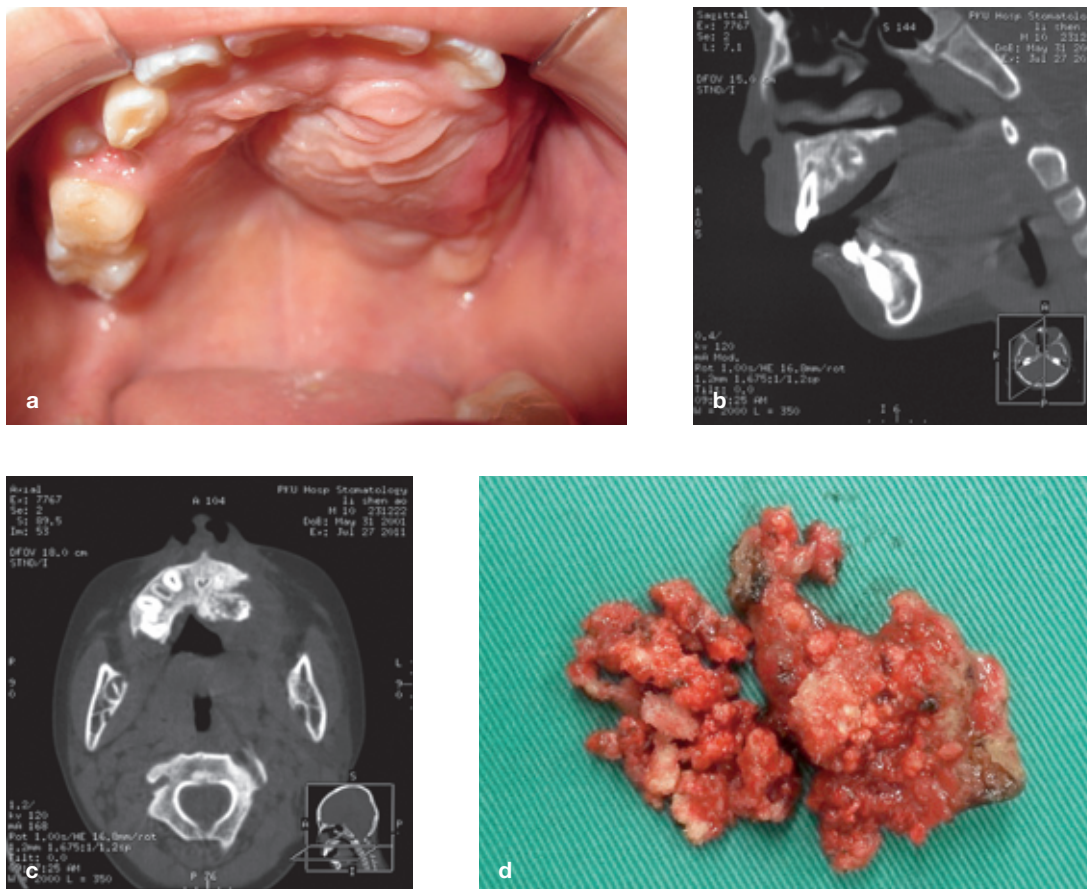
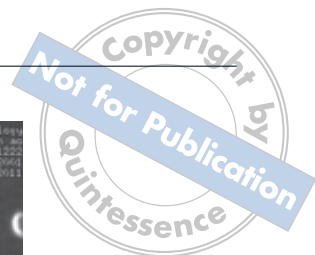

Fig 1 a) Preoperative clinical appearance showed the edentulous region of 23–27 was accompanied by a hard swelling measuring approximately 4 × 3 cm off the midpalatal suture; b and c) Preoperative CT image showed that uneven bone formation was noted on the left maxillary alveolar bone and hard palate; there were defects in the alveolar bone and the border was ill defined; d) Surgical specimen showed the lesion was composed mostly of solid osteoid and granulation tissue, fragile and grainy in cross-section.

swelling in the left anterior mandible with an ulcer measuring 0.5 × 0.5 cm² on the surface. It felt hard, had a clear surrounding rim and was painful when pressed. Pantomography and CT of the mandible revealed an expansile, mixed radiolucent and radiopaque lesion with a radiolucent rim in the anterior mandible. Her chest radiograph was normal and all laboratory values were within normal limits. A biopsy disclosed that the woven, bonelike tissues contained plump, scattered osteoblasts. Mitoses were rare and atypical figures were not found. A diagnosis of aggressive osteoblastoma was made. The patient received an operation of block segmental resection. During the operation, the lesion was rich in blood supply, brittle to touch, with granular surfaces. The final histologic report confirmed the diagnosis of osteoblastoma. The patient had an uneventful postoperative course, and at the 2-year follow-up there was no evidence of recurrence.

Discussion

Osteoblastoma accounts for only 1% of primary bone tumors; most are prevalent in the vertebrae, sacrum, long bones of the limbs, and small bones of the hands and feet. Fifteen percent occur in the cranial bones or mandible, with a 90% onset before age 30^{2,3}. The male-to-female ratio is 2:1. Its progression varies from months to 3 years. The common chief complaint is spontaneous, continuous, dull pain^{1,3-6}. Tenderness to palpation was noted; the effect of non-steroidal antiinflammatory drugs is inconclusive¹. Resorption of the jawbones could lead to loosening of the teeth. Endodontic treatment or the use of antibiotics is frequently encountered³.

A total of 82 cases, including our cases, of osteoblastomas occurring in the maxillofacial region in the recent decade have been reviewed. Overall, the age range in the reported cases was 7 to 78 years, with a slight pre-

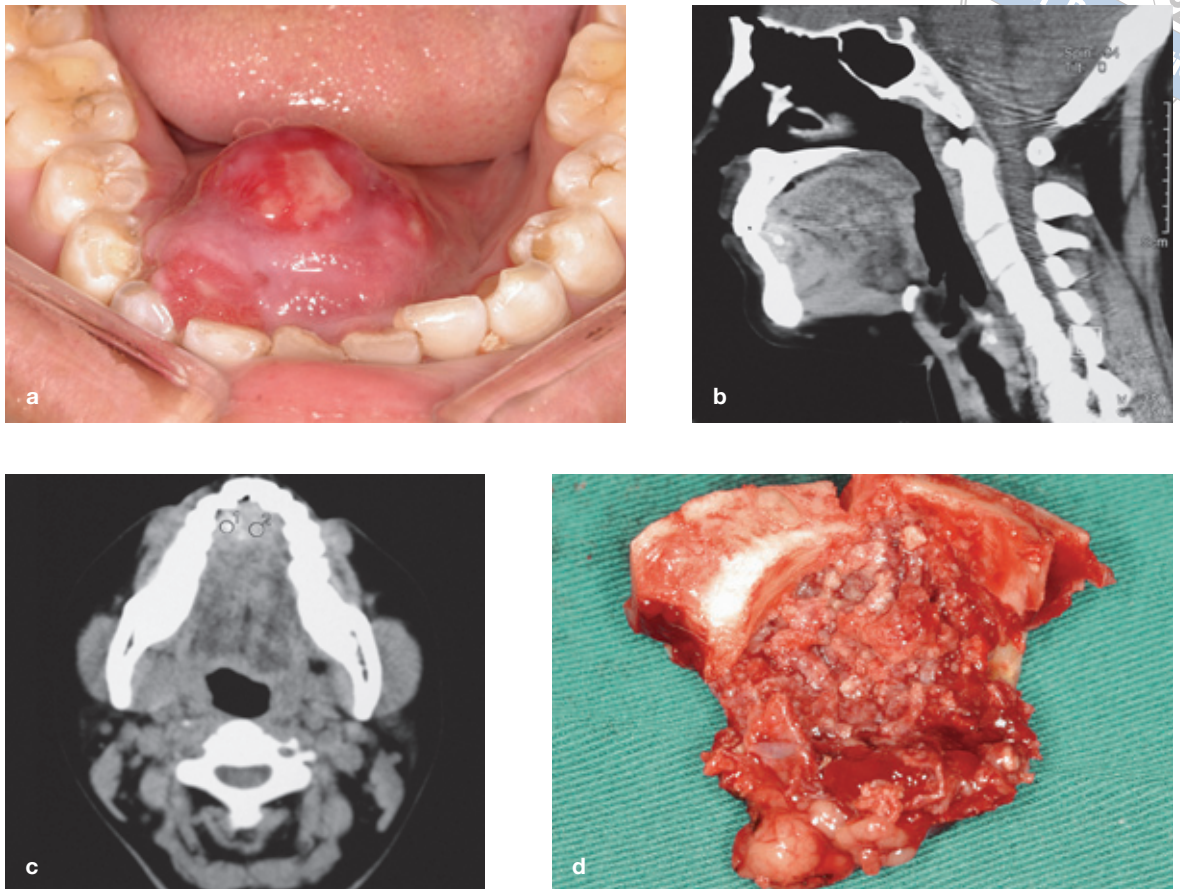


Fig 2 a) Preoperative clinical appearance showed a $3 \times 3 \times 2$ cm tumour was found lingual to 32 to 44 with a clear boundary and a poor range of motion, with 33 to 43 mobility II degrees; b, c) The bulk of the tumour manifested an even density, partial calcification, and an unclear boundary; the mandible was swollen toward the lingual; d) The surgical specimen showed a granular surface, brittle to the touch, and rich in blood supply.

dominance in male patients (66.5%) and in the mandible (58.7%) versus the maxilla. Asymptomatic swelling was identified in 18 cases; 46 complained of pain. Four cases were reported with root resorption. The follow-up period ranged from 6 months to 10 years, with 6 recurrences and 3 malignant changes being reported. Twenty-seven cases (33.8%) were radiopaque masses; 20 were low-density, cystic radiolucencies with inner calcification (25%); 12 were mixed radiopaque and radiolucent lesions (15.0%); and the rest did not report sufficient information.

Radiologic evaluation of the reported cases depended on the radiologic diagnostic technique available at the time of diagnosis⁴. The radiograph manifestations were a round or elliptical, substantive, well-defined lesion with a corticated border. Bone expansion and patchy or cloudy calcification was seen in unicystic and multicystic radiolucencies. Mature lesions were manifested

as central, high-density radiopacities with a radiolucent rim. Radiolucency may not be a feature of aggressive lesions, which show the characteristics of a malignant tumour, such as honeycombed, osteolytic destruction. The CT image is usually manifested as bony destruction and local calcification. The MRI findings of osteoblastoma are characterised by a hypointense or isointense mass on a T1-weighted image with homogenous or heterogeneous enhancement after the administration of gadolinium-diethylenetriamine pentaacetic acid and by a hypointense mass on a T2-weighted image. Compared with CT, the magnetic resonance imaging (MRI) has a lower diagnostic value, as its signals do not differentiate this tumour from other osteogenic lesions. In summary, the MRI has the advantage of showing the extent of the pathologic invasion, especially in determining the involvement of the adjacent soft tissues¹. Studies using technetium-99m scintigrams have shown an

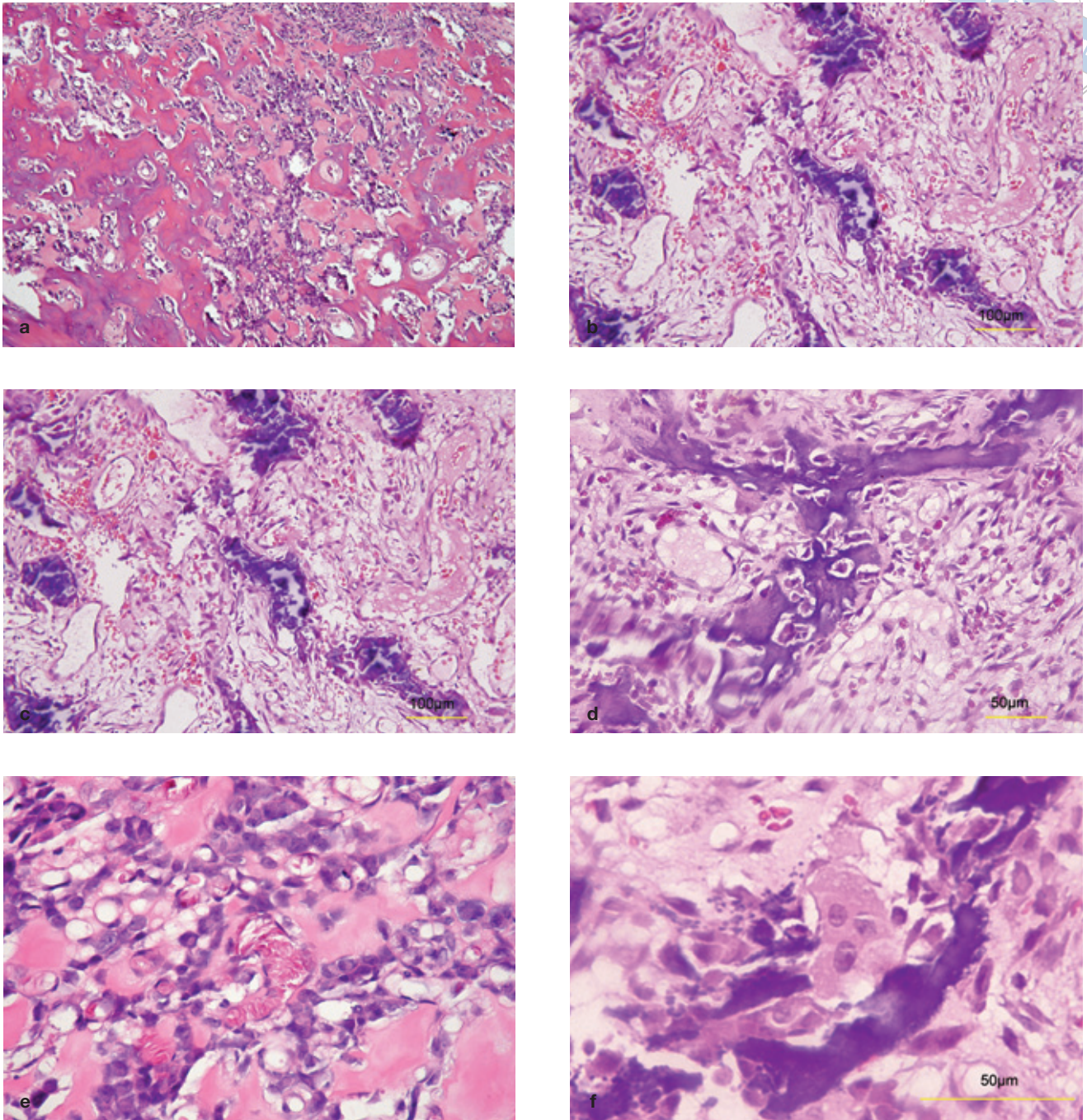
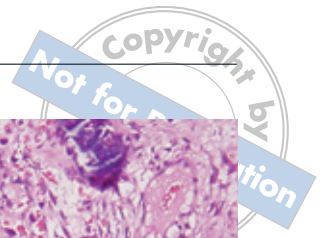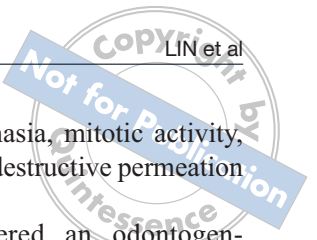


Fig 3 Fig 3 a, b) Histopathology showed a markedly well-vascularised fibrous connective tissue containing osteoid and bone trabeculae surfaced by numerous osteoblasts ($\times 100$); c, d) the tumour is composed of large osteoblast-like cells, frequently surrounded by clusters of osteoid substance. The intervening collagenous stroma contains osteoclast-like, multinucleated cells and loosely aggregated fibroblast-like cells. There was no evidence of cartilaginous differentiation ($\times 200$); e, f) the section shows bony trabeculae rimmed by osteoblasts. The fibrovascular stroma was associated with numerous osteoblasts, osteoid tissue, well-formed woven bone, and giant cells ($\times 400$). Figure a,c,e: Case 1; Figure b,d,f: Case 2.



increased uptake in the mass, while FDG-PET studies have revealed a high uptake by the tumour, despite its histologically benign features⁴.

The typical osteoblastoma appears to be composed of small irregular bony trabeculae and osteoids separated by a vascular stroma. The anastomosing trabecular bones are surrounded by numerous osteoblasts. The intertrabecular portion of the tumour contains variable numbers of fibroblasts and benign, multinucleated, osteoclast-like giant cells. The trabeculae of osteoid are usually delicate and lace-like and often have a basophilic staining pattern. These abundant, irregular spicules of mineralised bony tissue are rimmed by osteoblasts that exhibit no significant nuclear atypia or mitotic activity. Occasional osteoclastic giant cells are also scattered between the osteoid seams. The periphery of the lesion exhibits gradual merging of osteoid trabeculae with adjacent normal bone, and the lesions expanding into soft tissue usually show a peripheral rim of host-reactive bone that separates the tumour from the soft tissue. The rich vascularity of the fibrous stroma is responsible for the severe bleeding often observed during surgery^{1,4-6}.

The histopathologic differential diagnosis of osteoblastic lesions may include osteoid osteoma. The nidus of the osteoid osteoma consists of a highly vascularised, richly innervated fibrous stroma containing interconnected trabeculae of osteoid and woven bone lined by osteoblasts and osteoclasts. The distinction between them is primarily dependent on the size of the lesion. Classically, a lesion is considered osteoid osteoma when it is less than 2 cm in diameter and osteoblastoma when greater than 2 cm. Radiographically, osteoid osteoma typically produces a marked peripheral sclerosis in the bone adjacent to the lesion. Dull, aching pain with distinctive exacerbation at night is usually relieved by salicylates.

One of the significant lesions in the differential diagnosis of osteoblastoma is osteosarcoma. Swelling and pain are among the typical presenting signs and symptoms. Radiographically, an ill-defined, mixed radiopaque/radiolucent lesion is seen, and symmetrical widening of the periodontal ligament space affecting the teeth in the area of the tumour is characteristic. Histopathologically, osteosarcomas exhibit features that are typically more aggressive and destructive, and they are associated with a more compact pattern of cell arrangement between trabeculae. They form clusters of sheets without an intervening matrix, and they

have greater nuclear hyperchromasia, mitotic activity, nuclear to cytoplasmic ratio, and destructive permeation of the surrounding tissue.

Cementoblastoma is considered an odontogenic tumour similar to osteoblastoma. The difference between cementoblastoma and osteoblastoma depends on whether or not the lesion is fused to the root. Characteristically, the cementoblastoma appears as a radiopaque mass fused to one or more tooth roots, obliterating the root outline as well as the periodontal ligament space. Histopathologically, the cementoblastoma is characterised by interlacing trabeculae of mineralised tissue that resemble cellular cementum, having a more eosinophilic appearance compared to the characteristic basophilic trabeculae seen in osteoblastoma.

Although the clinical and radiographic features of ossifying fibroma may be similar to osteoblastoma, pain is not a usual feature in ossifying fibroma. Radiographically, fibrous dysplasia exhibits a poorly defined margin in contrast to the well-circumscribed appearance of osteoblastoma, and upon histologic evaluation, new bone formation is lamellar and lacks osteoblastic activity.

Some authors have recommended that, because of its benign fashion, osteoblastoma should be treated conservatively, such as by curettage or partial resection. In some cases, spontaneous regression took place after a biopsy⁷. Although osteoblastoma is regarded as benign, several cases of invasion, local recurrence, and malignant transformation have been reported. Because the recurrence rate after incomplete resection appears to be as high as 16% to 20%, the majority of the authors currently recommended total resection of the tumour. There is no role for adjuvant radiotherapy or chemotherapy, except in recurrent or surgically unresectable cases^{1,3,5,6}. Radiation may also induce malignant malformation of a benign tumour. In some reported cases, an angiogram showed moderate neovascularity supplied by branches of the external carotid artery; therefore, some authors advocated the efficacy of preoperative embolisation⁸. It promises a relatively good prognosis, though cases of local recurrence and malignant transformation have been reported^{1,5,6,9}.

Acknowledgements

The authors thank Dr Yang WANG for detailed surgical information.

References

1. Jones AC, Prihoda TJ, Kacher JE et al. Osteoblastoma of the maxilla and mandible: a report of 24 cases, review of the literature, and discussion of its relationship to osteoid osteoma of the jaws. *Oral Surg Oral Med Oral Pathol Oral Radiol Endod* 2006;102:639–650.
2. Arantes M, Resende M, Honavar M et al. Benign osteoblastoma of the sphenoid bone. *Skull Base* 2009;19:437–441.
3. Ribera MJ. Osteoblastoma in the anterior maxilla mimicking periapical pathosis of odontogenic origin. *J Endod* 1996;22:142–146.
4. Gordon SC, MacIntosh RB, Wesley RK. A review of osteoblastoma and case report of metachronous osteoblastoma and unicystic ameloblastoma. *Oral Surg Oral Med Oral Pathol Oral Radiol Endod* 2001;91:570–575.
5. Lypka MA, Goos RR, Yamashita DDR, Melrose R. Aggressive osteoblastoma of the mandible. *Int J Oral Maxillofac Surg* 2008;37:675–678.
6. Capodiferro S, Majorano E, Giardina C et al. Osteoblastoma of the mandible: clinicopathologic study of four cases and literature review. *Head Neck* 2005;27:616–621.
7. Eisenbud L, Kahn LB, Friedman E. Benign osteoblastoma of the mandible: fifteen year follow-up showing spontaneous regression after biopsy. *J Oral Maxillofac Surg* 1987;45:53–57.
8. Shimizu N, Sakata K, Yamamoto I. Benign osteoblastoma of the temporal bone: Case report and review of the literature. *Surg Neurol* 2006;66:534–538.
9. Berry M, Mankin H, Gebhardt M et al. Osteoblastoma: a 30-year study of 99 cases. *J Surg Oncol* 2008;98:179–183.

