

# Progress of Oral Sequelae During Head-Neck Radiotherapy

Hui Bin SUN<sup>1</sup>, Xue Jun GAO<sup>2</sup>, Jing DENG<sup>1</sup>, Ning Yi LI<sup>1</sup>, Hai Jun LU<sup>1</sup>

**Objective:** To evaluate xerostomia, mucositis and dental caries during head and neck radiotherapy.

**Methods:** Twenty patients with nasopharyngeal carcinoma were included. Oral examinations were conducted before radiotherapy, after dosage of 2000 cGy irradiation, immediately after the termination of radiotherapy, and 1 month and 6 months after termination of the radiotherapy. Oral hygiene instruction, effective oral care and dental intervention were performed during the treatment. Salivary flow rate was evaluated by modified Schirmer's test. Xerostomia, mucositis and dental caries status were evaluated based on oral examinations.

**Results:** Salivary flow rate decreased significantly after the first dosage of 2000 cGy, and was aggravated with the increase in irradiation dosage until the termination of radiotherapy. Xerostomia and mucositis were observed in parallel with the reduction of saliva flow rate, and were aggravated with the increase in irradiation dosage. Mucositis began to recover within 1 month after the termination of radiotherapy and fully recovered within 6 months after the termination of the radiotherapy. Six months after the termination of irradiation, new carious lesions were detected in two patients.

**Conclusion:** Oral sequelae developed during radiotherapy of the head and neck. Oral health instructions and effective intervention were essential before, during and after the radiotherapy.

**Key words:** xerostomia, mucositis, dental caries

Irradiation of the head and neck region is a common therapy for patients with nasopharyngeal carcinoma. However, the head and neck region is a complex area, where salivary glands locate and continuously secrete saliva to lubricate oral mucosa and maintain a balanced micro-environment. Damage to salivary glands reduces

salivary secretion and as a result, increases patients' susceptibility to various oral diseases dramatically<sup>1,2</sup>. Severe oral sequelae may force an interruption of the radiotherapy and result in tremendous impacts on a patient's quality of life<sup>3</sup>.

Common oral sequelae caused by radiation include xerostomia, mucositis and dental caries. A change in the predominant bacteria in dental plaque may be a reason for the high incidence of radiation caries. For example, *Lactobacillus* spp in dental plaque and saliva increases while *S. sanguinis* decreases after radiotherapy<sup>4</sup>. Reports on *S. mutans* were not consistent. Some reported that *S. mutans* increased after radiotherapy<sup>5-7</sup>, while others reported a slight increase, or no change<sup>8-10</sup>.

Various reports can be found on the epidemiology of oral sequelae after irradiation in the head and neck

1 Department of Stomatology, Affiliated Hospital of Medical College, Qingdao University, Qingdao, P.R. China.

2 Department of Cariology and Endodontology, Peking University School and Hospital of Stomatology, Beijing, P.R. China.

**Corresponding author:** Dr Xue Jun GAO, Department of Cariology and Endodontology, Peking University School and Hospital of Stomatology, #22 Zhongguancun Nandajie, Haidian District, Beijing 100081, P.R. China. Tel: 86-10-62179977 ext 5523; Fax: 86-10-62173402. E-mail: kqxjgao@bjmu.edu.cn



region, but few have focused on the progress and prognosis of oral sequelae. The aim of the present paper was to evaluate the development of oral sequelae after irradiation of the head and neck region.

## Materials and methods

### Subjects

Twenty patients pathologically diagnosed with nasopharyngeal carcinoma were included in the present study. The ages of patients were between 45 and 65 years (mean 57.6 years). The irradiation was performed with a 23EX linear accelerator (Varian Medical Systems, Palo Alto, CA, USA) with a total radiation dosage of 6000 cGy over 6 weeks (200 cGy per day and 5 days per week). Preauricular regions were in the fields of irradiation. All patients were receiving radiotherapy for the first time with no neuropsychoses, no systemic diseases and no diseases in oral mucosa or salivary glands. Patients were not taking antibiotics, hormones, antimycotic drugs or immunity preparations 2 weeks before radiotherapy. The present study was approved by the Ethics Committee of Peking University. Informed consent was obtained from each patient.

### Oral examination and oral care intervention

Baseline information was obtained, including dental caries, and periodontal and oral mucosal status. Carious teeth were restored in advance with resin composite. All metal crowns were removed. Tooth cleaning and individual oral health instruction were implemented. Typical instructions included dietary advice, restriction of cariogenic foods, professional tooth cleaning and using fluoride toothpaste. Daily oral rinses with 2.5% sodium bicarbonate and 0.05% NaF were prescribed from the start of irradiation until 1 month after termination of the irradiation.

Whenever positive findings in dental caries and oral mucosal and periodontal diseases were recognised, oral care interventions with corresponding measures would be implemented.

Oral examinations and plaque collections were performed at the following time points: before the irradiation, after a dosage of 2000 cGy, immediately after the termination of radiotherapy, and 1 month and 6 months after termination of the radiotherapy.

### Determination of saliva flow rate by modified Schirmer's test

Reduction of the saliva flow rate implies damage to the salivary glands. A modified Schirmer's test was used to determine the saliva flow rate<sup>11</sup>. In the test, one end of a filter paper strip (1 cm × 17 cm, trimmed from 3MM WHATMAN colour spectrum laminar analysis filter paper) was placed on the mouth floor for 5 minutes. The length of the filter paper strip fully infiltrated by saliva was measured. The salivary flow rate was quantified as mm/5 min. The test was carried out between 9 am and 12 pm. Smoking and eating were forbidden 2 hours before the test.

### Subjective index of xerostomia

According to a ranking standard of advanced-stage radiation reactions of the Radiation Therapy Oncology Group/European Organization for Research on Treatment of Cancer (RTOG/EORTC)<sup>12</sup>, xerostomia was characterised as slight (feeling of slight dry mouth but unable to eat rice without water), moderate (feeling of dry mouth demanding more drinking water, unable to eat rice without water) and heavy (feeling of severe dry mouth, relying on frequent water drinking to relieve the symptom, unable to eat biscuits at all).

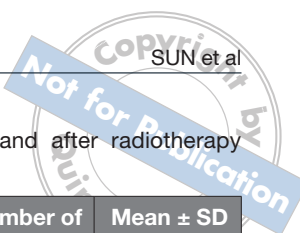
### Diagnostic criteria of mucositis

The severity of mucositis was characterized in four degrees, according to the clinical manifestation<sup>13</sup>:

- 0o: normal mucosa
- Io: mucosal congestion, red colour and dropsy
- IIo: red coloured mucosa, dropsy, punctate albuginea, slight pain
- IIIo: feeling of pain and burning, mucosal striping, ulcer, covered with fibrous exudation, intense pain
- IVo: atrophy of tongue papillae, mouth drying, large mucosal ulcer, intense pain, dysgeusia, unable to eat.

### Statistical analysis

Data before and after radiotherapy were analysed with ANOVA.  $P < 0.05$  was considered statistically significant. The software used for statistical analysis was SPSS 10.0.



## Results

Among the 20 patients, one was defined as a dropout because the follow-up was lost at 6 months after the termination of radiotherapy.

Table 1 shows the results of a modified Schirmer's test. A trend of decreasing salivary flow rate was demonstrated. Based on subjective feelings, xerostomia was determined as shown in Table 2. Mucositis was ranked according to mucosal damage as shown in Table 3. New carious lesions were found in two patients 6 months after the termination of radiotherapy.

## Discussion

In the present study, the saliva flow rate decreased immediately after 2000 cGy irradiation and further decreased with increasing dosage. Further reductions stopped after termination of the radiotherapy. The present results did not show a further effect of radiation on salivary secretion 6 months after the termination of the irradiation. On the other hand, no significant recovery of flow rate could be found even 6 months after termination of the radiotherapy. Xerostomia and mucositis developed with increasing dosage of irradiation. In more than half of the cases, xerostomia lasted 6 months after termination of the radiotherapy, suggesting that the salivary glands

**Table 1** Salivary flow rate before and after radiotherapy (modified Schirmer's test).

Examination time	Number of subjects	Mean $\pm$ SD (mm/5 min)
Pre-radiation	20	41.75 $\pm$ 9.32*
Received 2000 cGy radiation	20	25.70 $\pm$ 8.51 <sup>§</sup>
At termination of total 6000 cGy	20	20.30 $\pm$ 4.60 <sup>#</sup>
1 month post-radiation	20	17.65 $\pm$ 4.31
6 months post-radiation	19	16.15 $\pm$ 5.15

\* $P < 0.01$  vs all other groups; <sup>§</sup> $P < 0.01$  vs 1 month and 6 month post-radiation groups; <sup>#</sup> $P < 0.05$  vs 2000 cGy group

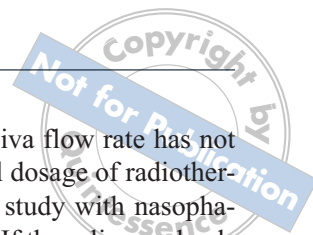
might be permanently damaged. However, mucositis started to recover immediately after termination of irradiation and a thorough recovery could be expected after 6 months. This implied that mucosal damages were mostly due to the direct effects of radiation on superficial mucosal cells. Oral mucositis was thought to be a process involved in the epithelium only. Radiation results in epithelial thinning as no new cells are developed and existing cells migrate to the surface and are exfoliated. More layers of cells are lost, which results in erythema and ulceration<sup>14</sup>.

**Table 2** Cases of xerostomia after irradiation.

	Without syndrome	Slight xerostomia	Moderate xerostomia	Heavy xerostomia	Total cases
Pre-radiation	20	0	0	0	20
Received 2000 cGy radiation	0	10	8	2	20
At termination of total 6000 cGy	0	4	8	8	20
1 month post-radiation	0	2	6	12	20
6 months post-radiation	0	2	5	12	19

**Table 3** Cases of mucositis before and after radiotherapy.

	0o	1o	2o	3o	4o	Total cases
Pre-radiation	20	0	0	0	0	20
Received 2000 cGy radiation	0	12	3	3	2	20
At termination of total 6000 cGy	0	1	2	5	12	20
1 month post-radiation	7	10	3	0	0	20
6 months post-radiation	19	0	0	0	0	19



### *Mucositis was eliminated soon after radiotherapy*

This study demonstrated that mucositis was a short-term but inevitable condition caused by irradiation. The damaged mucosal epithelium could be restored in a fairly short period if there was no secondary infection. From the clinical findings, mucositis occurred in two stages during radiotherapy. The first stage occurred during the process of radiotherapy: mucositis occurred and was aggravated with increasing irradiation dosage<sup>15</sup>. Clinical symptoms included pain, burning sensation, and pain while eating and swallowing. The secondary stage occurred during the recovery period after radiotherapy: the damaged cells started to repair, and symptoms disappeared soon after termination of the radiotherapy<sup>16</sup>. It is essential to give effective means like lubricant and mouth rinse throughout the irradiation period to reduce symptoms and prevent further complications. A daily rinse with 2.5% sodium bicarbonate is useful in relieving mucosal pain and discomfort, and can maintain moisture in the lips and oral cavity<sup>3</sup>.

### *Xerostomia persisted after radiotherapy*

Xerostomia, the most frequent complication of head and neck radiotherapy, is due to reduction of saliva secretion caused by radiation damage to the salivary glands. The damage may not recover in a short period of time, so the symptom of xerostomia may last long after the radiotherapy. An additional complication caused by saliva reduction was rampant dental caries, as saliva secretion was reduced soon after the beginning of the irradiation. Primary prevention of dental caries should start with radiotherapy.

In a detailed observation, the present study chose five time points, before and after radiotherapy, to obtain information about the damage process. The results showed that when patients received 2000 cGy irradiation, all developed xerostomia to various degrees. A previous study showed that in patients who received 1 week of radiotherapy (1000 cGy total), the saliva flow rate decreased nearly 50% and further decreased 95% after a 6000 to 7000 cGy dosage<sup>17</sup>. The severity of salivary gland damage mainly depends on the dosage of radiotherapy and volume of the salivary gland exposed in the irradiated region. The radiation sensitivity of serous alveoli is higher than mucous alveoli, therefore parotid glands are the most susceptible among salivary glands<sup>18,19</sup>. Saliva production is affected significantly by radiation, but with doses < 25 to 30 Gy, recovery is substantial and returns to pre-treatment levels 2 years after radiotherapy<sup>20</sup>. If the dosage is above 4000 cGy

and directly on the glands, the saliva flow rate has not been shown to recover<sup>21</sup>. The total dosage of radiotherapy in the patients of the present study with nasopharyngeal carcinoma was 6000 cGy. If the salivary glands are exposed directly to this dosage, permanent damage may occur. In view of clinical management, careful planning and maximal protection of parotid glands from irradiation is essential to reducing damage to salivary function.

Irradiation results in a reduction of saliva flow rate, which undermines the balance of oral micro-ecology. Consequently, caries risk increases significantly. The low caries incidence in the present study was probably due to three reasons. First, oral hygiene instruction and timely oral care intervention was implemented. Second, patients understood the means of prevention and their compliance was adequate. Third, the period of the present study was only 6 months.

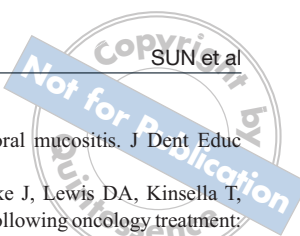
In summary, mucositis was a reversible consequence of radiotherapy, while xerostomia and hyposalivation were not. Mucositis and xerostomia appeared to be inevitable and dental caries preventable during radiotherapy. A combination of enhancing radiotherapy safeguards, oral health instruction, effective oral care and timely dental intervention may be essential to decreasing oral sequelae and preventing radiation caries.

### **Acknowledgements**

This study was supported by the following grants: 2007BA118B01 from 115-National Key Technologies R&D Programme, the Ministry of Science and Technology of China; 0050001109 from Special Fund for Doctorate Training, Ministry of Education, China; and 30870042 from National Natural Science Foundation of China.

### **References**

1. Lockhart PB, Clark J. Pretherapy dental status of patients with malignant conditions of the head and neck. *Oral Surg Oral Med Oral Pathol* 1994;77:236-241.
2. Wang WC, Chen YK, Lin LM. Oral care experiences with 181 nasopharyngeal carcinoma patients receiving radiotherapy in a Taiwanese hospital. *Auris Nasus Larynx* 2008;35:230-234.
3. Vissink A, Burlage FR, Spijkervet FK, Jansma J, Coppes RP. Prevention and treatment of the consequences of head and neck radiotherapy. *Crit Rev Oral Biol Med* 2003;14:213-225.
4. Tong HC, Gao XJ, Dong XZ. Non-mutans streptococci in patients receiving radiotherapy in the head and neck area. *Caries Res* 2003;37:261-266.
5. Schwarz E, Chiu GK, Leung WK. Oral health status of southern Chinese following head and neck irradiation therapy for nasopharyngeal carcinoma. *J Dent* 1999;27:21-28.



6. Meng L, Liu J, Peng B, Fan M, Nie M, Chen Z et al. The persistence of *S. mutans* in nasopharyngeal carcinoma patients after radiotherapy. *Caries Res* 2005;39:484-489.
7. Keene HJ, Fleming TJ. Prevalence of caries-associated microflora after radiotherapy in patients with cancer of the head and neck. *Oral Surg Oral Med Oral Pathol* 1987;64:421-426.
8. Almståhl A, Wikström M. Oral microflora in subjects with reduced salivary secretion. *J Dent Res* 1999;78:1410-1416.
9. Eliasson L, Carlén A, Almståhl A, Wikström M, Lingström P. Dental plaque pH and micro-organisms during hyposalivation. *J Dent Res* 2006;85:334-338.
10. Epstein JB, Chin EA, Jacobson JJ, Rishiraj B, Le N. The relationships among fluoride, cariogenic oral flora, and salivary flow rate during radiation therapy. *Oral Surg Oral Med Oral Pathol Oral Radiol Endod* 1998;86:286-292.
11. Lopez-Jornet P, Camacho-Alonso F, Bermejo-Fenoll A. A simple test for salivary gland hypofunction using Oral Schimer's test. *J Oral Pathol Med* 2006;35:244-248.
12. Meirovitz A, Murdoch-Kinch CA, Schipper M, Pan C, Eisbruch A. Grading xerostomia by physicians or by patients after intensity-modulated radiotherapy of head-and-neck cancer. *Int J Radiat Oncol Biol Phys* 2006;66:445-453.
13. Blijlevens NM. Implications of treatment-induced mucosal barrier injury. *Curr Opin Oncol* 2005;17:605-610.
14. Redding SW. Cancer therapy-related oral mucositis. *J Dent Educ* 2005;69:919-929.
15. Shaw MJ, Kumar ND, Duggal M, Fiske J, Lewis DA, Kinsella T, Nisbet T. Oral management of patients following oncology treatment: literature review. *Br J Oral Maxillofac Surg* 2000;38:519-524.
16. Scully C, Epstein JB. Oral health care for the cancer patient. *Eur J Cancer B Oral Oncol* 1996;32B:281-292.
17. Jacob RF. Management of xerostomia in the irradiated patient. *Clin Plastic Surg* 1993;20:507-516.
18. Henriksson R, Fröjd O, Gustafsson H, Johansson S, Yi-Qing C, Franzén L, Bjermer L. Increase in mast cells and hyaluronic acid correlates to radiation induced damage and loss of serous acinar cells in salivary glands: the parotid and submandibular glands differ in radiation sensitivity. *Br J Cancer* 1994;69:320-326.
19. Ying M, Wu VW, Kwong DL. Comparison of sonographic appearance of normal and postradiotherapy parotid glands: a preliminary study. *Ultrasound Med Biol* 2007;33:1244-1250.
20. Li Y, Taylor JM, Ten Haken RK, Eisbruch A. The impact of dose on parotid salivary recovery in head and neck cancer patients treated with radiation therapy. *Int J Radiat Oncol Biol Phys* 2007;67:660-669.
21. Liu RP, Fleming TJ, Toth BB, Keene HJ. Saliva flow rates in patients with head and neck cancer 0.5 to 25 years after radiotherapy. *Oral Surg Oral Med Oral Pathol* 1990;70:724-729.