

# Orthodontic Treatment of an Adult Maxillomandibular Protrusion Case with Impacted Mandibular Second Molars Using the Physiologic Anchorage Spee-wire System: a Case Report

Huan Huan CHEN<sup>1,2</sup>, Gui CHEN<sup>1,2</sup>, Guang Yao FENG<sup>2,3</sup>, Xiu Jing WANG<sup>2,3</sup>, Tian Min XU<sup>1,2</sup>, Hong SU<sup>2,3</sup>

*Impaction of mandibular second molars should be resolved as soon as possible once diagnosed, since it may lead to many functional, periodontal, hygienic and endodontic problems. Treatment options for impacted second molars include orthodontic-assisted eruption following surgical exposure, surgical uprighting and, in some cases, surgical extraction with possible subsequent implant placement if the tooth is deemed non-restorable or the patient prefers an implant restoration. This case report describes the orthodontic treatment of a 21-year-old woman with maxillomandibular protrusion and impacted bilateral mandibular second molars. The Physiologic Anchorage Spee-wire System (PASS) was adopted due to its innovative strategy of physiological anchorage control and unique design involving the multilevel low-friction (MLF) bracket and cross buccal tube (XBT). After 22 months of treatment, a well-aligned dentition, a normal functional occlusion and a harmonious facial profile were obtained, and impaction of the bilateral mandibular second molars was finally resolved. This case report demonstrates a simple and efficient solution to dental impaction. The PASS technique is superior to other preadjusted straight wire appliances in the treatment of maxillomandibular protrusion cases without auxiliary anchorage devices, and the mandibular buccal tube involved in the PASS technique can assist in uprighting the impacted mandibular second molars with NiTi round wire and minimising oral discomfort for the patient.*

**Keywords:** anchorage, maxillomandibular protrusion, molar impaction, physiological anchorage, Spee-wire system

*Chin J Dent Res* 2024;27(4):333–343; doi: 10.3290/j.cjdr.b5860297

1 Department of Orthodontics, Cranial-Facial Growth and Development Center, Peking University School and Hospital of Stomatology, Beijing, P.R. China.

2 National Center of Stomatology & National Clinical Research Center for Oral Diseases & National Engineering Research Center of Oral Biomaterials and Digital Medical Devices & Beijing Key Laboratory for Digital Stomatology & Research Center of Engineering and Technology for Computerized Dentistry Ministry of Health, Beijing, P.R. China.

3 First Clinical Division, Peking University School and Hospital of Stomatology, Beijing, P.R. China.

**Corresponding author:** Dr Hong SU, No. 37A Xishiku Street, Xicheng District, Beijing 100034, P.R. China. Tel: 86-10-82195737. Email: suhong0309@qq.com

The work was supported by the National Natural Science Foundation of China (no. 82001080), National Clinical Key Discipline Construction Project (PKUSSNKT-T202102) and National Programme for Multidisciplinary Cooperative Treatment on Major Diseases (PKUSSNMP-201902).

Tooth impaction is defined as the cessation of eruption or failure of teeth to erupt into the normal functional position caused by physical barriers in the eruption path.<sup>1</sup> Impaction of permanent second molars is relatively rare and its prevalence is often expressed as the percentage of all retained teeth in a group of patients,<sup>2</sup> which lies between 0.06% and 0.3%, and the prevalence rate is increasing gradually.<sup>3</sup> However, despite the fact that impaction is rarely seen in clinical practice, there are many functional, periodontal, hygienic and endodontic reasons that justify the need for treatment of impacted mandibular molars.<sup>4</sup> For example, oral hygiene in the area surrounding the impacted teeth is usually poor, which can cause caries and periodontal disease. Furthermore, undiagnosed second molar impaction may

initiate distal root resorption of the first molars, causing irreversible damage.<sup>5,6</sup>

The treatment of impacted teeth is very challenging for both the orthodontist and oral surgeon due to the limited access and complexity of the mechanics that needs to be applied.<sup>7</sup> Treatment options depend on multiple factors, such as the degree of tooth inclination, the existence of third molars and the desired type of movement in 3D directions.<sup>8</sup> In contrast to vertically impacted molars that may be associated with ankylosis or other factors that prevent eruption, mesially inclined or horizontally impacted mandibular second molars usually have great eruption potential, since the impaction is often due to the lack of space or abnormal eruption path.<sup>9</sup> Methods for managing impacted or tilted mandibular molars include surgical extraction with or without transplantation of the third molar into the extraction site, surgical uprighting and orthodontic repositioning. Further use of miniscrew as a temporary anchorage device (TAD) in the uprighting of mesially inclined mandibular molars may also be considered.<sup>10</sup> Among the above-mentioned methods for resolving molar impaction, the advantages of orthodontically uprighting impacted molars are functional, periodontal and restorative, showing the most promising efficacy.<sup>11</sup>

In addition to having impacted bilateral mandibular second molars, patients with tooth impaction usually display noticeable maxillomandibular protrusion. This is characterised by proclined anterior teeth and protrusive lips.<sup>12</sup> Most of these patients seek orthodontic treatment to improve their dental and profile aesthetics, and maximum anchorage is often required.<sup>13</sup> To attain better treatment outcomes, miniscrews and headgear are frequently utilised for anchorage reinforcement.<sup>14</sup> However, the introduction of the physiological anchorage Spee-wire system (PASS) provides orthodontists with an additional, simplified solution that can reduce the reliance on miniscrew anchorage significantly.<sup>15</sup> The advantages of the PASS to treat maxillomandibular protrusion include the fact that the cross buccal tube (XBT) can be used to prevent molar forward tipping following premolar extraction, and that the multilevel low-friction (MLF) bracket can be employed to facilitate the alignment of anterior teeth.

This case report describes the treatment of a 21-year-old woman with impacted bilateral mandibular second molars and mild maxillomandibular protrusion. The PASS appliance was applied following the extraction of four first premolars and three third molars.

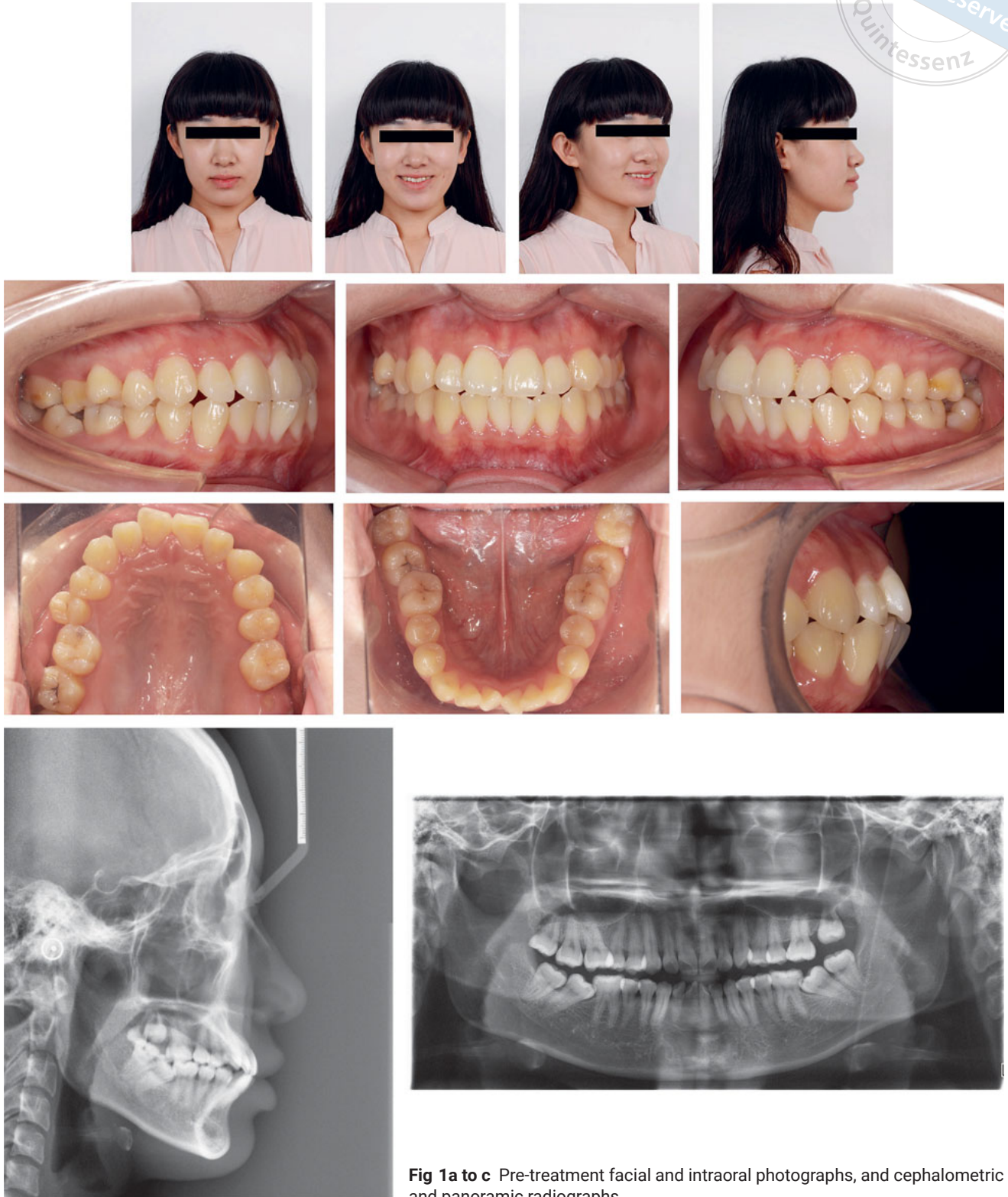## Case report

### *Diagnosis and aetiology*

A 21-year-old woman presented for orthodontic treatment in September 2015 with the chief concerns of occlusal disorder and lip protrusion. Her medical history showed no contraindication for orthodontic treatment.

The pretreatment facial and occlusal photographs showed an asymmetrical midline and chin, moderate maxillomandibular crowding, crossbite of the left anterior teeth, scissor bite involving the right second premolars, early loss of the maxillary left second molar, and impaction of the bilateral mandibular second molars (Fig 1). The mandibular dental midline was deviated 3.0 mm to the left and the maxillary midline was deviated 1.0 mm to the left, and the chin deviated 4.0 mm to the left of the facial midline. The dental casts showed an Angle Class III occlusion on each side with apparent crowding. Horizontal overlap was 2.0 mm, and vertical overlap was shallow (Fig S1, provided on request). The cephalometric analysis (Table 1) showed that the patient had a maxillomandibular protrusive profile relative to the cranial base, and the mandible was more protrusive than the maxilla. The impacted bilateral mandibular second molars were shown to have penetrated the oral mucosa in the intraoral photographs, but showed a severe lack of eruption potential on the panoramic radiograph (Fig 1). Clinical examination of the temporomandibular joint revealed that upon opening the mouth, the patient exhibited a single, audible click, deviation to the left during the opening motion, and a maximum degree of opening of 35 mm, and denied experiencing tenderness and restricted or limited arch movement. The panoramic radiograph demonstrated that the patient had four third molars and asymmetric bilateral joints. Her left condyle was flattened, and the left ascending ramus was shorter than the right. Although there is no definite association between the occlusal disorder caused by impaction of the second molars and temporomandibular disorder,<sup>16</sup> it is important to pay attention to dysfunction of the masticatory musculature.<sup>17</sup>

After analysis of the facial and occlusal photographs, dental casts and cephalometric and panoramic radiographs, the patient's problems were represented as an Angle Class III malocclusion with impaction of the bilateral mandibular second molars, maxillomandibular protrusion, early loss of the maxillary left second molar, and a deviated midline.



**Fig 1a to c** Pre-treatment facial and intraoral photographs, and cephalometric and panoramic radiographs.



**Table 1** Cephalometric measurements at pre-treatment and post-treatment.

Measurement	Initial value	Final value	Norm	Standard deviation
SNA, degrees	82.2	82.2	81.2	3.5
SNB, degrees	83.3	83.6	79.2	3.2
ANB, degrees	-1.1	-1.3	2.1	1.5
SN-GoGn, degrees	28.9	28	32.8	5.3
FH-GoGn, degrees	24.8	28.5	25.4	5.3
Y axis, degrees	69.5	68.9	66.3	7.1
U1-SN, degrees	115.1	108.7	105.7	6.3
U1-NA, degrees	32.9	26.5	22.8	5.7
U1-NA, mm	11.8	7.8	3.5	6.5
U1-L1, degrees	111.5	134.9	124.2	8.2
L1-NB, degrees	36.7	20	30.5	5.8
L1-NB, mm	7.9	2.9	6.7	2.1
L1-MP, degrees	104.4	88.4	93.9	6.2
UL-EP, mm	-3.7	-6.5	-1.4	1.9
LL-EP, mm	0.8	-3.9	0.6	1.9
L7-MP, degrees	62.0	95.0	NA	NA

NA, not applicable.

*Treatment*

**Treatment objectives**

The treatment objectives were to resolve crowding and impaction of the bilateral mandibular second molars, improve the maxillomandibular protrusive profile, replace the early lost maxillary left second molar with the third molar, relieve the crossbite of the left anterior teeth and the scissor bite involving the right second premolars, achieve optimal horizontal and vertical overlap with a Class I relationship, correct the midline and chin asymmetry as far as possible without the need for surgery, and maintain a stable occlusion in the long term.

**Treatment options**

The following treatment options were presented to the patient and her parents:

1. Comprehensive orthodontic treatment: To resolve the dental crowding, maxillomandibular protrusion, early loss of the maxillary left second molar and molar impaction, extraction of the four first premolars and three third molars (maxillary right and mandibular left and right) was proposed. The dental midline could be corrected, but there was a risk that the chin symmetry might not change significantly without orthognathic surgery. The PASS appliance with no auxiliary anchorage and a conventional fixed appliance with TADs, such as miniscrews, were introduced to the patient separately. In the hope of achieving a better facial profile, aligning the teeth, requiring minimal surgical procedures and experiencing

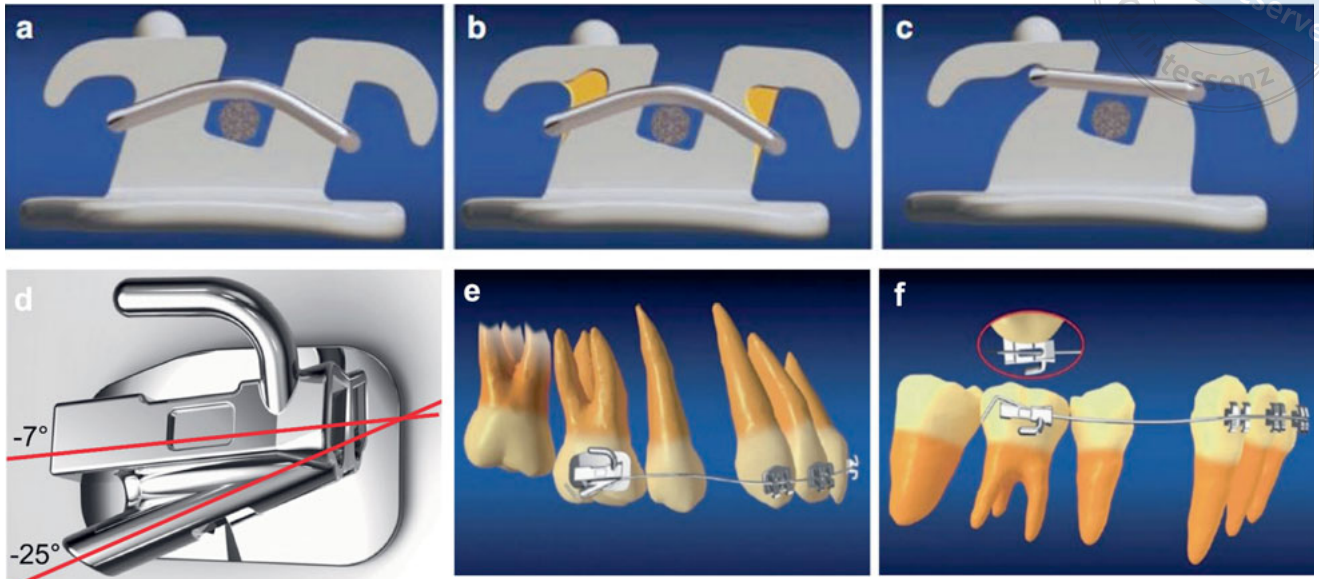
greater comfort during treatment, the patient opted for the PASS appliance for correction.

2. Local orthodontic treatment: This would simply involve extraction of the bilateral mandibular third molars and uprighting of the bilateral impacted second molars with local orthodontic intervention. The patient declined this option.

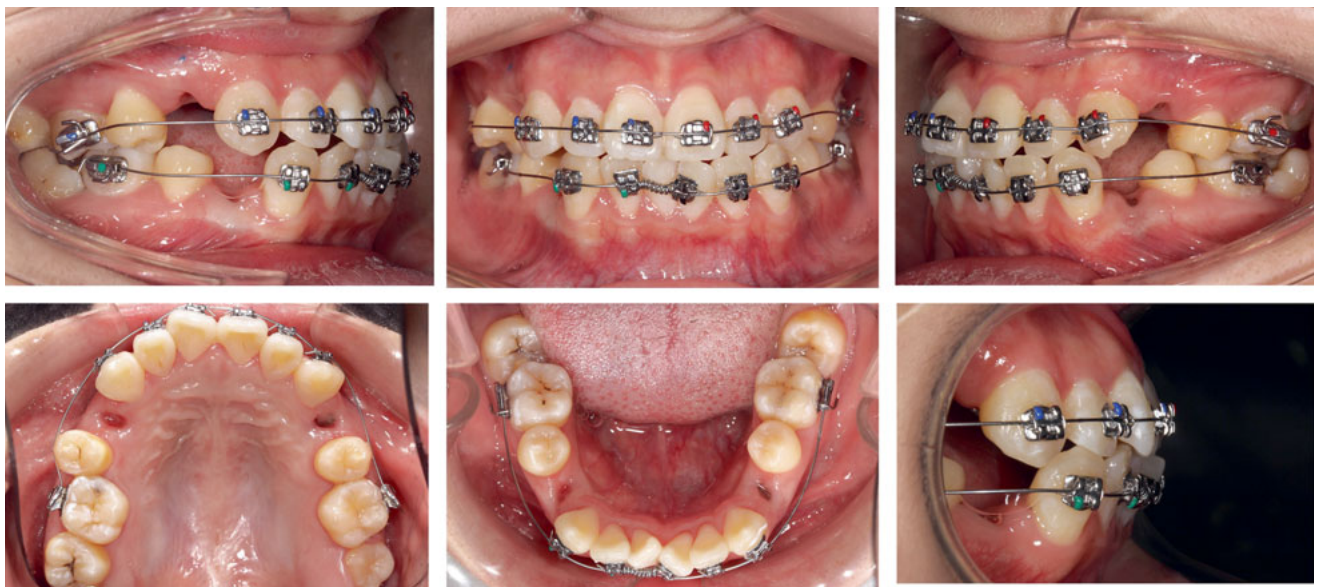
Written informed consent was obtained from the patient. The treatment was approved by the Institutional Review Board (IRB) of the biomedical ethics committee of Peking University School and Hospital of Stomatology (PKUSSIRB-202163049).

**Treatment progress**

Prior to orthodontic treatment, periodontal therapy and extraction of the four first premolars and three third molars were completed, then the patient was referred for bonding of the PASS appliance, which was characterised by the innovative design of the MLF bracket and XBT (Fig 2). The MLF brackets were originally designed to reduce friction by cutting the outer walls of the slot into slopes to shift the ligature wire off the archwire to increase the first-order clearance. In the maxilla, the XBT consists of one -25-degree auxiliary round tube that is 0.018 inches in size for thin nickel-titanium (NiTi) wires in the early stage of treatment, which will make a -25-degree tip back angle on the maxillary first molar, and another -7-degree rectangular tube with dimensions of 0.022 × 0.027 inches for thick round wires and rectangular wires in the following stages of treatment. In the mandible, a slot is cut on the occlusal wall of



**Fig 2a to f** Conventional twin bracket (a). Cutting the outer walls of the slot into slopes (b). MLF bracket: the ligature wire was shifted up to increase the wire-slot clearance (c). The XBT consists of one -25-degree auxiliary round tube and another -7-degree rectangular tube (d). Initial setting showing a -25-degree tip back angle on the maxillary first molar (e). A slot was cut on the occlusal wall of the conventional buccal tube and the slot size allowed thin archwires to go through, showing a -20-degree tip back angle on the mandibular first molar (f).

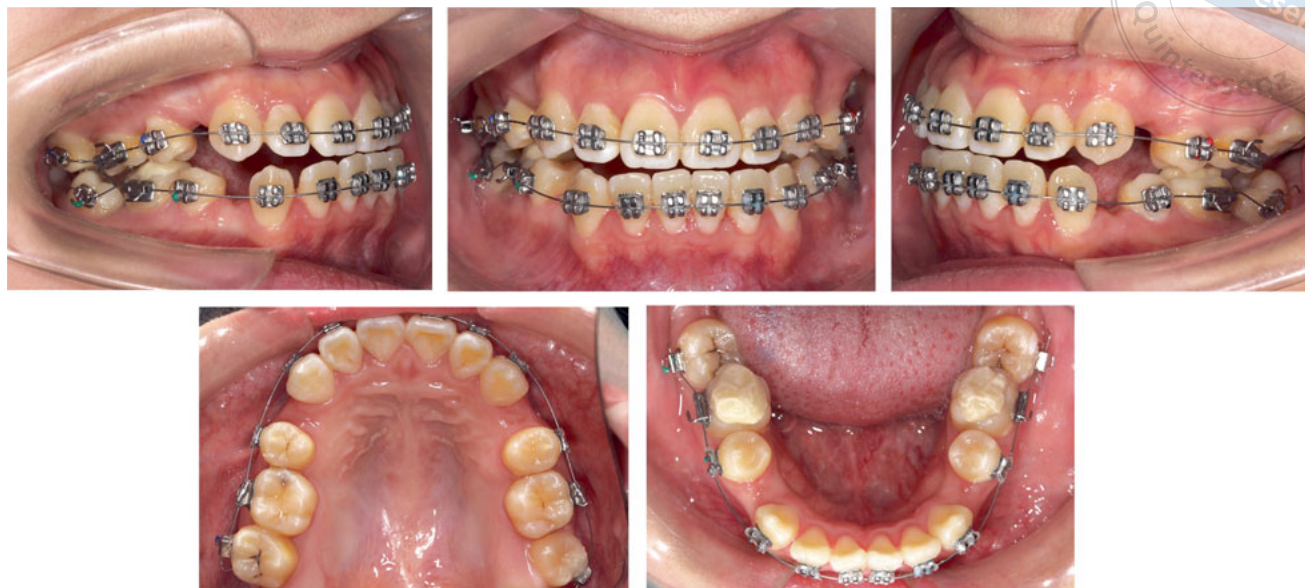

**Fig 3** The maxillomandibular canine-to-canine MLF brackets and buccal tubes on the first molars were bonded, and 0.014-inch NiTi wires were engaged separately in a -25-degree tip back tube on the maxillary molars and a -20-degree tip back tube on the mandibular molars.

the conventional buccal tube and the slot size allows thin wires (usually less than 0.018 inches) to go through, which will make a -20-degree tip back angle on the mandibular first molar.<sup>18</sup>

At the first stage, the maxillomandibular canine-to-canine MLF brackets and XBT on first molars were bonded. Since the residual space for the rmandibular

right central incisor was small, its bracket was not bonded and a NiTi coil-spring was used. Then, the 0.014-inch NiTi wires were inserted separately into a -25-degree round tube on the maxillary molar and a -20-degree buccal tube on the mandibular molar (Fig 3). When inserting NiTi wires into -25-degree maxillary XBT and a -20-degree mandibular buccal



**Fig 4** The maxillomandibular second premolar brackets and second molar tubes were bonded when the anterior teeth were aligned. Specifically, the 0.012-inch NiTi wire was inserted into the  $-20$ -degree mandibular buccal tubes to apply a gentle and constant force to upright the bilateral impacted molars.

tube, the dominant moment was applied to the anchor molars to protect the molars from drifting forwards during the alignment stage. When there was sufficient space for the mandibular right central incisor, the bracket was bonded to align the dentition.

Four months later, the maxillomandibular second premolar brackets and second molar tubes were bonded (the maxillary left third molar had sprouted automatically and was severely twisted). To improve the inclination of the impacted mandibular second molars, the 0.012-inch NiTi wire was inserted into  $-20$ -degree mandibular buccal tubes to apply a gentle and constant force to upright the bilateral impacted molars (Fig 4). In addition, since the maxillary posterior teeth would bite the buccal tubes and wires of the mandibular posterior teeth, the pad material was bonded to the occlusal surface of the mandibular first molars. Meanwhile, the 0.016-inch NiTi wires with a normal curve of Spee were changed to the  $-7$ -degree rectangular tube of the maxillary first molars. After alignment, 0.018  $\times$  0.025-inch NiTi wires with a normal curve of Spee were used to level irregularities in the third-order direction and prepare the teeth in the third order for engaging rectangular stainless-steel wires.

Eight months later, a 0.018-  $\times$  0.025-inch rectangular stainless-steel wire with a normal curve of Spee was used in the maxilla, while a 0.018-  $\times$  0.025-inch rectangular stainless-steel wire with a reverse curve of Spee was used in the mandible. Then a power chain and

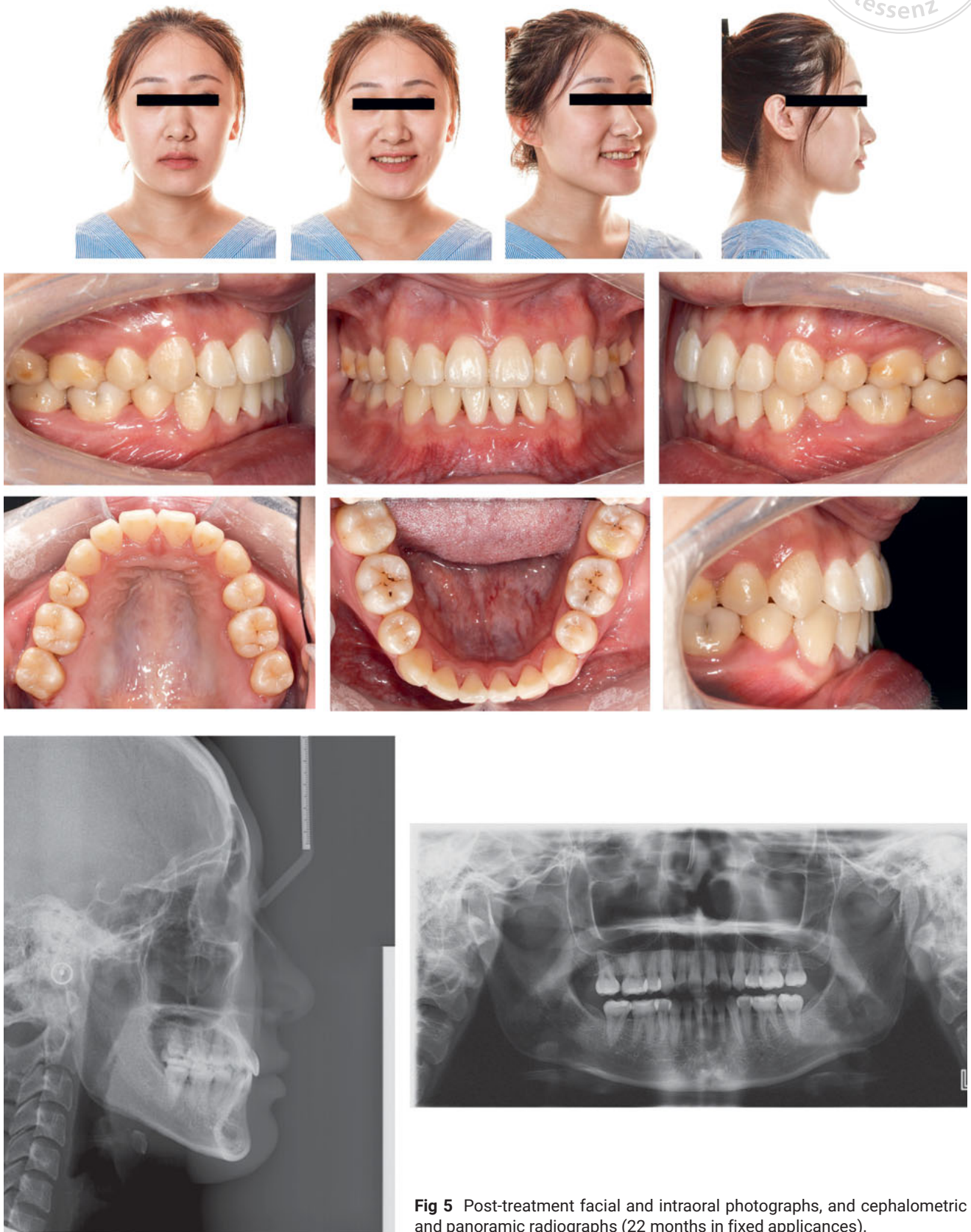maxillomandibular elastics were employed to close the space and adjust the occlusion.

Treatment was completed in a total of 22 months (Fig 5, Fig S2 [provided on request]). The patient was followed up for 4 years without complications (Fig 6).

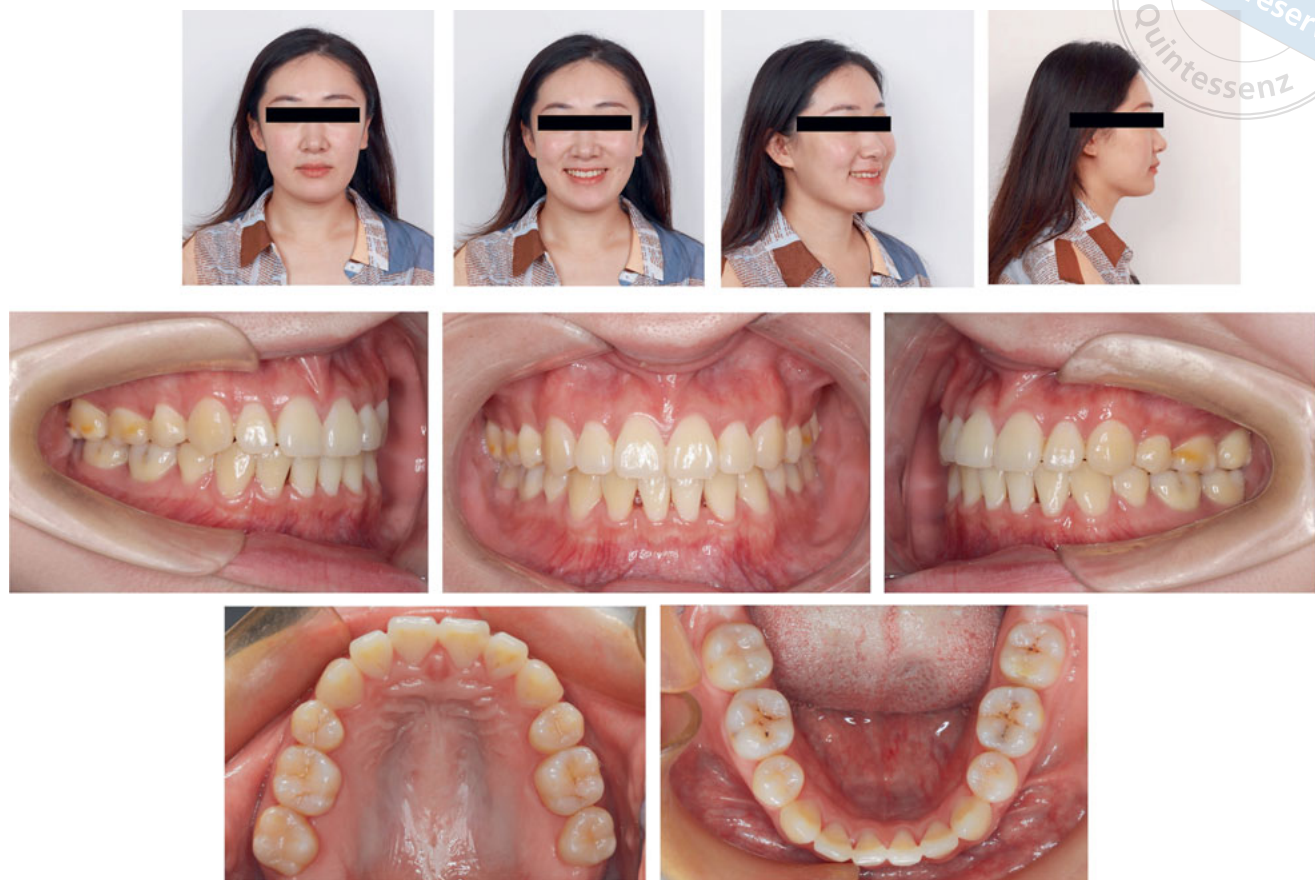## Results

After 22 months of treatment, a well-aligned dentition, a normal functional occlusion and a harmonious facial profile were achieved. The early lost maxillary left second molar had been perfectly replaced with the third molar, and the impaction of the bilateral mandibular second molars was resolved successfully, with the teeth having been rotated upright by approximately 33 degrees (Fig 5, Fig S2 [provided on request]). Since the maxillary molars in cases treated with the PASS technique would exhibit a slight backward retroversion, the physiological curve of Spee was maintained after treatment.

Through superimposition of the pre- and post-treatment cephalometric tracings, the lip inclination and protrusion of the maxillomandibular incisors were shown to have decreased significantly, which was also attributed to the improvement of the profile (Fig 7). The decrease in U1-NA and L1-NB indicated the anterior tooth retraction (U1-NA decreased by 4.0 mm, L1-NB decreased by 5.0 mm). In addition, the superimposition of the anterior skull base showed that the



**Fig 5** Post-treatment facial and intraoral photographs, and cephalometric and panoramic radiographs (22 months in fixed appliances).



**Fig 6** Post-retention facial and intraoral photographs obtained 4 years after debonding.

patient’s vertical facial height was controlled properly, and the mandibular plane angle was reduced by just 0.9 degrees. The maxillary superimposition showed a small amount of forward movement of the maxillary molars and a large amount of retraction of the maxillary incisors, whereas the mandibular superimposition revealed a small amount of retroversion and forward movement of the mandibular molars, and a large amount of retraction of the mandibular incisors. The panoramic radiograph after treatment showed that the patient had no obvious root resorption (Fig 5).

The tooth movement was further quantified by superimposing the pre- and post-treatment digital models (Fig 7),<sup>19</sup> which showed that the mean forward movement of the maxillary first molar in a sagittal direction was 1.16 mm, less than one-third of the extraction space, achieving strong sagittal anchorage control. The mean retraction of the maxillary central incisors was 5.15 mm.

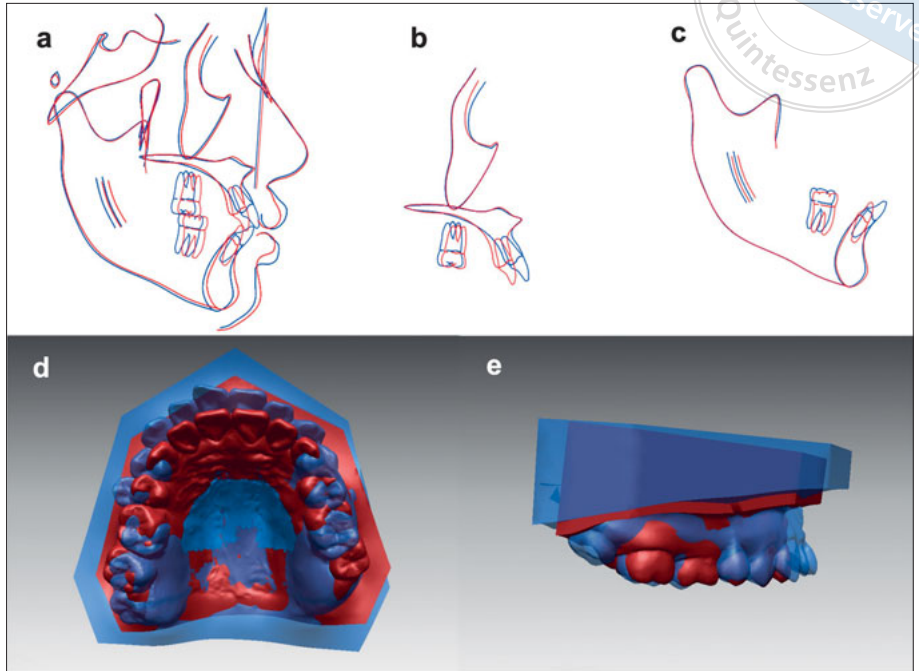
From the facial and occlusal photographs, the patient’s profile was improved after treatment, from convex to straight. The midline of the maxillomandibular dentition was consistent with the facial midline

(Fig 5). When smiling, the relationship between the lips and teeth was harmonious, and the patient displayed noticeable confidence and ease. Overall, the treatment was successful in addressing the patient’s chief complaints and post-treatment stability was excellent at the 4-year follow-up (Fig 6).

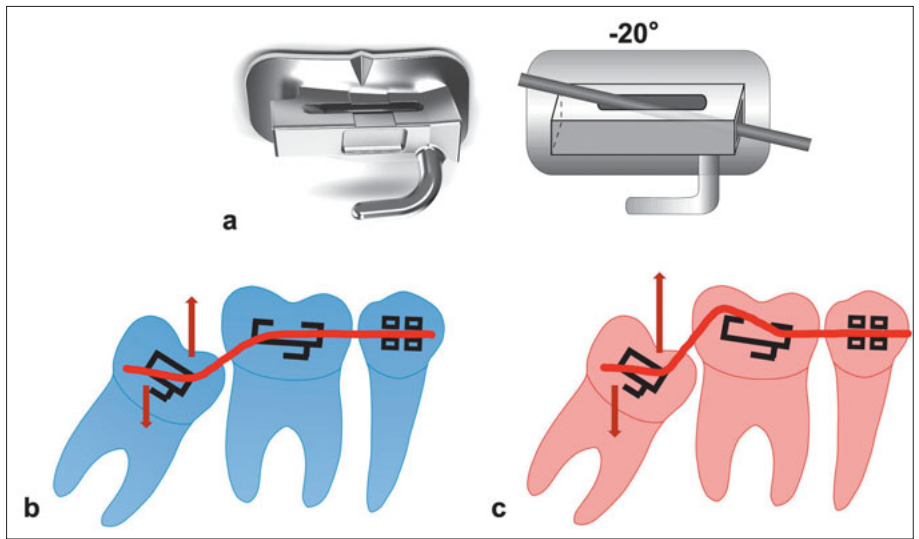
**Discussion**

The incidence of impaction of the mandibular second molars is increasing gradually, and early diagnosis and treatment of eruption disturbances contributes to optimal outcomes. In most cases, extraction or uprighting of the impacted molars was the most important decision that determined the treatment planning.<sup>20</sup> The factors that affect this decision are mainly the degree of impaction, the relationship of the tooth with the critical anatomical structures, caries, root dilacerations, periodontal problems and the complexity of the surgical procedure. In this case report, since there was a visible clinical crown that was sufficient to be bonded with buccal tubes, surgical exposure was not necessary, and the PASS technique in this case also seemed to pro-





**Fig 7a to e** Pre- and post-treatment superimposition. Anterior skull base, maxillary, and mandibular superimposition of cephalometric radiographs (a to c). Top and side views of 3D digital model superimposition, pretreatment (blue) and post-treatment (red) (d and e).



**Fig 8a to c** Sketch of uprighting of the impacted mandibular second molar. Mandibular buccal tube with a slot cut on the occlusal wall of the conventional buccal tube (a). Insertion of the NiTi wire into the conventional rectangular tube that has a  $-4^\circ$  prescribed angle (b). Insertion of the NiTi wire into the mesial entrance and out from the slot of a  $-20^\circ$  tip back angle (c).

vide good control of the mandibular second molars during uprighting, in which just a single buccal tube was effective enough, minimising patient discomfort and reducing chair time. For example, after being bonded with buccal tubes, the mandibular second molars were engaged in 0.012-inch NiTi wire, and instead of engaging in the  $-4^\circ$  conventional rectangular tube, the  $-20^\circ$  tip back angle of mandibular buccal tubes were engaged, which could apply an upward and distal force to upright the bilateral impacted molars (Fig 8). The moment applied to the mandibular second molar was greater than other ordinary moments, which could

upright the impacted mandibular molars more efficiently and comfortably. In the literature, since molar uprighting requires good anchorage control, multiple uprighting appliances have been applied successively to enhance anchorage and avoid undesirable tooth movements, such as Australian uprighting springs, cantilever springs and prefabricated Sander springs. However, in contrast to those that have a complicated design and relatively massive volume, the retroversion moment of PASS tubes has avoided greater inconvenience and discomfort, such as mucosal swelling, pain and poor oral hygiene. Furthermore, the invasiveness of miniscrew

implantation was avoided, and the bulkiness and inconvenience of extraoral appliances were also eliminated.<sup>21</sup>

Furthermore, in addition to providing good control of the mandibular second molars during uprighting, the PASS technique in this case also appeared to facilitate rapid alignment of crowded teeth and prevention of anchorage loss. The MLF bracket involved in the PASS technique has increased the clearance of the groove in the first-order direction and reduced the friction force, which can facilitate the alignment of crowded dentition at an early stage. Additionally, MLF brackets can also facilitate the “drifting” of anterior teeth back along the archwire when tip back moments are exerted, which may sometimes result in anterior scattered spacing. The PASS technique also made full use of the patient’s own physiological anchorage reserve to improve the profile. The XBT buccal tube is equipped with an additional  $-25$ -degree round tube, which is used in the early alignment stage to make the molar occupy the dominant moment. The application of conventional straight-wire appliances often causes the maxillary molars to tip forward rapidly under the influence of the forward tipping angle, resulting in the loss of anchorage and levelling of the curve of Spee of the maxillary molars, so as to occupy part of the extraction space. However, previous clinical application has shown that the  $-25$  degrees exceeds the greatest tip back angle of the malpositioned teeth. Therefore, the  $-25$ -degree tip back angle of the round tube can effectively maintain the backward tipping compensation angle of the maxillary molars and avoid iatrogenic anchorage loss. The backward tipping angles in all posterior brackets and buccal tubes of the PASS appliance also inhibit the forward tipping trend of the posterior teeth due to growth and extraction, while maintaining the posterior curve of Spee, which saves more space for anterior tooth retraction. Chen et al<sup>22</sup> conducted a clinical randomised controlled study and found that compared with the medium or maximum anchorage cases in the McLaughlin-Bennett-Trevisi group using miniscrews, Nance’s arch, headgear and other devices, the cases in the PASS group without additional anchorage devices achieved the same effect of sagittal anchorage control.<sup>22</sup>

For patients with maxillomandibular protrusion who are not undergoing orthognathic surgery, torque control of anterior incisors is equally crucial as the anchorage control of molars in maintaining profile aesthetics. Excessive retraction of the anterior incisors and inadequate control of tooth torque can lead to uprighting of the anterior teeth, which adversely affects patients’ lip and smile aesthetics, as well as the health of the al-

veolar bone. In this case, the tooth movement achieved through orthodontic treatment was a controlled oblique movement. At this time, the stress on the root tip was small, and the teeth were finally close to the centre of the alveolar bone, which was the most recommended retraction method for the health of the anterior teeth. The good control of torque during treatment was due to the groove size design of the MLF bracket, which was specifically tailored to the maxillary incisors, with a slot size of  $0.020 \times 0.027$  inches. When  $0.018 \times 0.025$ -inch rectangular stainless-steel wire was used to close the extraction space, the residual clearance was only around 2 degrees, and the positive torque could be expressed fully. Moreover, the power of retracting incisors in the PASS technique was relatively gentle, which did not further reduce the height of the labial bone plate. This adherence to gentle forces aligns with the principles of healthy orthodontic correction, effectively preventing complications such as bone dehiscence and fenestration.

### *Limitations*

In orthodontic research, case reports serve as an important method that provides detailed insight into specific cases; however, it is essential to acknowledge the limitations inherent in this approach. For example, case reports typically focus on one or a few cases, which may limit the generalisability of the findings to a larger patient population. Additionally, they often emphasise descriptive analysis and lack a control group or statistical analysis, which makes it difficult to accurately assess the effectiveness of interventions. Therefore, future clinical research requires the collection of a more diverse range of clinical cases to validate the effectiveness of treatment. This approach is crucial for ensuring that the treatment can be applied confidently to a broader patient population.

### **Conclusion**

Taking advantages of the PASS technique’s characteristic of physiological anchorage reserve and low friction, the present authors effectively and efficiently solved the problems of maxillomandibular protrusion and dental crowding in this patient. Using the mandibular buccal tube in the PASS technique, we simply and conveniently erected the impacted mandibular second molars with NiTi round wire and minimised the patient’s oral discomfort.

## Conflicts of interest

The authors declare no conflicts of interest related to this study.

## Author contribution

Dr Huan Huan CHEN contributed to the data collection, analysis and manuscript draft; Drs Gui CHEN, Guang Yao FENG, Xiu Jing WANG and Tian Min XU contributed to the case treatment design and supervision; Dr Hong SU contributed to the investigation, conceptualisation and critical revision of the manuscript. All authors gave final approval and agreed to be accountable for all aspects of the work.

(Received Dec 04, 2023; accepted Aug 08, 2024)

## References

- Hanisch M, Hanisch L, Kleinheinz J, et al. Primary failure of eruption (PFE): a systematic review. *Head Face Med* 2018;14:5.
- Evans R. Incidence of lower second permanent molar impaction. *Br J Orthod* 1988;15:199–203.
- Arevalo SS, Choy R, Rich AP, Felemban O, Bagher SM, Loo CY. Relationship of lower lingual arch appliance use and impaction of second molars: A retrospective study. *Pediatr Dent* 2020;42:123–125.
- Magkavali-Trikka P, Emmanouilidis G, Papadopoulos MA. Mandibular molar uprighting using orthodontic miniscrew implants: a systematic review. *Prog Orthod* 2018;19:1.
- Shapira Y, Finkelstein T, Shpack N, Lai YH, Kuftinec MM, Vardimon A. Mandibular second molar impaction. Part 1: Genetic traits and characteristics. *Am J Orthod Dentofacial Orthop* 2011;140:32–37.
- Hsin-Chung Cheng J, Yi-Hsuan Lee T, Fang CY, De-Shing Chen D. Orthodontic uprighting of horizontally impacted second mandibular molar through innovative use of springs. *J Dent Sci* 2023;18:939–941.
- Vedtofte H, Andreasen JO, Kjaer I. Arrested eruption of the permanent lower second molar. *Eur J Orthod* 1999;21:31–40.
- Sawicka M, Racka-Pilszak B, Rosnowska-Mazurkiewicz A. Uprighting partially impacted permanent second molars. *Angle Orthod* 2007;77:148–154.
- Barros SE, Faria J, Jaramillo Cevallos K, et al. Torqued and conventional cantilever for uprighting mesially impacted molars: A 3-dimensional finite element analysis. *Am J Orthod Dentofacial Orthop* 2022;162:e203–e215.
- Park HS, Kyung HM, Sung JH. A simple method of molar uprighting with micro-implant anchorage. *J Clin Orthod* 2002;36:592–596.
- Sabuncuoglu FA, Sencimen M, Gülses A. Surgical repositioning of a severely impacted mandibular second molar. *Quintessence Int* 2010;41:725–729.
- Rajandram RK, Ponnuthurai L, Mugunam K, Chan YS. Management of bimaxillary protrusion. *Oral Maxillofac Surg Clin North Am* 2023;35:23–35.
- Almutairi TK, Albarakati SF, Aldrees AM. Influence of bimaxillary protrusion on the perception of smile esthetics. *Saudi Med J* 2015;36:87–93.
- Villela HM. Treatment of bimaxillary protrusion using intra- and extra-alveolar miniscrews associated to self-ligating brackets system. *Dental Press J Orthod* 2020;25:66–84.
- Xu T, Vaden J, Johnston L, et al. Physiologic Anchorage Control—A New Orthodontic Concept and its Clinical Application. Cham: Springer International Publishing; 2017.
- Bales JM, Epstein JB. The role of malocclusion and orthodontics in temporomandibular disorders. *J Can Dent Assoc* 1994;60:899–905.
- Shroff B. Malocclusion as a cause for temporomandibular disorders and orthodontics as a treatment. *Oral Maxillofac Surg Clin North Am* 2018;30:299–302.
- Xu TM, Zhang X, Oh HS, Boyd RL, Korn EL, Baumrind S. Randomized clinical trial comparing control of maxillary anchorage with 2 retraction techniques. *Am J Orthod Dentofacial Orthop* 2010;138:544.e1–e9; discussion 544–545.
- Chen G, Chen S, Zhang XY, et al. Stable region for maxillary dental cast superimposition in adults, studied with the aid of stable miniscrews. *Orthod Craniofac Res* 2011;14:70–79.
- la Monaca G, Cristalli MP, Pranno N, Galluccio G, Annibali S, Pippi R. First and second permanent molars with failed or delayed eruption: Clinical and statistical analyses. *Am J Orthod Dentofacial Orthop* 2019;156:355–364.
- Lorente C, Lorente P, Perez-Vela M, Esquinas C, Lorente T. Treatment of impacted or retained second molars with the miniscrew-supported pole technique: a prospective follow-up study. *Prog Orthod* 2022;23:36.
- Chen H, Han B, Jiang R, et al. PASS versus MBT (TM) for evaluation of anchorage control in three-dimensional measurements: a randomized controlled trial. *Eur J Orthod* 2021;43:113–119.