

“REJUVENATING AESTHETICS IN A GERIATRIC PATIENT- A CASE REPORT”

Manu Rathee¹, Sujata Chahal³, Prachi Jain², Maqbul Alam³, S Divakar³, Sandeep Singh³

¹ Senior Professor and Head, ²Senior Resident, ³ Post Graduate Student,

¹Department of Prosthodontics, Post Graduate Institute of Dental Sciences, Rohtak, Haryana, India

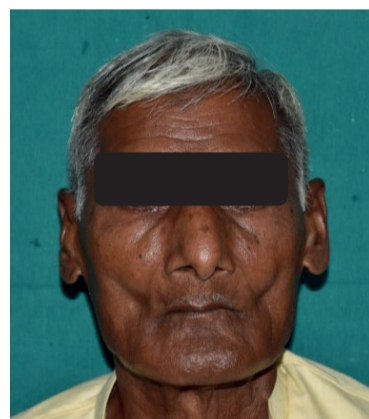Introduction

The importance of aesthetics on a person's psychological and social life cannot be overstated. Ageing has an impact on facial aesthetics due to **loss of alveolar process and teeth**, loss of muscle tonicity, **loss of elasticity of the skin**, and impairment of function. This presentation focuses on using a customised detachable cheek plumper to improve the facial aesthetics of a completely edentulous patient with sunken cheeks.

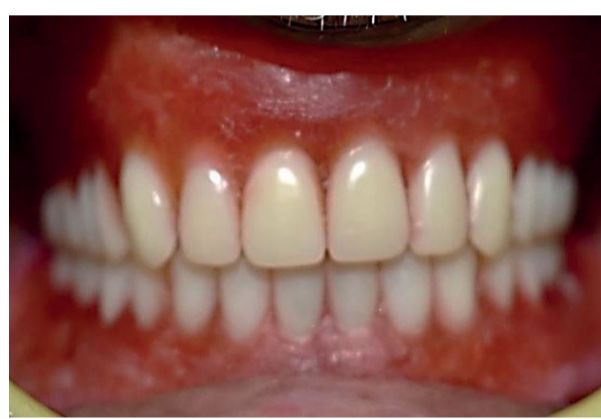Case Report

A 55-year-old male patient reported with the chief complaint of appearance of sunken cheeks due to missing upper and lower teeth. Extraoral examination revealed wrinkling of the skin and the appearance of sunken cheeks. Patient was unwilling for any invasive treatment approach, so an implant-supported prosthesis and plastic surgery was opted out. Complete denture with non-detachable cheek plumper was not planned to avoid constant muscle fatigue. Ultimately, complete denture with detachable cheek plumper was planned to meet the aesthetic demands of the patient.

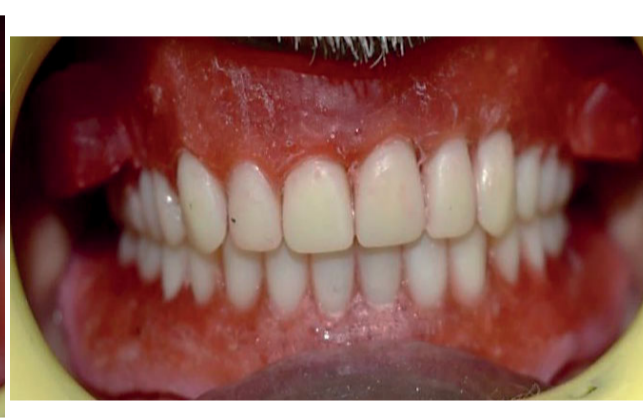Treatment



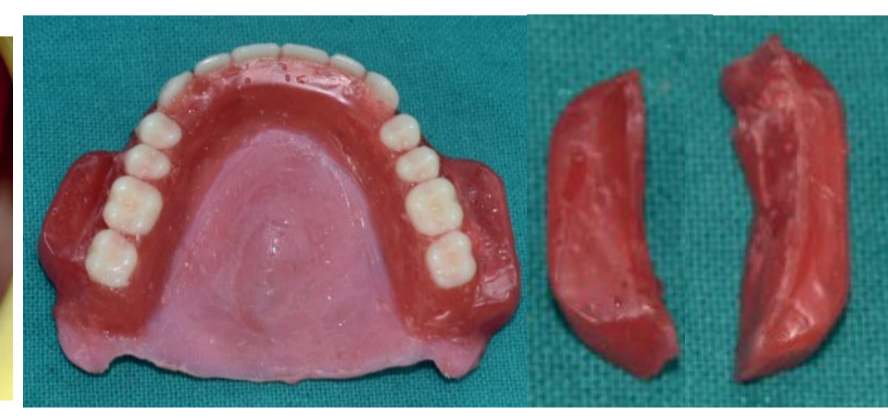
Pre-rehabilitative view



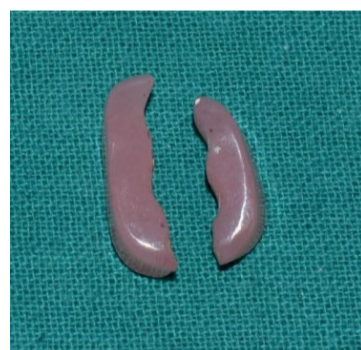Try-on of complete denture



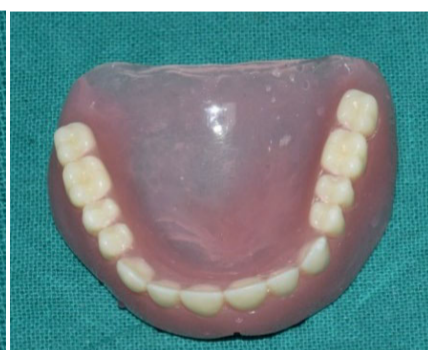Try-on with wax carved cheek plumper




Wax up of maxillary denture with cheek plumper



Finished and polished cheek plumpers with maxillary complete denture



EDS used for duplication of attachments



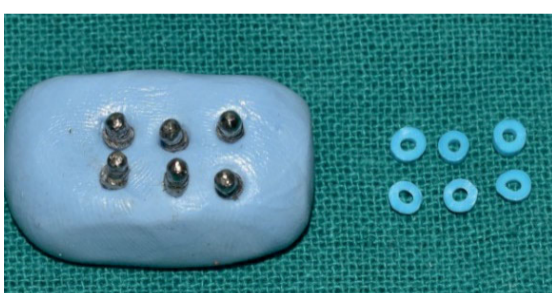
Duplication of attachments using putty material



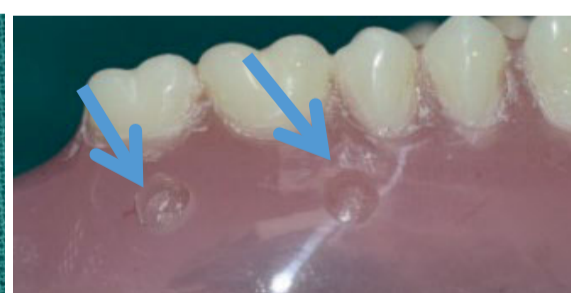Inlay wax-pattern fabricated for attachments



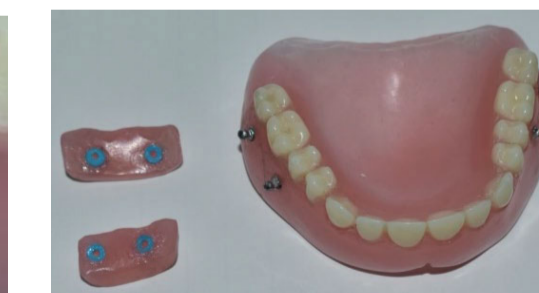Attachments after casting



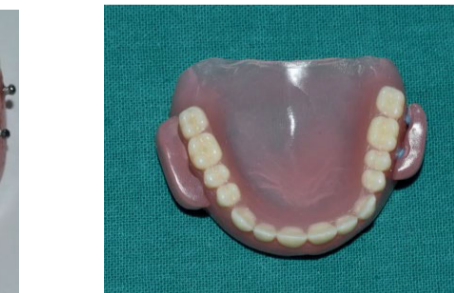Finished and polished customised attachments with orthodontic tooth separators



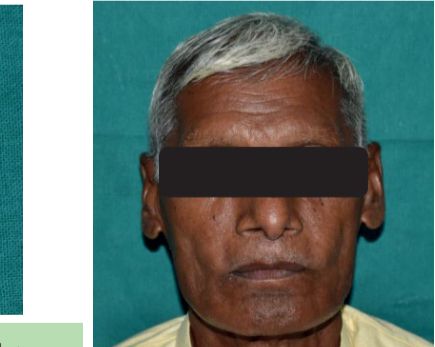Slots made in the buccal surface of the denture for the customised attachments



Separators picked up using self cure resin in the plumper part corresponding to the attachments in the denture



Cheek plumper attached to the maxillary complete denture



Post-rehabilitative view

Conclusion

This presentation presents an effective, simple, and **non-invasive treatment** option for improving facial aesthetics in a patient with hollow cheeks. The cheek plumper prosthesis with customised attachments improves the patient's aesthetics and psychological well-being by effectively restoring the contour of the cheek.

References

- Natarajan P, Kumar SM, Natarajan S, Raza FB. Management of shrunken cheeks by hollow buccal cheek plumper prosthesis. J Pharm Bioall Sci 2021;13:S875-7.
- Bains JW, Elia JP. The role of facial skeletal augmentation and dental restoration in facial rejuvenation. Aesthet Plast Surg.1994;18(3):243-246.