

Philipp Winterhalder, Nassim Ayoub, Stephan Möhlhenrich, Ali Modabber, Frank Hölzle

# Advances and limits in planning and implementing orthognathic surgery

**Introduction:** Orthognathic surgery has steadily developed since its establishment in 1849, and is characterized by consistent collaboration with orthodontics.

**Materials and Methods:** Computer-based operation planning, that also takes resulting changes in soft tissue into account, can now be carried out through three-dimensional X-ray imaging, face scans and powerful data processing. This procedure can also be used to produce individualized osteosynthesis material and osteotomy templates, which in combination even enable orthognathic surgery without the use of an occlusal wafer. Piezo surgery represents a minimally invasive alternative to conventional methods for the osteotomy. As an alternative to titanium, resorbable polymers can also be used as osteosynthesis material.

**Conclusion:** Due to modern orthodontics and computer-based operation planning, the surgery-first concept enables orthognathic surgery without prior orthodontic treatment for eligible cases. The effects of orthognathic surgery on the upper airway must be considered during planning. In addition to treating dysgnathia, orthognathic surgery expands the upper airway and has become established as a treatment option for obstructive sleep apnea.

**Keywords:** computer-based surgery planning; prediction of soft tissue changes; individualized osteosynthesis material; resorbable osteosynthesis material; surgery first; piezosurgical osteotomies; effects on the upper airways

Clinic of Oral and Maxillofacial Surgery of the University Hospital RWTH Aachen: Dr. Dr. Philipp Winterhalder, Dr. Dr. Nassim Ayoub, PD Dr. Dr. Ali Modabber, Univ.-Prof. Dr. Dr. Frank Hölzle

Department of Dental, Oral and Orthodontic Medicine, University Hospital Witten/Herdecke: PD Dr. Stephan Möhlhenrich

Translation from German: Yasmin Schmidt-Park

**Citation:** Winterhalder P, Ayoub N, Möhlhenrich S, Modabber A, Hölzle F: Advances and limits in planning and implementing orthognathic surgery. Dtsch Zahnärztl Z Int 2020; 2: 181–187

**Peer-reviewed article:** submitted: 16.03.2020, revised version accepted: 09.07.2020

**DOI.org/10.3238/dzz-int.2020.0181–0187**

## Introduction

Orthognathic surgery has been characterized by continuous advancement since its origin. In order to classify the current advancements and limitations, it is worth taking a brief look at the history of orthognathic surgery [38]. The first orthognathic surgery was performed by the American surgeon Hüllihen in 1849. He normalized the mandibular length of a female patient with burn-related deformities with anterior segmental osteotomy [13]. Among others, two principle pioneers of early orthognathic surgery are considered to be Angle and Blair, who together described standardized mandibular osteotomies in 1907 as a treatment for mandibular prognathism [5, 38]. Blair also began classifying types of dysgnathia and realized the importance of orthodontics [38]. Many other surgeons described various different procedures for mandible correction, however, due to high rate of recurrence and significant risks they were unable to implement these at the time [38].

This was followed by the development of osteotomies that are used today (Fig. 1): Wassmund displaced the maxilla with an anterior segmental osteotomy in 1935 to treat maxillary protrusion [43]. In 1955, Trauner performed the reversed L-shaped osteotomy of the mandibular ramus to treat mandibular prognathism with shortened mandibular ramus [41]. Schuchardt described the posterior maxillary osteotomy in the same year, as well as the diagonal, sagittal osteotomy of the mandibular ramus to increase bone apposition [33]. Kôle

performed osteotomies of the alveolar process in both jaws in 1959, as well as genioplasty in 1968 [20, 21]. In 1955, Obwegeser developed the revolutionary sagittal split osteotomy of the mandibular ramus [30], which was modified by Dal Pont in 1958 [9] and von Hunsuck in 1968 [14]. In 1969, Obwegeser performed the protrusion of the maxilla with a Le Fort-I osteotomy and combined this with a mandible correction in 1970, making this the first corrective osteotomy of both jaws [28, 29]. In addition to the development of the effective osteotomies, the postoperative stability of the jaws is mainly due to the advancement of osteosynthesis procedures. A working party for osteosynthesis founded in 1958 in Switzerland is still at the forefront of this research today.

In addition to surgical aspects, orthodontic treatment and interdisciplinary treatment planning is absolutely crucial for a successful therapy of dysgnathia. Major progress in orthodontics was described in 1984, specifically the possibility of using mini screws as means of skeletal anchoring [8]. When compared to its beginnings, modern day orthodontics is more gentle, faster and can even supersede lengthy preoperative tooth movement in certain cases.

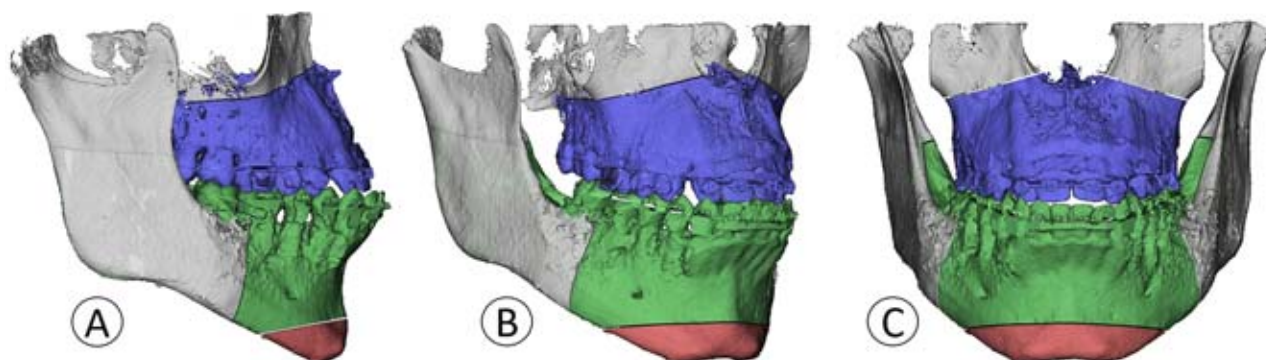
The basis of interdisciplinary treatment planning is still individualized cephalometry, which was introduced in 1974 by Hasund and further developed with Segner [10, 35]. Additionally, detailed model analyses and clinical investigations were also carried out. Treatment plans tend to mostly structure in preoperative

measures, for example orthodontic pretreatment, followed by orthognathic surgery to displace one or both jaws, and orthodontic follow-up treatment. Close collaboration between orthodontics and maxillary surgery is necessary during all treatment stages. After completing pretreatment, a model operation is performed to plan the orthognathic surgery, where the planned displacement can be implemented from previous analysis. Besides the reliable model operation using plaster models in articulators, digital operation planning is gaining more importance. Current progress in orthognathic surgery is characterized by digitalization, new materials, minimal invasiveness and an individually optimized treatment result. In the following, computer-based operation planning, prediction of soft tissue changes, individualized and absorbable osteosynthesis material, the surgery-first concept, piezosurgical orthognathic surgery and the effects on the upper airways are explained.

## Computer-based operation planning

The analog operation planning using plaster models, face bow, articulators and wax bites has proven itself reliable over decades. Computer-based operation planning has become established as an alternative in research and patient care due to the increasing availability and advancement of digital technologies.

Apart from the analog and digital approach, the exact recording of dental, skeletal, functional and aesthetic difficulties is an absolute necessity for

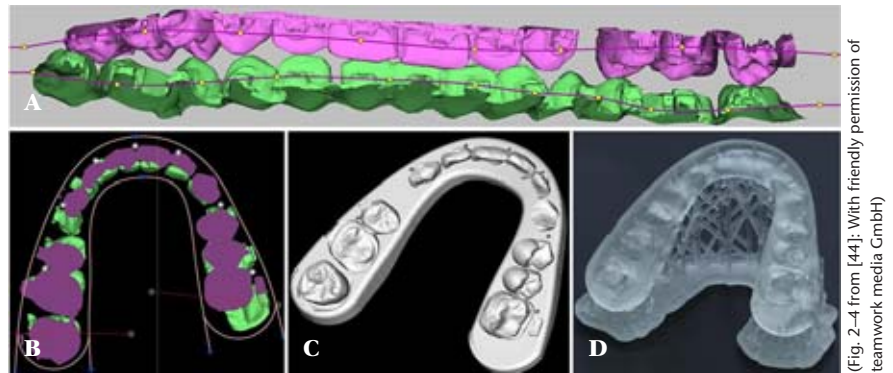


**Figure 1A–C** Course of common osteotomy lines in jaw corrections, lateral view (A), semi-profile (B) and frontal view (C): on maxilla in Le Fort-I plane (blue), on mandible via bilateral sagittal split osteotomy (green) and if needed with additional genioplasty (red).

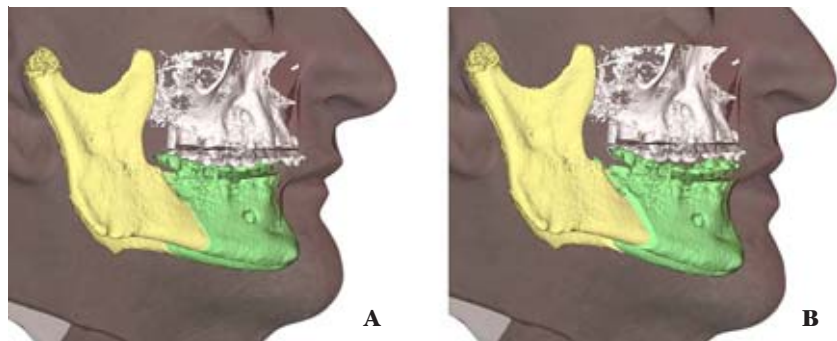
successful planning. In addition to orthodontic and maxillofacial expertise, individualized cephalometry, model analysis and the clinical investigation are the basis of the treatment planning.

The operation planning should not be viewed as an isolated part, but rather as part of the treatment plan. Similar to analog operation planning, the digital method leads to success when the practitioner has the ability to gather and understand the underlying individual dental, skeletal, aesthetic and functional parameters and their deviation. Recent findings of cephalometric fundamental principles, such as the harmony box, enable the optimal use of benefits of 3-dimensional, computer-based dysgnathia-planning.

The individualized cephalometry sets the basis for a successful treatment, despite new analysis and planning methods. The holistic diagnosis to differentiate between dental and skeletal causes is made possible with individualized cephalometry. Furthermore, this enables the analysis of facial proportions as well as the assessment of mutual dependencies in sagittal and vertical direction. The individualized cephalometry helps to adjust the Curve of Spee and Wilson, correctly plan the axial position of the front teeth in jaw rotations and estimate the autorotatory effects when changing the vertical relation. However, software programs for digital operation planning offer reduced determination of cephalometric parameters, or parameters that are not comparable with classic parameters. Program designers should offer a complete cephalometric analysis. After completing comprehensive diagnostics, it is not only possible to create operation splints, but also to create analyses and predictions for soft tissue. Especially in the case of asymmetries digital operation planning is helpful because mirror images can be made for optimal adjustment. Movements of the skeletal bases can only be assessed roughly, which is why cephalometric analysis of required movements is helpful at the beginning of treatment planning. The patient should be informed about measurement and prediction



**Figure 2A–D** Digital production of splints with dental arches after the planned displacement (A and B). The splint is produced as an STL-file (C) and is printed in 3-D (D).



**Figure 3A and B** Simulation of soft tissue in a patient with class-II malocclusion. Pre-operative situation (A), planning of mandibular protrusion (B).

errors of the used equipment and programs during the analysis and prediction of soft tissue changes, in order to avoid unrealizable, specific expectations and even legal concerns. The computer-based operation planning combined 3-dimensional x-ray data from a DVT or CT with a digital impression of the dental arches. Additionally, a face scan was done to analyze the soft tissue. These data sets are used to create a complete model which simulates the operation using a planning software.

After successful virtual displacement of the jaws the operation splints are created digitally and 3D-printed and after the osteotomy, the new jaw positions can be defined using teeth impressions (Fig. 2, 3 and 4). During planning, the jaw movements can be positioned in the 1/100 mm-range, which can lead to successful treatment of complex cases, such as vertical height correction [15]. The benefits of computer-

based operation planning regarding the quality of results include the consideration of the individual temporomandibular joint axis and the expected change of the soft tissue. The planning time period can be shortened in computer-based operation planning compared to analog planning. For the planning of a sole mandibular displacement, the planning time period of 195 minutes can be reduced by 41 % and when displacing both jaws, the planning time period of 385 minutes can be reduced by 62 % [31].

Shortening of the planning period described in literature compared to analog operation planning is questionable when considering the additional survey of fundamental dysgnathia parameters and creating splints in 3D print. In the alternative definition of the necessary movements and submission of implementation to a service provider or software program, the planning know-

how and understanding of specific surgical circumstances would be lost. A shortened planning period would therefore reduce the practitioners influence and produce additional costs. Other disadvantages of computer-based operation planning are high investment costs and the necessary staff training in the new workflow.

### Prediction of soft tissue changes

Displacement of the jaws also causes displacement of the soft tissue. While the displacement of the jaws can be planned and implemented precisely, the resulting displacement of the soft tissue is more difficult to predict. The reason for this is that the soft tissues do not follow the displacement in a 1:1 ratio but rather in a different ratio depending on their anatomic region. Even with the knowledge of these specific displacement factors, the individual patients' reaction complicates a prediction and does not allow a precise statement concerning displacement of soft tissues. Because soft tissues play an important role in the aesthetic and functional result, it is rewarding to consider the most optimal estimated displacement during planning and evaluating. The mean values of displacement factors were determined for anatomic regions in many studies. Lateral x-rays and photographs were used as underlying two-dimensional data, whereas new studies are mostly based on three-dimensional data from CT, DVT and face scans. Displacement factors were described as follows, whereas a displacement factor smaller than 1 means a smaller displacement than the according bone reference point: 0.78 in the upper lip region, 0.77 in the lower lip region, 0.74 on the tip of the nose 0.70 at the base of the nose and 0.73 on the cheeks [23] as well as 0.94 on the chin [6].

Due to the postoperative swelling, an assessment of the actual soft tissue displacement is advisable after a few weeks. An investigation of prediction accuracy of 3 planning programs showed a mean error of 1.8 mm +/- 0.8 mm for 3D (Dolphin Imaging & Management Solutions, Chatsworth, CA, USA), 1.2 mm +/- 0.4 mm für ProPlan CMF (Dentsply-Sirona,

York, PA, USA) and 1.3 mm +/- 0.4 mm for the prediction based on a Finite-Elemente-Simulation [18]. However, the measurement of the soft tissues already has a rather high error, which is why a mean error of up +/- 2 mm is needed to collect 90 % of the measurement points in a face scan [17].

### Individualized osteosynthesis material

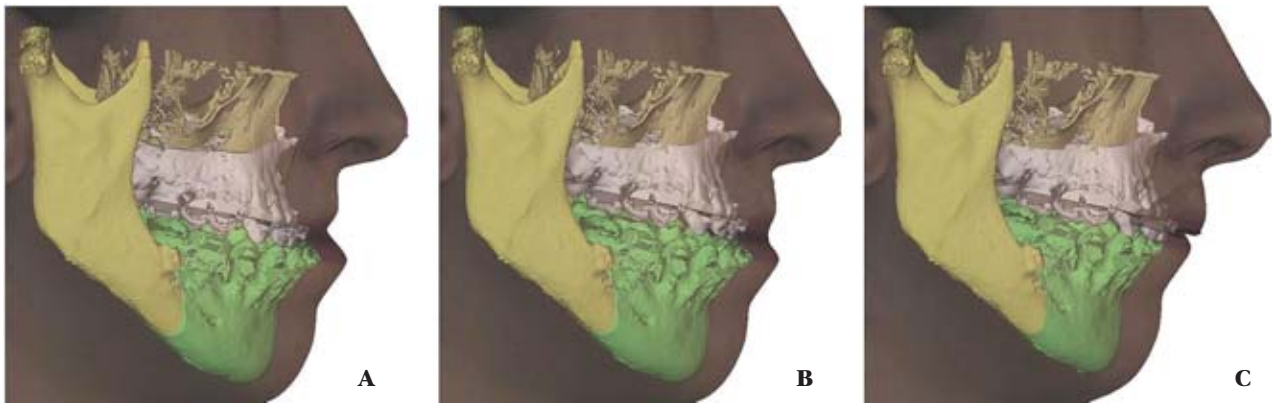
New manufacturing technologies have made it possible to create patient-specific osteosynthesis material and osteotomy templates. The basis for this is computer-based operation planning. Osteosynthesis material can therefore be directly created based on the virtual shaping via laser sintering. A less complex alternative is to print synthetic 3D models of the bone using the virtual situation and to individualize ready-made osteosynthesis materials by bending it into the correct position. With computer-based operation planning, osteotomy templates from synthetic materials can be 3D-printed and used to implement osteotomies. These osteotomy templates can additionally help keep the safety distance to the dental roots or nerves. Using patient-specific osteosynthesis materials and osteotomy templates is supposed to make exact implementation of planned jaw displacement possible. This is an advantage in the vertical dimension, because the implementation of pure splint-based methods is surgically demanding. In combination with fitting laser sintering osteosynthesis materials, the screw holes of the osteotomy templates can be used after the osteotomy for osteosynthesis material. Thus, the position is transferred accurately and an operation splint is not absolutely essential [39]. However, templates and individually manufactured osteosynthesis materials, especially when sintered when splintered, are inapplicable with minimally-invasive surgical access because of the larger measurements. Another possibility for surgery without splints is using intraoperative navigation [4]. There are optical and electromagnetic systems available that are not widely applied due to high equipment costs despite good results. The disadvan-

tage of an operation without splints is that the occlusion is unstable right after the displacement, because the orthodontic follow-up treatment still has to take place. Therefore, a splint is useful in many cases to ensure post-operative results during the healing phase, even when it is not essential for intraoperative positioning.

A significant disadvantage of patient-specific osteosynthesis material and osteotomy templates is the increased planning effort. Specifically, the laser sintering of patient-specific osteosynthesis material for orthognathic surgery may be the equivalent of the entire case compensation and has not yet established itself as a standard process. With further developments of manufacturing technologies and more frequent implementation, cost reduction and a wider application of these innovative processes is anticipated in the future.

### Resorbable osteosynthesis material

Back in 1932 an absorbable osteosynthesis material with pure magnesium was available, which did not stand the test of time due to its biochemical instability. Absorbable osteosynthesis material took a back seat, because the introduction of stainless steel in the 1940s and titanium in the 1950s has been successful until today [34]. However, persisting osteosynthesis material can lead to foreign body sensation, bacterial colonization and growth limitation. Titanium causes artefacts in x-ray or MRI imaging, which complicates diagnosis. Even with new accidents or other necessary surgeries, persisting osteosynthesis materials can be a source of complications. The osteosynthesis material is often removed after bone healing is completed, however, this second procedure also comes with all the risks of surgery and is more complicated due to the existing scars. The biochemical industry has developed absorbable polymers since the 1960s and absorbable osteosynthesis material since the 1990s, among other things based on lactic acid, glycolic acid and polydioxanone. Depending on the composition, the degradation period takes weeks to years, whereas the



(Fig. 1–4: P. Winterhalder)

**Figure 4A–C** Simulation of soft tissue in a patient with class-III malocclusion. Preoperative Situation (A), planning of maxillary protrusion (B) and the subsequent mandibular retrusion (C).

degradation is mostly based on hydrolysis of ester bonds [34]. In order to partially compensate reduced stability when compared to titanium, absorbable osteosynthesis material is designed larger and requires more invasive surgical access. In clinical studies, the osteosynthesis material made out of resorbable polymer in orthognathic surgeries in the maxilla or mandible is sufficiently stable and causes similar complication rates like osteosynthesis material made out of titanium [1, 16, 32].

Resorbable osteosynthesis made out of polymers has the additional special feature that it is not radiopaque. This offers the benefit that no artefacts are created in imaging, however, it also prevents position and integrity control. Another option are new magnesium alloys with zirconium and strontium, which are significantly more stable compared to polymers, but need to be improved concerning biocompatibility [34].

### Surgery first

When developing dysgnathia, the position of the teeth usually changes to compensate the underlying skeletal cause. For example, in mandibular retrognathia the incisors are often severely protruded. In such a compensated situation a normalization of the skeletal base by jaw displacement would cause a malocclusion. Therefore, in the conventional treatment concept the tooth positions are normalized with regard to the alveolar ridge and the dental arch. This causes the dysgnathia-based malocclusion

to become fully visible. The dental arches that now match each other are optimally aligned when planning the surgery and relocated accordingly during the operation.

In contrast to this, a treatment concept called surgery first has been used since 2009, where no or minimal orthodontic treatment occurs before the orthognathic surgery [7]. The best and definite occlusion is aspired after surgery, with orthodontic treatment. The procedure was made possible with advances in orthodontic treatment, often using skeletal anchoring elements such as mini screws. Benefits of the surgery-first concept include shortening the treatment period by several months as well as reduced strain on the patient by skipping the pretreatment phase [36]. The surgery-first concept is used in class-II and class-III dysgnathia patients for displacement of one or both jaws. The treatment planning is demanding and often involves computer-supported operation planning. There is no consensus of indications of the surgery-first concept. Patients with mandibular prognathism, less teeth crowding and little dental compensation are particularly suitable [7, 22]. Patients with a mandibular retrognathia, deep bite, narrow palate or pronounced axis deviation of the front teeth seem unsuitable for the surgery-first concept [7, 22]. Treatment using the surgery-first concept should be critically questioned with increasing asymmetry of the patient case [11], even though successful treatments of pronounced asymmetry

have also been described [42]. The treatment procedures of the surgery-first concept are continually being developed, which can lead to extended indications. For example, the treatment of protrusion of lower incisors as a surgery-first concept was described as a piezosurgical subapical osteotomy [12]. In order to facilitate the extensive, postoperative orthodontic treatment in a surgery-first concept, intraoperative skeletal anchoring elements such as mini-plates or mini-screws were inserted if needed. Postoperative, combined with increased bone remodeling [36], tooth movements can occur within a few months. Orthodontists and surgeons must individually discuss every patient to decide if the surgery-first concept depicts a promising therapy option. Even though all dislocations in digital operation planning are done very precisely, the spatial positioning of the segments provides a challenge for the user. Besides surgical aspects, orthodontic expertise is indispensable to determine positions of the jaws and to assess the postoperative orthodontic movements. Based on the absent preoperative decompensation the postoperative occlusion is only minimally supported in the surgery-first concept. Unfavorable occlusion contacts can even lead to postoperative mandibular malpositions [7]. Postoperative stabilizing with an operation splint is therefore recommended especially during multiple segmentations of the maxilla. The splint can be strengthened additionally for intraoperative application

with an incorporated transpalatal bow.

### Piezosurgical osteotomies

The basis of piezosurgery is the observation by the brothers Pierre and Jaques Curie in 1880, that a crystal converts electrical energy into micro-movements, which is considered the piezoelectric effect (Greek, piezein, 'to push'). The clinical use has developed since the 1950s from isolated applications in dentoalveolar surgery to the modern piezosurgery gadgets used today, where the first one in Germany was approved in 2002 [40].

In piezosurgery, micro movements of the piezo crystal are transferred to the tissue with different serrated or grained top pieces. The vibrations amount to 60–210  $\mu\text{m}$  with a frequency of 25–29 kHz [2]. Hereby, only hard tissue is removed and soft tissue such as nerves are spared. Piezosurgery can be used to displace the maxilla in the Le Fort-I level as well as the displacement of the mandible in sagittal segmental osteotomy. A significant reduction of operation time is possible by piezosurgical osteotomies [19], while in addition the saw cuts can be designed more delicately. A review with 799 patients showed no prolonged duration of the piezosurgical segmental osteotomy of the mandible [37]. The frequency of nerve impairment at least 6 months after the surgery with 4.7 % of the patients was significantly less compared to the 61.6 % when a saw was used. In another study, the impact of piezosurgery on the fracture pattern of sagittal segmental osteotomy was examined, whereby no difference to conventional osteotomy was found in comparison [27]. The selection of different osteotomy top pieces makes piezosurgery versatile, and a curved top piece was used to weaken the base of the lower jaw. However, similarly to conventional weakening, this showed a poorer fracture pattern.

### Effects on upper airways

Repositioning of the jaws with the adjacent soft tissues inevitably affects the upper respiratory tract. A measurement of the upper airways and their transformations is possible using three-dimensional imaging with DVT

or CT and has presented superior to measurements based on lateral radiographs [25]. In case of impaired nasal breathing the airway resistance in this region can be determined with rhinomanometry. A palate expansion causes an expansion of the main nasal cavity and a reduced airway resistance during nasal breathing [3].

A mandibular retrusion reduces the airways and bears the risk of respiratory problems in patients with pronounced class-III malocclusions. This is particularly true, when the tongue is large compared to the jaw. As an alternative to the sole mandibular retrusion in patients with class-III malocclusion, an additional maxillary protrusion should be considered. Even this approach causes changes in the airways, which was described in a study with 22 patients [24]. The volume of the nasopharynx changed from 5,4  $\text{cm}^3$  preoperative to 5,2  $\text{cm}^3$  postoperative. The volume of the oropharynx reduced from 17,8  $\text{cm}^3$  to 11,9  $\text{cm}^3$ , and the hypopharynx from 7,2  $\text{cm}^3$  to 4,6  $\text{cm}^3$ . Despite the significant changes no patient presented respiratory problems 6 months postoperative.

The effects of jaw corrections on the airways are not only of importance in orthognathic patients. In obstructive sleep apnea syndrome reduced muscle tone causes blocked upper airways due to the weight of the soft tissues. The patient wakes up repeatedly because of respiratory distress, often without even realizing. Although there are usually only a few symptoms besides fatigue, it can lead to serious health issues such as arterial hypertension, heart disease or diabetes mellitus. In therapy-resistant obstructive sleep apnea the protrusion of both jaws is an important treatment option [26]. In order to displace the mandibular soft tissues even more anteriorly, an additional genioplasty is often performed.

### Conflicts of interest

The authors declares that there is no conflict of interest within the meaning of the guidelines of the International Committee of Medical Journal Editors.

### Literatur

1. Agnihotry A, Fedorowicz Z, Nasser M, Gill KS: Resorbable versus titanium plates for orthognathic surgery. *Cochrane Database Syst Rev* 2017; 10: CD006204
2. Aly LAA: Piezoelectric surgery: Applications in oral and maxillofacial surgery. *Future Dental Journal* 2018; 4: 105–111
3. Baratieri C, Alves M, Souza MMG de, Souza Araújo MT de, Maia LC: Does rapid maxillary expansion have long-term effects on airway dimensions and breathing? *Am J Orthod Dentofacial Orthop* 2011; 140: 146–156
4. Berger M, Kallus S, Nova I et al.: Approach to intraoperative electromagnetic navigation in orthognathic surgery: A phantom skull based trial. *J Cranio-maxillofac Surg* 2015; 43: 1731–1736
5. Blair VP: Operations on the jaw-bone and face. *Surg Gynecol Obstet* 1907; 4: 67–78
6. Chang Y-J, Ruellas ACO, Yatabe MS, Westgate PM, Cevidanes LHS, Huja SS: Soft tissue changes measured with three-dimensional software provides new insights for surgical predictions. *J Oral Maxillofac Surg* 2017; 75: 2191–2201
7. Choi D-S, Garagiola U, Kim S-G: Current status of the surgery-first approach (part I): concepts and orthodontic protocols. *Maxillofac Plast Reconstr Surg* 2019; 41: 10
8. Creekmore TD, Eklund MK: The possibility of skeletal anchorage. *J Clin Orthod* 1983; 17: 266–269
9. Dal Pont G: L'osteotomia retromolare per la correzione della progenia. *Minerva Chir* 1, 1958
10. Hasund A: Klinische Kephalemtrie für die Bergen-Technik. Universität in Bergen, Kieferorthopädische Abteilung des zahnärztlichen Institutes 1974
11. Hernández-Alfaro F, Guijarro-Martínez R, Peiró-Guijarro MA: Surgery first in orthognathic surgery: what have we learned? A comprehensive workflow based on 45 consecutive cases. *J Oral Maxillofac Surg* 2014; 72: 376–390
12. Hernández-Alfaro F, Nieto MJ, Ruiz-Magaz V, Valls-Ontañón A, Méndez-Manjón I, Guijarro-Martínez R: Intraoral subapical osteotomy for dentoalveolar decompensation of class III malocclusion in 'surgery-first' and 'surgery-early' orthognathic treatment. *Int J Oral Maxillofac Surg* 2017; 46: 80–85
13. Hullihen SP: Case of elongation of the under jaw and distortion of the face and neck, caused by a burn, successfully treated. *Am J Dent Sci* 1849; 9: 157–165
14. Hunsuck EE: A modified intraoral sagittal splitting technic for correction of

- mandibular prognathism. *J Oral Surg* 1968; 26: 250–253
15. Jaisinghani S, Adams NS, Mann RJ, Polley JW, Girotto JA: Virtual surgical planning in orthognathic surgery. *Eplasty* 2017; 17:ic1. eCollection 2017
16. Kanno T, Sukegawa S, Furuki Y, Nariai Y, Sekine J: Overview of innovative advances in bioresorbable plate systems for oral and maxillofacial surgery. *Jpn Dent Sci Rev* 2018; 54: 127–138
17. Knoops PGM, Beaumont CAA, Borghi A et al.: Comparison of three-dimensional scanner systems for craniomaxillofacial imaging. *J Plast Reconstr Aesthet Surg* 2017; 70: 441–449
18. Knoops PGM, Borghi A, Breakey RWF et al.: Three-dimensional soft tissue prediction in orthognathic surgery: a clinical comparison of Dolphin, ProPlan CMF, and probabilistic finite element modelling. *Int J Oral Maxillofac Surg* 2019; 48: 511–518
19. Koba A, Tanoue R, Kikuta S, Hirashima S, Miyazono Y, Kusakawa J: The usefulness of piezoelectric surgery in sagittal split ramus osteotomy. *Kurume Med J* 2018; 64: 57–63
20. Köle H: Surgical operations on the alveolar ridge to correct occlusal abnormalities. *Oral Surg Oral Med Oral Path* 1959; 12: 277–288
21. Köle H: Die chirurgische Behandlung von Formveränderungen des Kinns. *Wien, Med Wschr* 1968; 118: 331–334
22. Kwon T-G, Han MD: Current status of surgery first approach (part II): precautions and complications. *Maxillofac Plast Reconstr Surg* 2019; 41: 23
23. Lai H-C, Denadai R, Ho C-T, Lin H-H, Lo L-J: Effect of Le Fort I maxillary advancement and clockwise rotation on the anteromedial cheek soft tissue change in patients with skeletal class III pattern and midface deficiency: a 3D imaging-based prediction study. *J Clin Med* 2020; Jan; 9(1): 262; doi: 10.3390/jcm9010262
24. Lee W-Y, Park Y-W, Kwon K-J, Kim S-G: Change of the airway space in mandibular prognathism after bimaxillary surgery involving maxillary posterior impaction. *Maxillofac Plast Reconstr Surg* 2016; 38: 23
25. Lenza MG, Lenza MMdO, Dalstra M, Melsen B, Cattaneo PM: An analysis of different approaches to the assessment of upper airway morphology: a CBCT study. *Orthod Craniofac Res* 2010; 13: 96–105
26. Liu SY-C, Awad M, Riley RW: Maxillomandibular advancement: contemporary approach at stanford. *Atlas Oral Maxillofac Surg Clin North Am* 2019; 27: 29–36
27. Möhlhenrich SC, Ayoub N, Peters F et al.: Evaluation of the lingual fracture patterns after bilateral sagittal split osteotomy according to Hunsuck/Epker modified by an additional inferior border osteotomy using a burr or ultrasonic device. *Int J Oral Maxillofac Surg* 2019; 48: 620–628
28. Obwegeser HL: Surgical correction of small or retrodisplaced maxillae. The „dish-face“ deformity. *Plast Reconstr Surg* 1969; 43: 351–365
29. Obwegeser HL: Die einzeitige Vorbewegung des Oberkiefers und Rückbewegung des Unterkiefers zur Korrektur der extremen Progenie. *Schweiz Mschr Zahnheilk* 1970; 80: 347–356
30. Obwegeser HL, Trauner R: Zur Operationstechnik bei der Progenie und anderen Unterkieferanomalien. *Dtsch Zahn Mund Kieferheilkd* 1955; 23: 11–26
31. Park S-Y, Hwang D-S, Song J-M, Kim U-K: Comparison of time and cost between conventional surgical planning and virtual surgical planning in orthognathic surgery in Korea. *Maxillofac Plast Reconstr Surg* 2019; 41: 35
32. Park Y-W: Bioabsorbable osteofixation for orthognathic surgery. *Maxillofac Plast Reconstr Surg* 2015; 37: 6
33. Schuchardt K: Formen des offenen Bisses und ihre operativen Behandlungsmöglichkeiten. In: Schuchardt K, Wassmund M (Hrsg): Fortschritte der Kiefer- und Gesichts-Chirurgie, Bd. I., Thieme, Stuttgart 1955, S. 222
34. Schumann P, Lindhorst D, Wagner MEH, Schramm A, Gellrich N-C, Rücker M: Perspectives on resorbable osteosynthesis materials in craniomaxillofacial surgery. *Pathobiology* 2013; 80: 211–217
35. Segner D, Hasund A: Individualisierte Kephalemetrie. Segner 1991
36. Sharma VK, Yadav K, Tandon P: An overview of surgery-first approach: recent advances in orthognathic surgery. *J Orthod Sci* 2015; 4: 9–12
37. Silva LF, Carvalho-Reis ENR, Bonardi JP et al.: Comparison between piezoelectric surgery and conventional saw in sagittal split osteotomies: a systematic review. *Int J Oral Maxillofac Surg* 2017; 46: 1000–1006
38. Steinhäuser EW: Historical development of orthognathic surgery. *J Cranio-maxillofacial Surg* 1996; 24: 195–204
39. Suojanen J, Leikola J, Stoor P: The use of patient-specific implants in orthognathic surgery: a series of 32 maxillary osteotomy patients. *J Craniomaxillofac Surg* 2016; 44: 1913–1916
40. Thomas M, Akula U, Ealla KKR, Gajjada N: Piezosurgery: a boon for modern periodontics. *J Int Soc Prev Community Dent* 2017; 7: 1–7
41. Trauner R: Zur Progenieoperation. *Ost Z Stomat* 1955; 52: 361
42. Villegas C, Uribe F, Sugawara J, Nanda R: Expedited correction of significant dentofacial asymmetry using a „surgery first“ approach. *J Clin Orthod* 2010; 44: 97–103; quiz 105
43. Waßmund M: Lehrbuch der praktischen Chirurgie des Mundes und der Kiefer, Bd. 1., H. Meußner, Leipzig 1935
44. Winterhalder P, Ayoub N, Modabber A, Hölzle F: Dysgnathiechirurgie im digitalen Workflow. *teamwork* 2020; 01: 34–39



(Photo: Philipp Winterhalder)

**DR. DR. PHILIPP WINTERHALDER**  
Clinic of Oral and Maxillofacial Surgery  
of the University Hospital  
of the RWTH Aachen  
Pauwelstr. 30  
52074 Aachen, Germany  
pwinterhalde@ukaachen.de