

# Treatment of Giant Unicystic Ameloblastoma by Suction Drainage and Secondary Curettage: a Case Report

Bing LIU<sup>1</sup>, Wen Feng ZHANG<sup>1</sup>, Xin Ming CHEN<sup>2</sup>, Zhi Jun SUN<sup>3</sup>, Mohd Jamal Alsharif<sup>1</sup>, Yi Fang ZHAO<sup>1</sup>

The concept of unicystic ameloblastoma (UA) was first introduced by Robinson and Martinez in 1977<sup>1</sup>. UA has been defined as a distinct clinicopathological entity based on its unicystic radiographic appearance and histological findings<sup>2,3</sup>. It occurs most frequently in the posterior mandible of young patients, associated with unerupted teeth. In most cases, it tends to develop without symptoms except for swelling. However, the cystic lesions frequently reach a large size, particularly at the angle and ascending ramus of the mandible, before they are noticed.

Several therapeutic approaches have been adopted for managing large cystic lesions in the mandible, including marginal or partial mandibulectomy, curettage alone or combined with cryotherapy or chemical fixation<sup>3-5</sup>. However, these procedures often cause morbidities, such as extraoral scar resulted from an extraoral incision, infection, or pathologic bone fracture. In addition, post-operative maxillofacial deformities and inferior alveolar nerve damages may also occur.

Marsupialisation may be used as the primary option for the management of large mandibular cystic lesions with an aim to minimise complications associated with the reconstruction of the defect. However, it takes sever-

al months or even years to treat UA by marsupialisation, depending on the size of cystic cavity and the rate of bone regeneration, which discourages its wide use clinically. Few articles have documented the long-term outcomes of UA patients treated with marsupialisation<sup>6,7</sup>. Therefore it is necessary to revise the treatment modalities for large UA.

In the present report, an effective and simple surgical procedure is described, which may be a good alternative for the treatment of large UA in the mandible. The technical details and potential advantages are described.

## Case Report

A 28-year-old Chinese woman was referred to the Department of Oral and Maxillofacial Surgery, Hospital of Stomatology, Wuhan University, with a swelling in the left cheek in May 2004. The patient noticed a progressively enlarging hard bony swelling, which affected her facial symmetry for a month. A week before presentation, the swelling extended to her left cheek and a dull pain arose in the swelling area.

An extraoral examination showed a swelling that extended from the mandibular angle to the temporo-mandibular joint region, sensitive to touch (Fig 1A). Intraorally, the retromolar triangle was occupied by the expanded anterior border of the left ascending ramus. The overlying mucosa demonstrated a slight hyperemia in the posterior mandibular alveolus. In addition, moderate mobility with pain on percussion was observed in the left mandibular second molar.

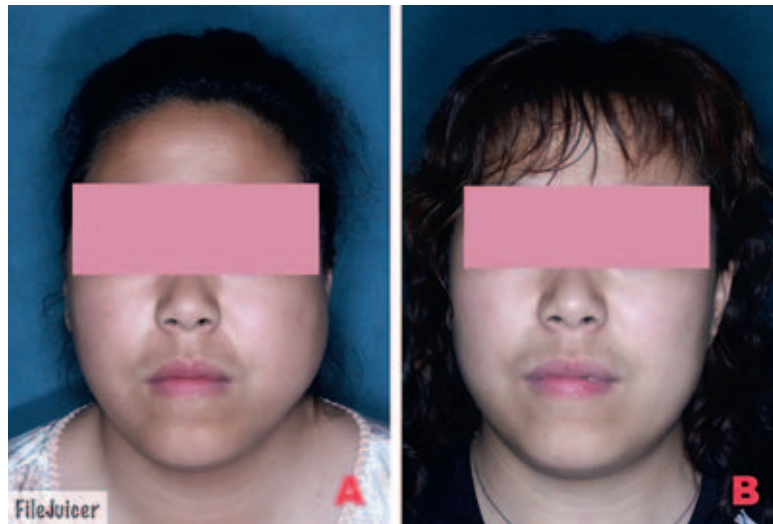A panoramic radiographic examination revealed a large unilocular radiolucency with remarkable bone absorption and expansion in the left mandibular molar and

<sup>1</sup> Department of Oral and Maxillofacial Surgery,

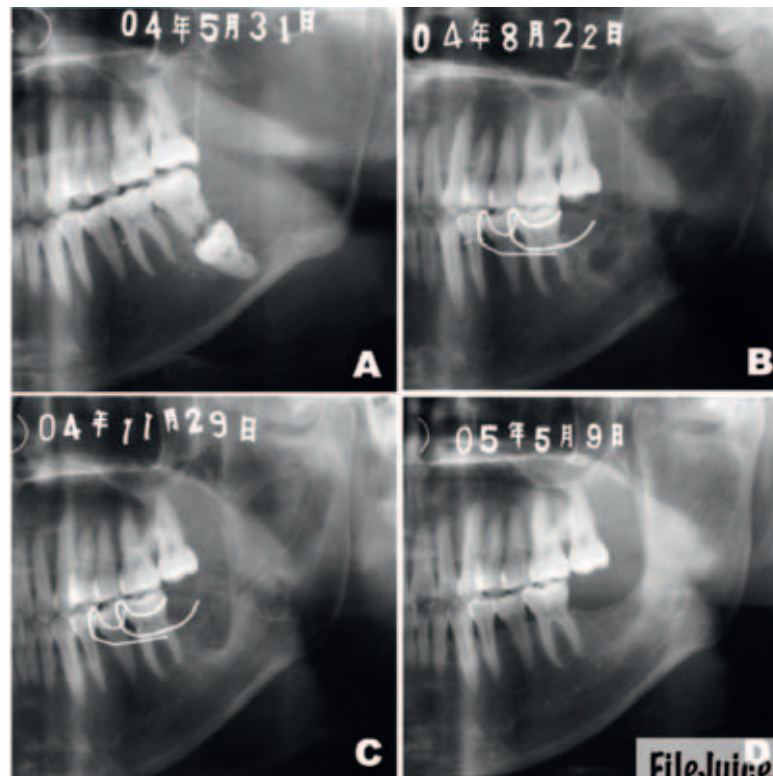
<sup>2</sup> Department of Oral Pathology,

<sup>3</sup> Key Laboratory for Oral Biomedical Engineering of Ministry of Education, School of Stomatology, Wuhan University, Wuhan, P.R. China.

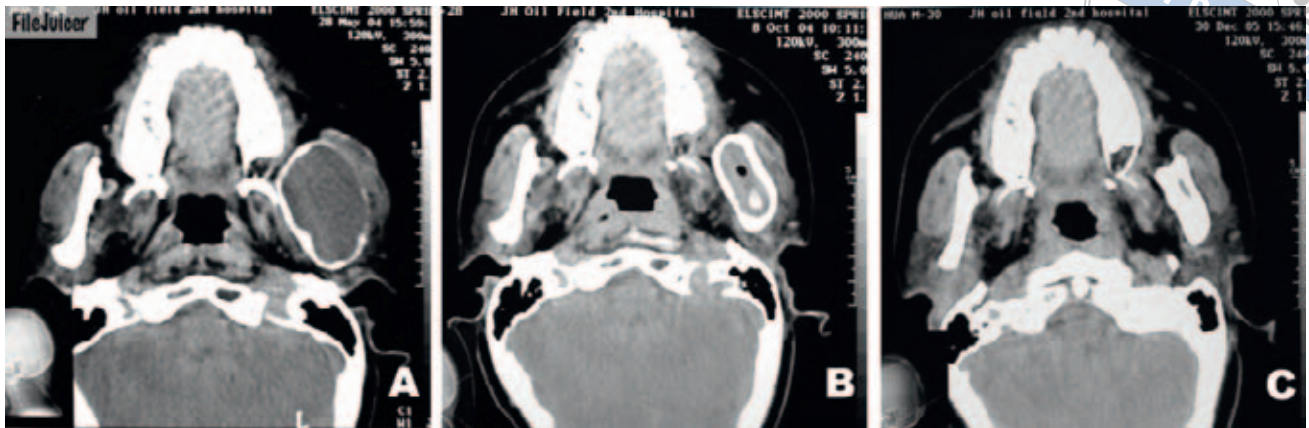
**Corresponding author:** Dr. Yi Fang ZHAO, Department of Oral and Maxillofacial Surgery, School of Stomatology, Wuhan University, 237 Luoyu Road, Wuhan, Hubei Province 430079, P.R. China. Tel: 86-27-876 46313. Fax: 86-27-87873260. E-mail: yifang@public.wh.hb.cn



**Fig 1** Frontal views of the patient. A) Pre-operative view. B) After 5 months of suction drainage.



**Fig 2** Panoramic radiographs of unicystic ameloblastoma in the mandible. A) A unilocular radiolucency lesion with an impacted third molar. B) The lesion after 3-month suction drainage. C) The lesion after 5-month suction drainage (B and C with the drainage tube in the cavity). D) New bone formed in the defect 6 months after curettage.



**Fig 3** Axial CT scans showing the lesion in the left ramus of maximum section. A) An expansile low-density lesion with interrupted margins in the left ramus before treatment. B) The shape of mandibular ramus similar to the opposite side after 4-month suction drainage. The drainage tube was seen as a radiolucent spot in the cavity. C) Approximate normal shape and density of the left mandibular ramus 13 months after curettage.

ascending ramus regions. The lesion was associated with the impacted left mandibular third molar, and measured approximately  $10 \times 7.5 \text{ cm}^2$ , extending to the condyloid process and coronoid process. Thinning of the anterior and posterior borders of the mandibular ascending ramus as well as cortical bone of interrupted posterior border was observed in the panoramic radiograph (Fig 2A). Computed tomography showed a well-demarcated expansile lesion with low density in the left posterior mandible, which extended to the left mandibular sigmoid notch area. Both coronal and axial views demonstrated cortical destruction of the buccolingual plate with obvious buccolingual expansion (Fig 3A).

The medical history of the patient was not noteworthy, except for a well-controlled hyperthyroidism. Pre-operative routine blood and urine tests showed normal results. An aspiration of the lesion yielded thin, yellow-coloured fluid. Therefore, our impression was that the lesion might be cyst or cystic lesion.

### Surgical Procedures and Results

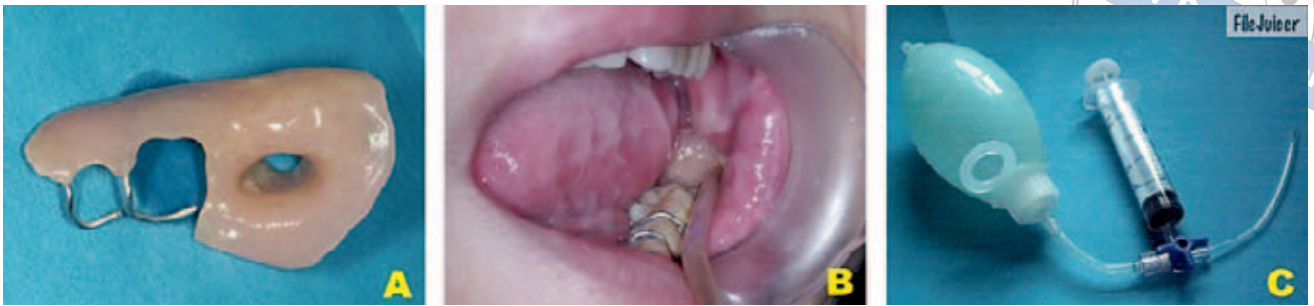Following advised consent from the patient about the surgical plan, marsupialisation and extraction of the left mandibular second and impacted third molars were performed under local anaesthesia. Biopsy was undertaken simultaneously and the surgical specimen was submitted to the Department of Pathology for histopathological diagnosis. We noted at the time of surgery that the lesion

was a single cystic cavity in the mandible. A 1-cm incision was cut to make a window on the alveolar ridge of the second molar. The intracystic fluid was completely aspirated out and the cavity was packed with iodoform gauze. Pathological diagnosis confirmed the lesion as an ameloblastoma with mural growth.

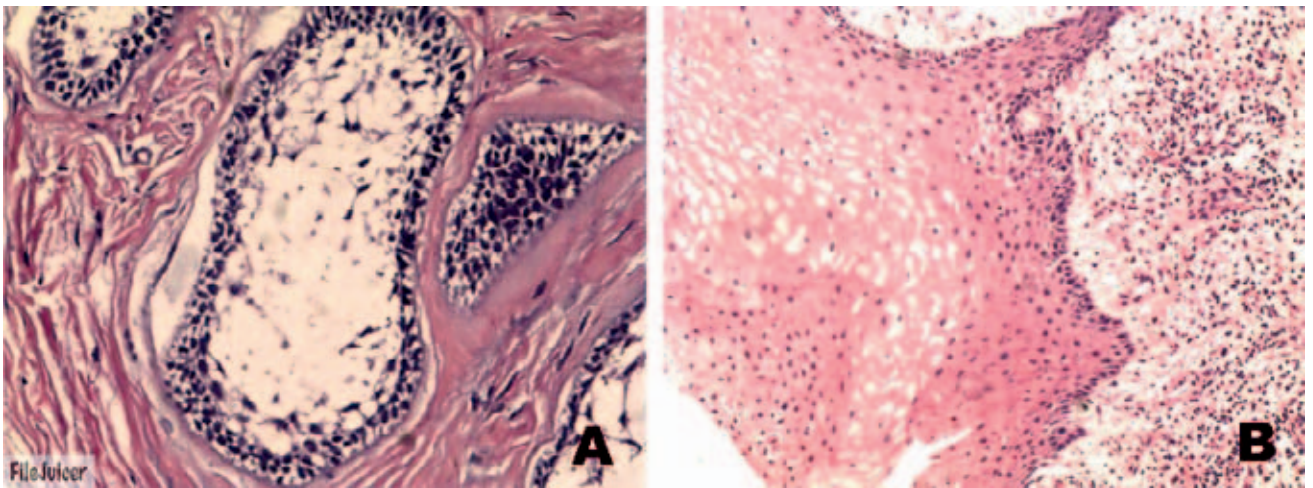
Three days after the operation, the cystic cavity was irrigated by a special irrigation apparatus, which consisted of an acrylic resin obturator with retention clasps and a hole in the centre, a syringe, a triplet, a drainage tube, and a 200 ml hollow ball for air suction. The obturator was placed on the incision to keep the window open and prevent food debris becoming trapped in the cystic cavity, and mounted onto the adjoining teeth with a wire clasp (Fig 4A). The drainage tube was inserted into the cystic cavity through the hole of the obturator and the outlet was bound to the first mandibular premolar with a wire (Fig 4B). The cystic cavity was rinsed through the syringe connected to the drainage tube twice daily with sterile saline to avoid accumulation of inflammatory exudation. The negative pressure of the cystic cavity was kept at  $-4.5$  to  $-6.2 \text{ kPa}$  by exhausting air in the ball connected to the drainage tube through the triplet. Suction drainage was performed for 24 hours daily for the first 2 weeks and later maintained at no less than 8 hours per day during sleeping time.

Clinical and radiological examinations were carried out once every 3 months. The volume of the cavity was measured by measuring the volume of the sterile saline





**Fig 4** Apparatus of suction drainage. A) Acrylic resin obturator with a hollow and retention clasps. B) Placement of drainage tube into the cystic cavity through the obturator. C) The plastic syringe, triplet and suction ball for irrigation and negative pressure.



**Fig 5** Pathological features of the UA. A) Intramural nodule with islands of infiltrating ameloblastoma tissue (haematoxylin-eosin, original magnification 200x). B) A hyperplastic epithelial lining with intramural chronic inflammatory cells infiltrating after suction drainage (haematoxylin-eosin, original magnification 100x).

injected into the cavity through the triplet while still maintaining the maximum intracystic negative pressure (-6.2 kPa).

The swelling of the facial soft tissue was no longer apparent 1 week post-operation. The size of the lesion shrank by 65% and bone regeneration was seen after the first 3 months of suction drainage. After suction drainage for 5 months, the facial symmetry was restored to an acceptable appearance (Fig 1B), the volume of the cavity reduced by 90% and the size of the lesion decreased by 81% in the panoramic radiograph (Fig 2C). The contour of mandibular ascending ramus appeared similar to the opposite one and the profile of the mandible also reshaped to almost normal size, concur-

rent with notable new bone formation (Figs 2B and 3B).

Treatment was completed with curettage via intraoral incision under local anesthesia after 5.5 months of suction drainage. Finally, Carnoy's solution was spread on the surface of the bony defect for 5 minutes. No complications occurred after application of curettage and Carnoy's solution. No recurrence was found within 22 months of follow-up (Figs 2D and 3C).

Histologically, this case was classified as Ackermann type III unicystic ameloblastoma<sup>8</sup>. It was observed that a hyperplastic epithelial lining infiltrated with intramural chronic inflammatory cells after suction drainage (Fig 5).

## Discussion

UA was a newly defined benign tumour in the mandibular region. The recurrence rate of UA is reported to range from 10.7% to 25%. This rate is much lower than the reported recurrence rate of conventional ameloblastoma that are treated only by enucleation or curettage<sup>1,2</sup>. Considering the benign characteristics and low recurrence rates of UA, the priority for treatment of the lesion should be focused on maintaining the functions of jaw and improving the quality of life for the patient. Therefore, UA should be treated with a more conservative procedure, and should have a better prognosis.

In the present case, it was demonstrated that the intracystic negative pressure was successfully formed due to the continuity of the cystic wall covered by the thin cortex and periosteum. Obviously, the intracystic negative pressure accelerated the shrinking of the cyst and stimulated new bone formation, followed immediately the reduction of the tumour. Compared with conventional marsupialisation, negative pressure drainage not only maintained the integrity of bony structure but also shortened treatment period. Furthermore, negative pressure suction also ameliorated the facial soft tissue swelling rapidly in initial stage of treatment, partly because negative pressure counteracted soft tissue tension overlying the affected area and improved the local venous and lymph drainage.

Radiological examinations demonstrated that bone regeneration in the defect was observed in the early stage of the treatment. This suggests that negative pressure stimulated bone formation in the area adjacent to the exterior surface of the cyst wall. In fact, the reduction of the volume of the cavity was more significant in the first two weeks, which could not be showed by panoramic radiographs. After 5.5 months of suction drainage, the cyst was curetted via an intraoral approach and followed by application of Carnoy's solution. Carnoy's solution has been employed for treatment of keratocysts, and shown to reduce recurrence rates when combined with enucleation or curettage. Recently, Lee et al<sup>5</sup> reported that 27 out of 29 cases of UA exhibited mural invasion. They reported the recurrence rate was 10% after enucleation and suggested potential benefits of Carnoy's solution against recurrence of UA.

A retrospective analysis of UA by radiographic examination after marsupialisation has been reported<sup>9</sup>. It was

found that the earliest radiographic sign was scalloping of a sclerotic margin of regenerated bone within the cavity of the original lesion, usually after 6 months of marsupialisation. The procedures with secondary curettage we employed here showed earlier bone regeneration and decreased the time of treatment. The daily living of the patient was somewhat affected by the suction drainage apparatus in therapeutic sessions, and this could be improved by using refined mini apparatus in the future.

In conclusion, the present study shows that negative pressure suction drainage for large UA could rapidly reduce treatment time and maximally restore jaw function and facial aesthetics. Secondary curettage and application of Carnoy's solution could completely remove the lesion. The procedures were simple, minimally invasive and cost-effective. Further studies with more cases and long-term follow-up are needed to substantiate the method as an acceptable modality for large UAs in the mandible.

## References

1. Robinson L, Martinez MG. Unicystic ameloblastoma: a prognostically distinct entity. *Cancer* 1977;40:2278-2285.
2. Reichart PA, Philipsen HP, Sonner S. Ameloblastoma: biological profile of 3677 cases. *Eur J Cancer B Oral Oncol* 1995;31B:86-99.
3. Philipsen HP, Reichart PA. Unicystic ameloblastoma. A review of 193 cases from the literature. *Oral Oncol* 1998;34:317-325.
4. Chapelle KA, Stoelinga PJ, de Wilde PC, Brouns JJ, Voorsmit RA. Rational approach to diagnosis and treatment of ameloblastomas and odontogenic keratocysts. *Br J Oral Maxillofac Surg* 2004; 42:381-390.
5. Lee PK, Samman N, Ng IO. Unicystic ameloblastoma: use of Carnoy's solution after enucleation. *Int J Oral Maxillofac Surg* 2004; 33:263-267.
6. Nakamura N, Higuchi Y, Mitsuyasu T, Sandra F, Ohishi M. Comparison of long-term results between different approaches to ameloblastoma. *Oral Surg Oral Med Oral Pathol Oral Radiol Endod* 2002;93:3-20.
7. Zhao YF, Liu B, Jiang ZQ. Marsupialization or decompression of the cystic lesions of the jaws. *Shanghai Kou Qiang Yi Xue* 2005;14:325-329.
8. Ackermann GL, Altini M, Shear M. The unicystic ameloblastoma: a clinicopathological study of 57 cases. *J Oral Pathol* 1988;17:541-546.
9. Furuki Y, Fujita M, Mitsugi M. A radiographic study of recurrent unicystic ameloblastoma following marsupialization. *Dentomaxillofac Radiol* 1997;26:214-218.