

# Therapy modalities in Papillon-Lefèvre-Syndrome-associated periodontitis

## A systematic review

N. Tassabehji, Th. Hoffmann, B. Noack  
Department of Periodontology, TU Dresden, Germany



### INTRODUCTION - OBJECTIVES

Papillon-Lefèvre syndrome (PLS) is a rare autosomal recessive disorder characterised by palmoplantar hyperkeratosis combined with severe periodontitis (Figures 1- 5). PLS is caused by loss of function mutations in the *cathepsin C (CTSC)* gene. CTSC is a lysosomal enzyme of polymorphonuclear leukocytes. It plays an essential role in the host's defense against bacteria.

The eruption of the deciduous teeth is mostly associated with gingival inflammation and subsequent rapid destruction of the periodontium. Thus, the primary dentition is usually exfoliated prematurely. The same severe aggressive periodontitis occurs in the permanent dentition, leading premature destruction of periodontal tissue. Preventing excessive tooth loss seems to be hardly attainable. Early case reports on periodontal treatment in PLS patients described unsuccessful outcomes. Thus, tooth loss leading to edentulism seemed to be an unavoidable part of this syndrome. However, since the early 1980s, more and more cases have been reported treated by different therapy protocols with controversial success rates.

The aim of this systematic review was to evaluate the outcome of the reported therapy regimens of PLS-associated periodontitis and to provide an evidence-based protocol for clinicians for treating periodontitis in these patients.

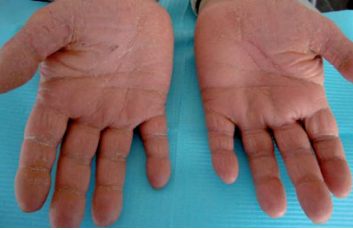

Fig 1 and 2: Palmo-plantar keratosis in PLS

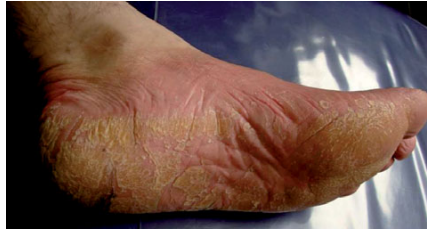

Fig. 3 and 4: Severe periodontitis of deciduous teeth

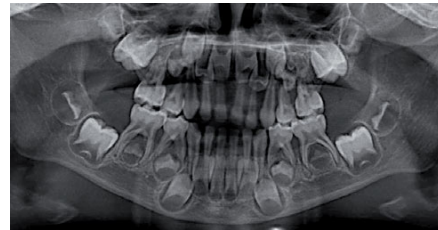
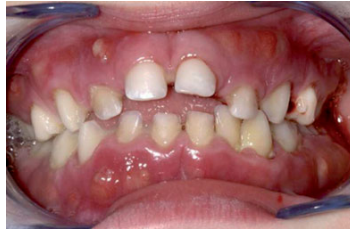

Fig. 5: early tooth loss in PLS

### MATERIAL AND METHODS

Based on a structured protocol, a literature search was performed using two databases (MEDLINE and the Cochrane Oral Health Group specialist trials register). In addition, reference lists of original and review articles were searched. Articles published from January 1980 until April 2016 in English or German were considered if they reported therapy modalities and therapy outcomes in PLS-associated periodontitis. The search protocol was structured according to the guidelines of the PICO Format: P (patients): PLS patients in all age groups; I (intervention/exposure): therapy of periodontitis as a manifestation of PLS; C (comparison): different therapy regimens; O (outcome): tooth loss or periodontitis progression. Only articles with a minimum of 1 year observation time were included. The search was carried out using the search terms described in Table 1. Two reviewers independently extracted papers of interest.

### RESULTS

1140 articles were identified by the primary search, whereas 15 additional articles were found by hand. After applying the inclusion/exclusion criteria and removing duplicates, 43 publications (case reports, case series and one prospective study) were included in the review (Fig. 6). 92 patients (aged from 2 to 34 years) with follow-up time between 1 year and 33 years were analysed.

Table 1: Search terms used for electronical search

Hits	Search Expression
496	Papillon-Lefevre syndrome
106	PLS AND Periodontitis
201	Papillon-Lefevre syndrome AND Periodontitis
285	Papillon-Lefevre syndrome AND Periodontal disease
45	Periodontitis as systemic manifestation
6	Periodontitis AND manifestation AND Papillon-Lefevre syndrome
1	Periodontitis as manifestation of PLS

Two promising therapeutic protocols were found:

- i. Start of therapy in the first dentition:  
Extraction of all deciduous teeth 6 months before eruption of permanent teeth and/or all erupted permanent teeth (tooth-less phase), followed by the prescription of antibiotics to eliminate all niches 6 months before the breakthrough of the first permanent teeth
- ii. Start of therapy during mixed dentition/ permanent dentition:  
Oral hygiene instructions and prophylaxis, extraction of teeth with advanced periodontitis, anti-infectious therapy (mechanically and adjunctive systemic antibiotics, mouth rinses with chlorhexidine)

Both modalities are combined with antibiotics, close monitoring, and maintenance therapy. Recommended antibiotics are amoxicillin or amoxicillin + clavulanic acid or amoxicillin + metronidazole.

18 reported cases were treated using the first protocol as well as seven additional cases with a tooth-less period during mixed dentition or of permanent dentition. 22 out of these 25 patients (88%) showed stability in periodontal conditions during follow-up time (1 to 15 years). Other treatment regimes resulted in periodontitis progression in 31 % of cases.

In the one prospective cohort study, two out of 13 patients with early treatment initiated before the eruption of the first permanent tooth lost teeth (8 lost teeth) during follow-up compared to 12 out of 22 patients (99 lost teeth) with treatment starting later following protocol two (Ulbro et al. 2005).

Only a few cases (N = 10) were treated by implant therapy. Osseointegration seems to be possible in PLS patients. However, peri-implantitis and implant loss have also been reported. Long-term results are not yet available.

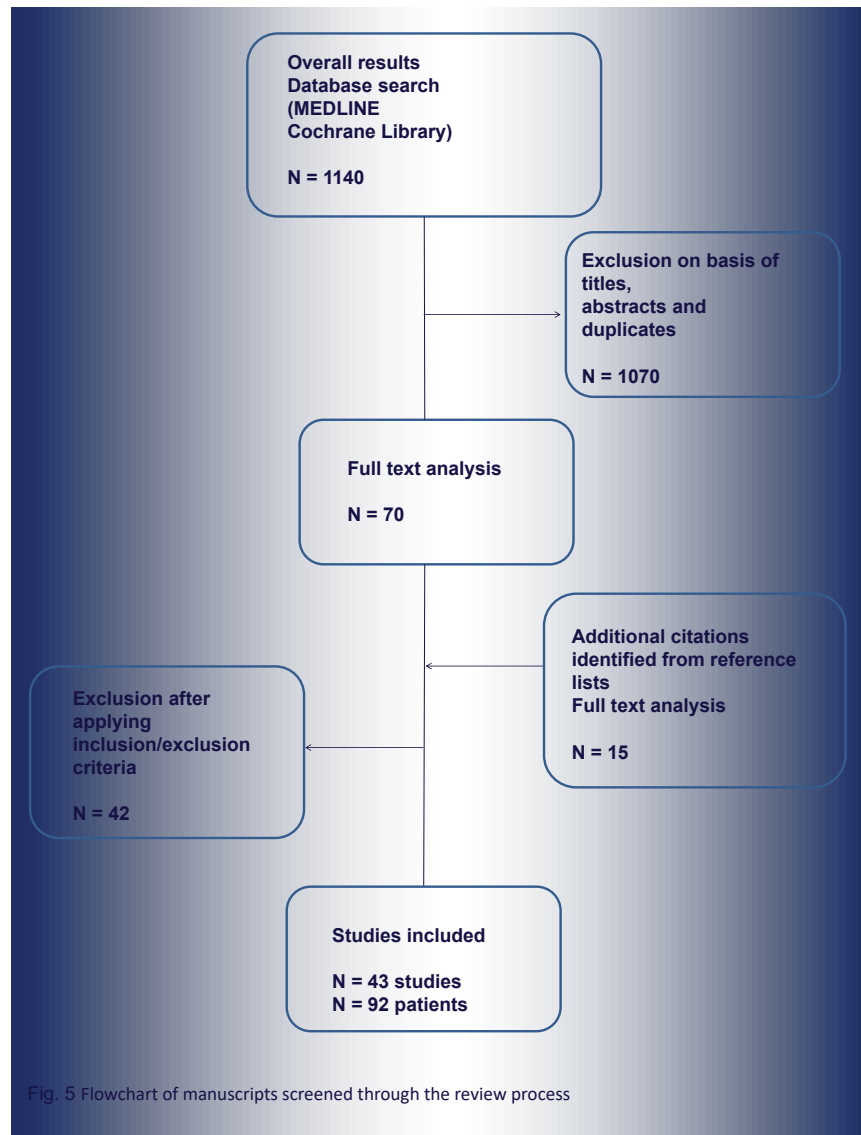


Fig. 5 Flowchart of manuscripts screened through the review process

### CONCLUSION

Periodontal treatment of PLS patients remains challenging. Therapy concepts that include a tooth-less period seem to have promising results in the long run. The use of adequate adjunctive antibiotics is obligatory. The success rate is strongly affected by the patients' compliance; stringent maintenance therapy, including mechanical and antibiotic re-treatment if needed, is a major determinant for preserving permanent teeth in these patients.

Long-term results are limited in the literature. Further monitoring of the published patients or new controlled studies with higher patient numbers and long-term observation are necessary for the evaluation of the described therapeutic protocols.