

Oral tumors and tumor-like lesions in Yemeni Elderly attending Outpatient Dental Clinic: A Preliminary Assessment

Authors: Sadeq A Al-Maweri^{1,2}, Ousamah AlMasri¹

¹Departement of Oral Medicine, Al-Farabi Colleges, Riyadh, Saudi; ²Sana'a University, Yemen

Introduction

Worldwide, the elderly person demographic is growing faster than that of any other age group. Approximately 600 million people are aged 60 years and older, and this number will double by 2025. Older persons are at risk of chronic diseases of the mouth, including dental infections, mucosal lesions, benign tumors, and oral cancer. The prevalence of lesions affecting the oral mucosa is an important parameter in evaluating the oral health of elders,^[5] and its assessment is important for government decisions regarding health programs.

Objectives

To document the most common oral mucosal lesions (OMLs) with a particular emphasis on tumors and tumor-like lesions among Yemeni elderly attending outpatient dental clinic.

Methods

This cross-sectional study involved 101 elderly individuals, who attended outpatient dental clinics at Sana'a university, Yemen. The participants were interviewed for socioeconomic status, oral risk habits, oral hygiene practices, systemic health, and history and current use of medications. A single examiner performed detailed oral examinations of the oral cavity according to international criteria and the World Health Organization codes.

Results

The mean age of the participants was 64.89 years. A total of 54.5% of the participants were Khat chewers and 23.8% were smokers. A total of 67.3% of the participants were diagnosed with at least one OML. The most common lesions were fissured tongue (38.6%), tumor and tumor-like lesions (20.8%) and Khat-associated white lesion (5.9%). The frequency of tumor and tumor-like lesions was significantly higher among smokers (45.8%) than none- and/or ex-smokers ($P < 0.01$). Likewise, the frequency of oral tumors was also higher in males than females and among Khat-chewers than none chewers, though this was not statistically significant.

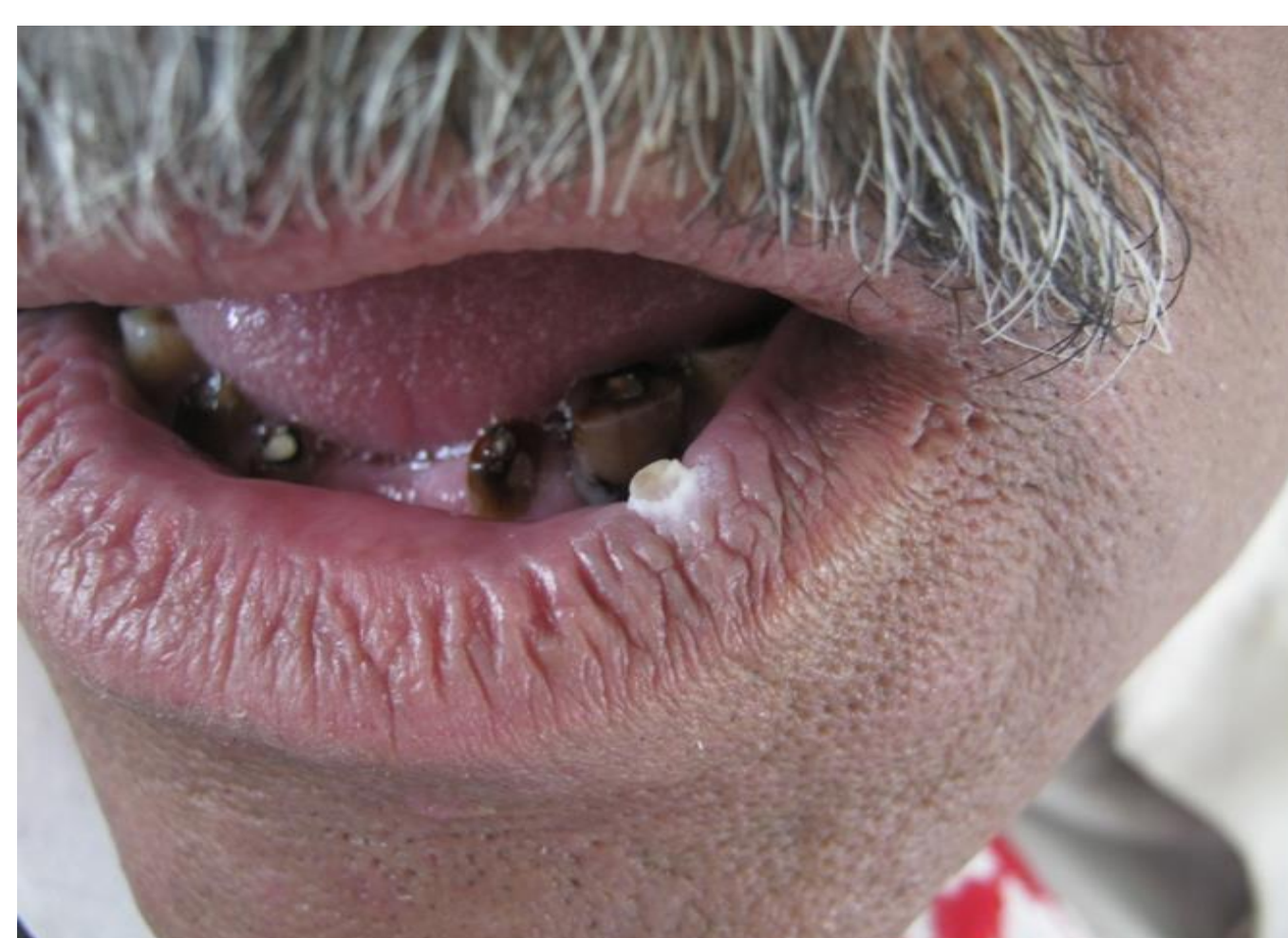

Figure 1: Papilloma

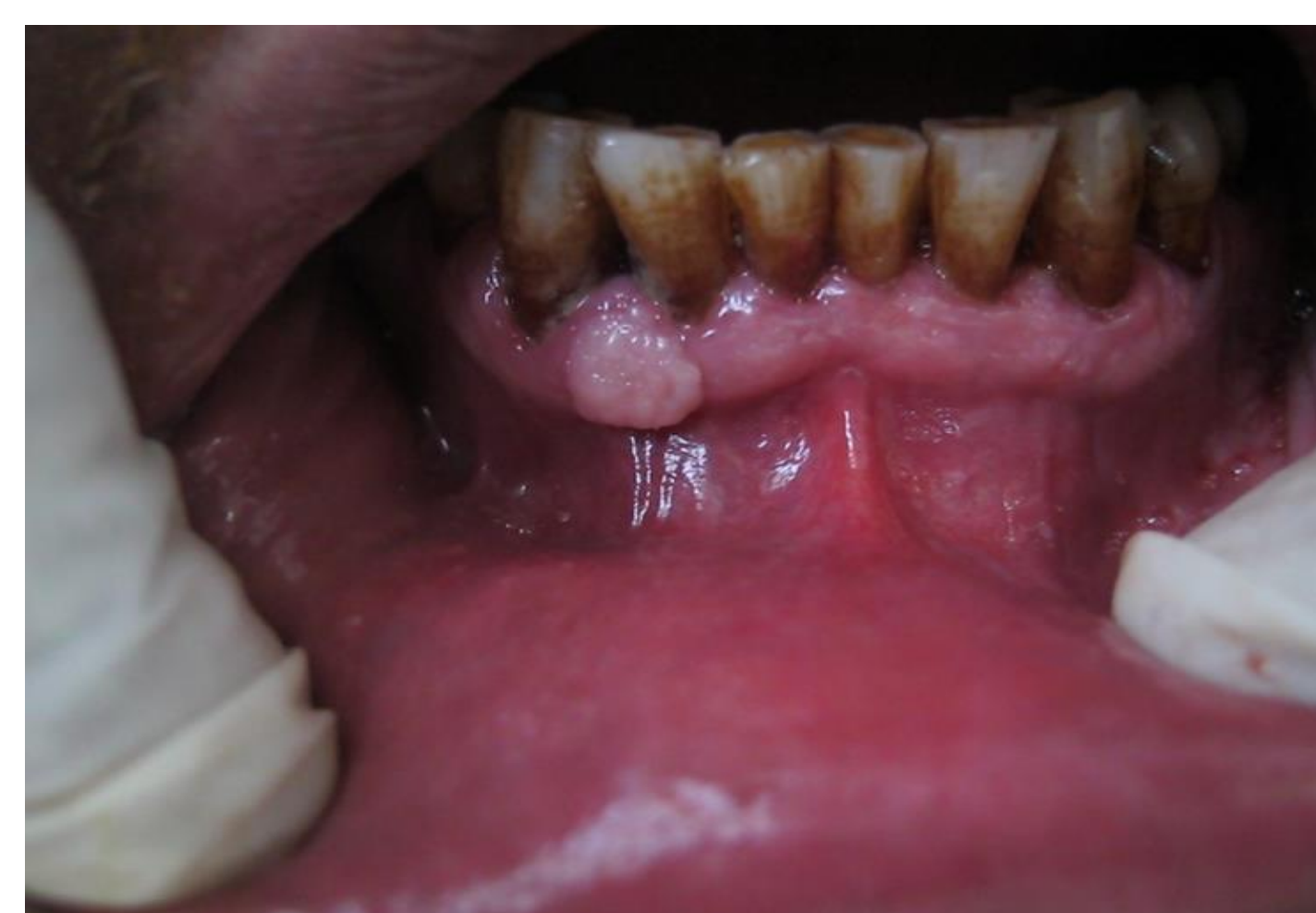

Figure 2: Gingival epulis

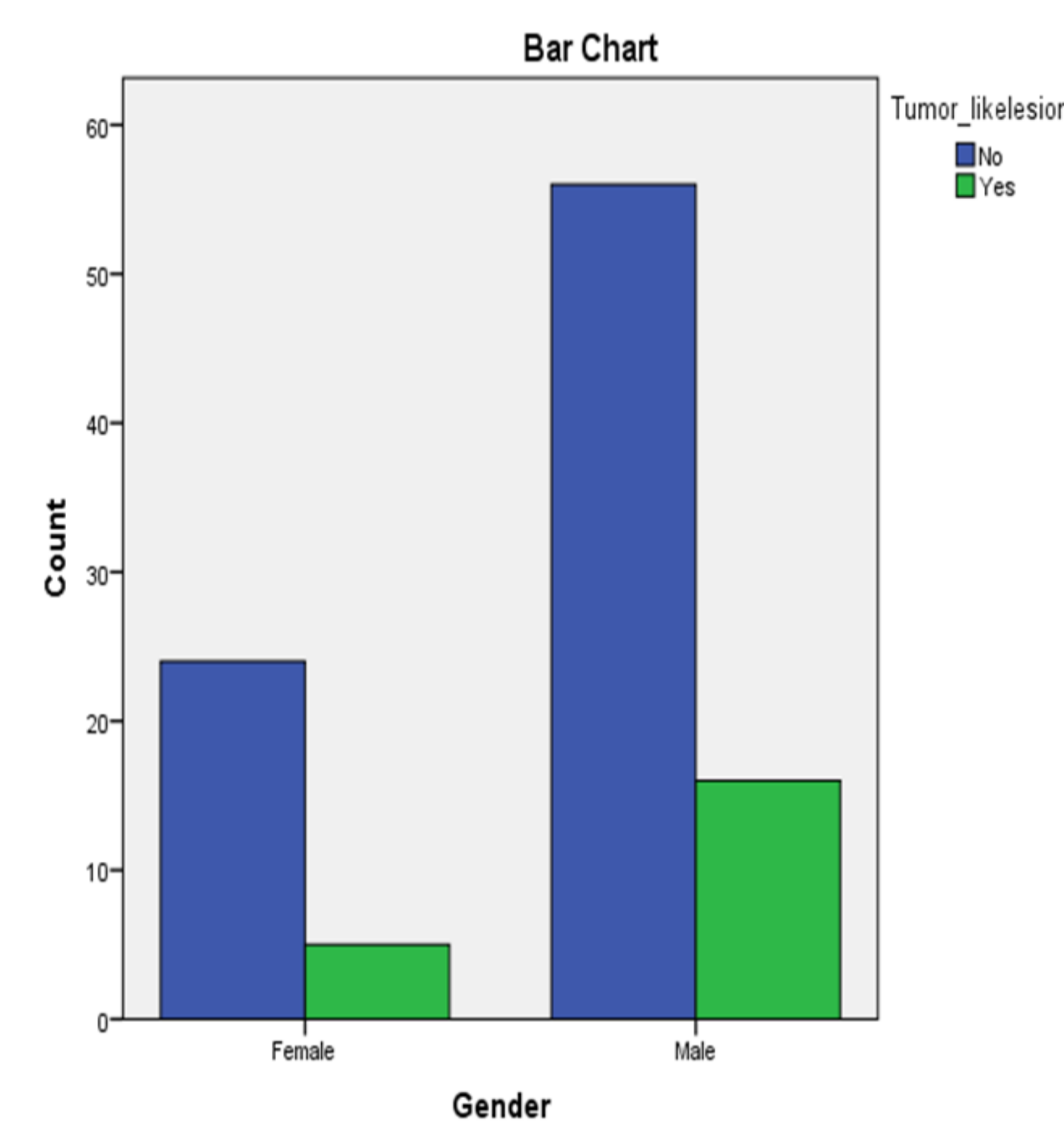


Figure 3: Oral tumors by gender

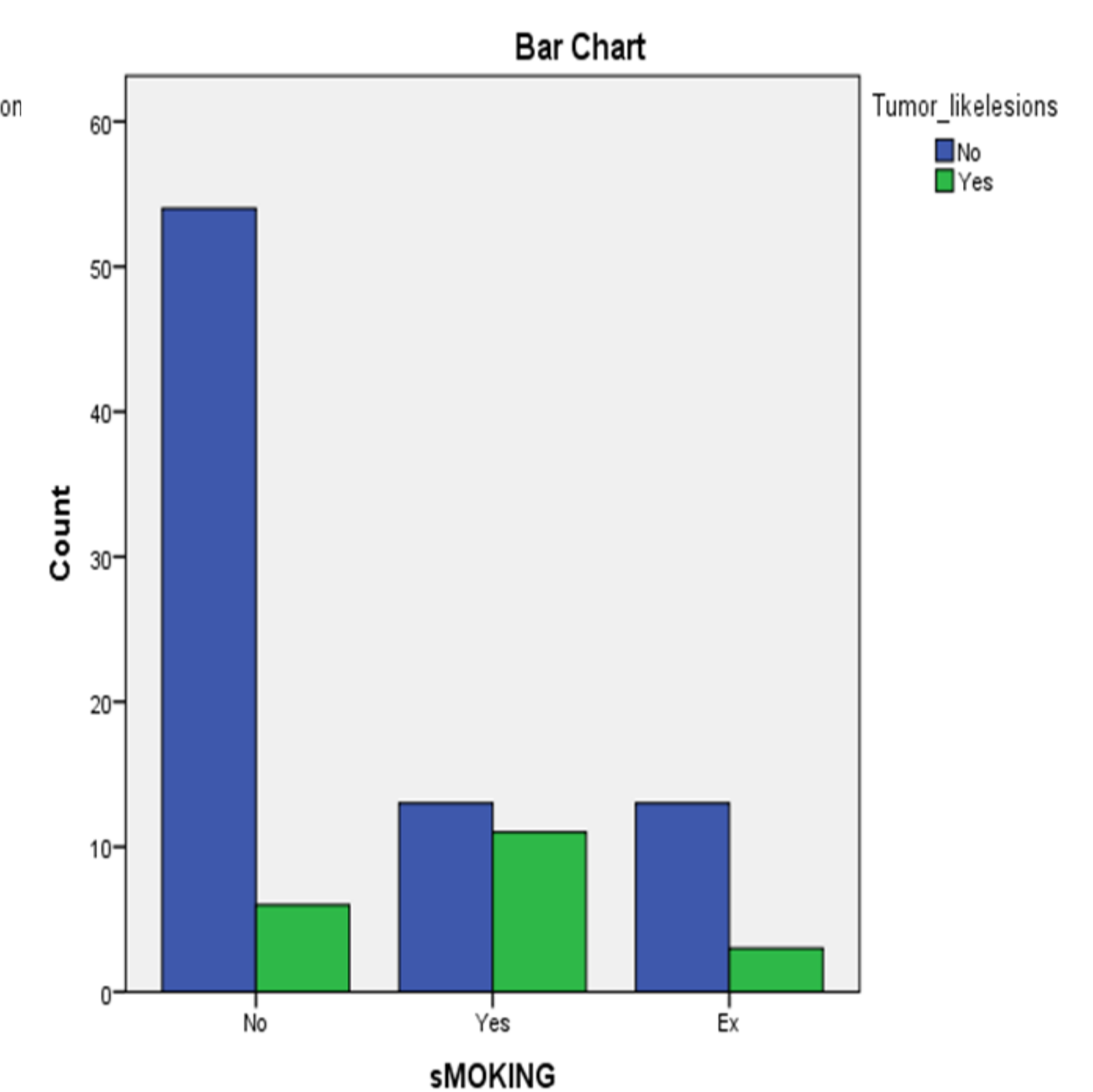


Figure 4: Oral tumors by smoking status

Table 1: Frequency & proportion of OMLs

Oral Lesions	N= 101	
	N	%
Fissured tongue	39	38.9
Hairy tongue	13	12.9
Atrophic tongue	5	5
Benign Tumors	21	20.8
Traumatic	5	5
Khat-induced lesion	6	5.9
Shammah keratosis	2	2
Lichen Planus	2	2
Angular cheilitis	4	4
One or more lesions	68	67.3

Discussion and Conclusions

In this study 67.3% of the elderly were found to have one or more OMLs, a finding that is slightly higher than the results of other epidemiological studies.

Furthermore, the prevalence of oral tumors and tumor-like lesion in our study (20.8%) was conspicuously higher than the results of other previous studies.

These variations may be from differences in the subjects studied, oral habits, and the types of oral mucosal conditions included.

The present authors also found an association between OMLs including oral tumors and deleterious oral habits, which is in line with previous studies.

Due to high prevalence of oral mucosal lesions in elderly patients, interceptive and preventive measures should be planned as early as possible.

References

- Atashrazm P, Sadri D. Prevalence of oral mucosal lesions in a group of Iranian dependent elderly complete denture wearers. *J Contemp Dent Pract* 2013;14:174-8.
- World Health Organization. *Active Ageing: A Policy Framework*. Geneva, Switzerland: World Health Organization (WHO); 2002.
- Petersen PE, Yamamoto T. Improving the oral health of older people: The approach of the WHO Global Oral Health Programme. *Community Dent Oral Epidemiol* 2005;33:81-92.
- Cueto A, Martínez R, Niklander S, Deichler J, Barraza A, Esguep A. Prevalence of oral mucosal lesions in an elderly population in the city of Valparaiso, Chile. *Gerodontology* 2013;30:201-6.
- Jainkittivong A, Aneksuk V, Langlais RP. Oral mucosal conditions in elderly dental patients. *Oral Dis* 2002;8:218-23.
- Al-Maweri, S. A., Alaizari, N. A., & Al-Sufyani, G. A. (2014). Oral mucosal lesions and their association with tobacco use and qat chewing among Yemeni dental patients. *J Clin Exp Dent*, 6(5), e460-466.