

Introduction

The most frequent location to restore edentulous areas with implant supported prosthesis is the maxillary and mandibular posterior sites. In these areas, the ideal placement of dental implant from a restorative-driven concept, is often limited due to anatomic structures (maxillary sinus, inferior alveolar nerve, mental foramen) or limited bone availability. These situations entail the clinicians to perform guided bone regeneration techniques, such as open/closed sinus elevations, inferior alveolar nerve transpositions or even vertical ridge augmentations.

Objectives

The aims of this study were:

- To assess the survival of 32 implants placed in the posterior maxilla, where the bone availability (apico-coronal) measured from the bone crest to the floor of the maxillary sinus was ≤ 5 mm, during and observational period of 18 months.
- To measure the amount of newly bone formed spontaneously, **without any bone grafting**, around the apex of the implants, which after surgery are located apically to the cortical of the initial sinus floor.
- To assess the stability of newly formed bone ("Slumping", bone graft resorption) at 18 months.

Material and methods

- Thirty two (32) consecutive patients who come to San Rafael Hospital, to rehabilitate one or more teeth in the posterior maxilla using implants, having a bone availability at less than or equal to 5 mm maxillary sinus.
- Camlog implant system was used. The implants used were: 4.3 x 9/11 mm (18,7%) 5 x 9 mm ((81,3%).
- Radiographic study of newly formed bone around the apex without the use of biomaterials.

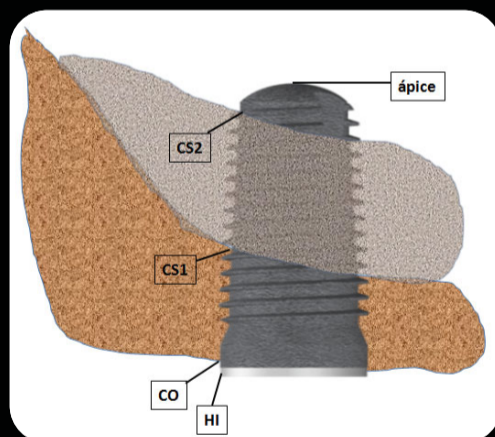
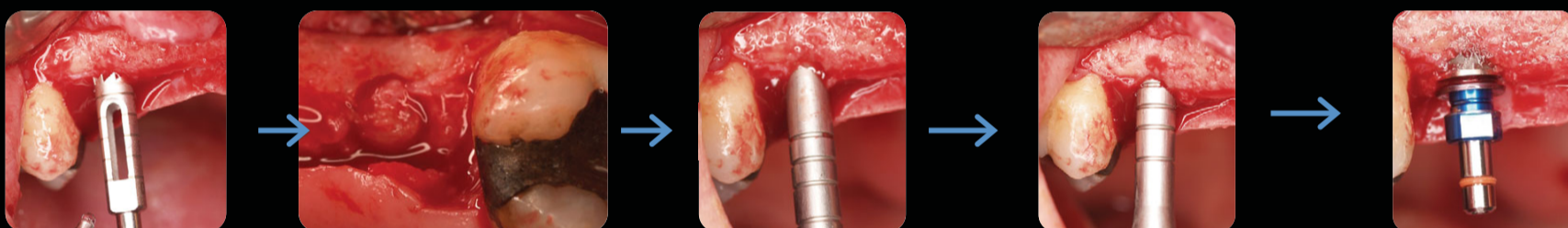Inclusion Criteria

- > 18 years
- residual bone height ≤ 5 mm
- Informed Consent
- Absence of partial removable denture in the implant area
- Socket healing > 4 months

Exclusion Criteria (Local factors)

- Sinus pathology
- Unhealed alveoli (<4 months)
- Residual bone height > 5 mm
- Underwood septa
- "Drop outs"
- Presence of partial removable denture in the implant area

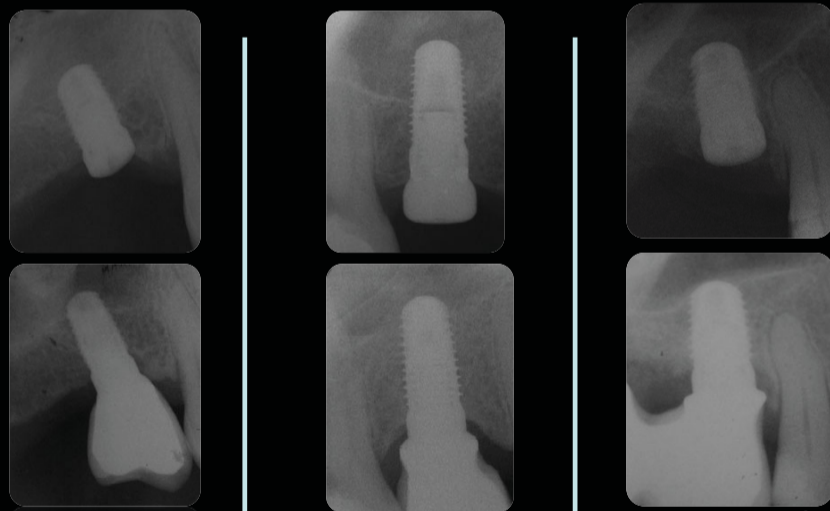
Surgical sequence and postop measurements



Study landmarks

- HI : Implant shoulder
- CO: Osseous crest
- CS1: Initial cortical sinus floor
- Ápice: Implant apex
- CS2: New cortical sinus

12 months



12 months

Results

Thirty two tapered implants were placed were loaded after a mean of 4.2 +/- 1.6 months. The mean maxillary residual bone height was 3.6 +/- 1.2 mm. All implants achieved primary stability, and all were successfully loaded (**100% survival rate**).

At the 18 month radiographic control, the mean **bone gain** within the sinus was 3.89 +/- 1.3 mm.

Eight cases tested positive for Valsalva maneuver but still achieved **100% survival**.

The mean gain on the mesial side of the implant was 4mm vs the mean gain on the distal surface was 3.67mm (SS).

The crestal bone resorption from baseline to 18 months was 0.8mm.

Conclusions

The placement of implants in the posterior maxilla where there is a bone availability equal to or less than 5 mm is predictable.

- No differences in terms of implant survival was found when this technique is compared with the results observed in studies placing implants by the conventional technique.
- Elevation of the sinus membrane without the addition of bone grafting material led to bone formation beyond the original limit of the sinus floor.
- In all cases spontaneous bone formation around the apex of the implant (3.89 mm on average) and was stable over time.
- Due to the results obtained in this study, which has obtained a spontaneous bone regeneration has been reduced by almost 50% the time of treatment and the cost to the patient and less painful and troublesome postoperative propose this technique as a treatment of choice for implant placement in the atrophic posterior maxilla.

References

- Nedir R, Nurdin N, Khoury P, Perneger T, Hage ME, Bernard JP, et al. Osteotome sinus floor elevation with and without grafting material in the severely atrophic maxilla. A 1-year prospective randomized controlled study. Clin Oral Implants Res 2012 Aug 27.
- Summers RB. A new concept in maxillary implant surgery: the osteotome technique. Compendium 1994 Feb;15(2):152-6
- Fugazzotto PA. The modified trephine/osteotome sinus augmentation technique: technical considerations and discussion of indications. Implant Dent 2001;10(4):259-264.
- Boyne PJ, James RA. Grafting of the maxillary sinus floor with autogenous marrow and bone. J Oral Surg 1980 Aug;38(8):613-616.