

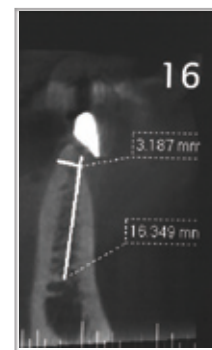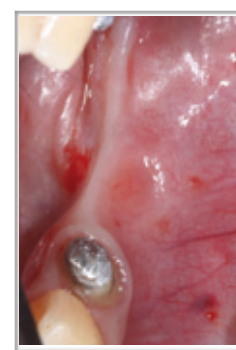
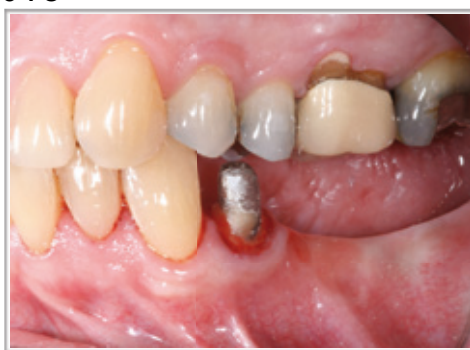Posterior horizontal augmentation in a knife edge ridge utilizing the "sausage" technique. Case report

International Symposium Osteology Monaco May 2-4 2013

Roberto Mejia. DDS*

Objective

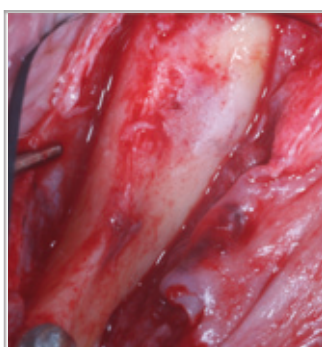
Horizontally augmentation of a deficient lower posterior ridge (knife edge) using a combination of anorganic bovine bone matrix (DBBM) with autogenous bone and native collagen membrane in order to prepare the site for future implant placement.



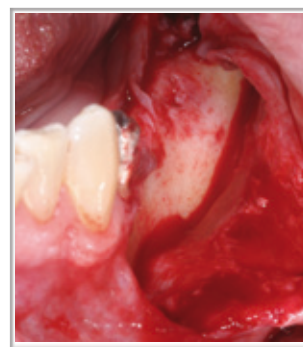Preoperative view

Materials and Methods

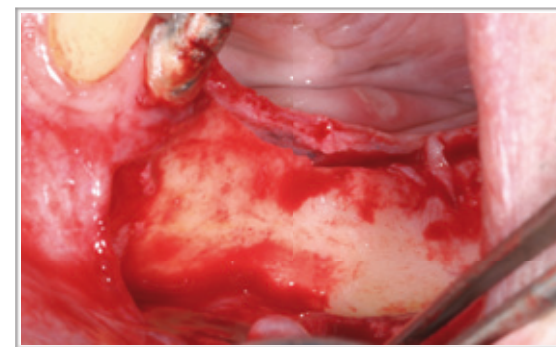
60 years old male missing teeth 35,36 and 37 for more than 20 years. CBCT scan showed good height but only 3 mms width contraindicating implant placement. Procedure included full thickness flap, isolation of mental foramen, cortical perforation for angiogenesis, autogenous bone scraped from external oblique ridge combined with DBBM (Bio-Oss®) 1:1 ratio. Stabilization of bone graft was performed using a porcine natural collagen membrane (Bio-Gide®) with bone tacks and flaps released and closed with Cytoplast® suture. Sutures were removed after 12 days. Patient was pre-medicated with amoxicillin 2 g one hour before surgery and 500 gms penicillin three times a day for one week following the surgery and anti inflammatories for 5 days combined with chlorhexidine mouth wash for two weeks. No appliance was worn by the patient during treatment.



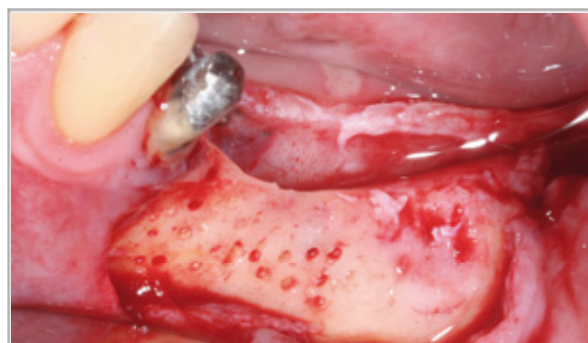Occlusal view



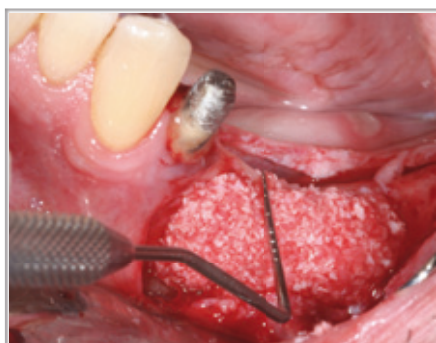Isolation of mental foramen



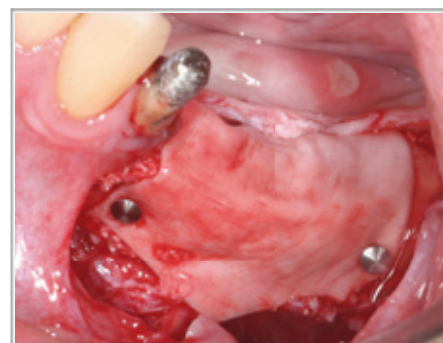Buccal and lingual flap release



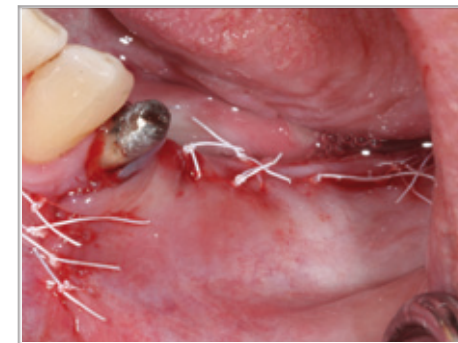Decortication for angiogenesis



Autogenous bone mixed with Bio-Oss® in 1:1 ratio



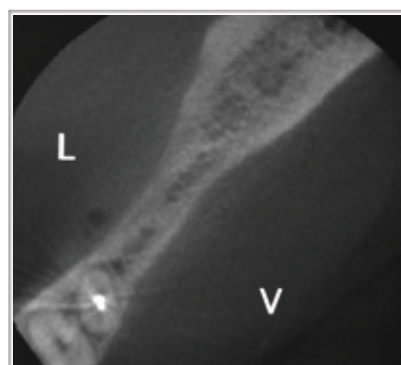Bio-Gide® membrane fixed with bone tacks



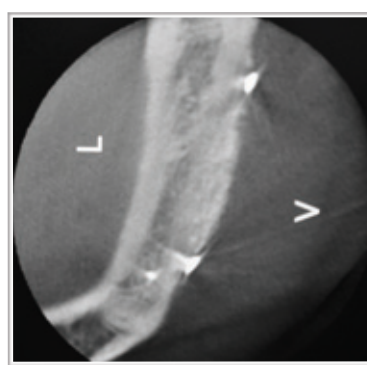Non tension flap closure with 4:0 Cytoplast® suture using mattress and single interrupted sutures

Results

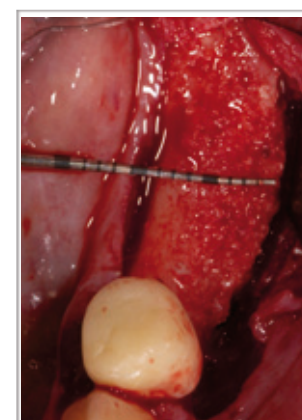
Nine months after bone regeneration, a new CBCT scan showed a horizontal bone gain of 6 mms for a total of 9 mms width. Three Biohorizons® taper implants were placed with no complication on a vascularized and hard bone tissue replacing teeth 35,36 and 37.



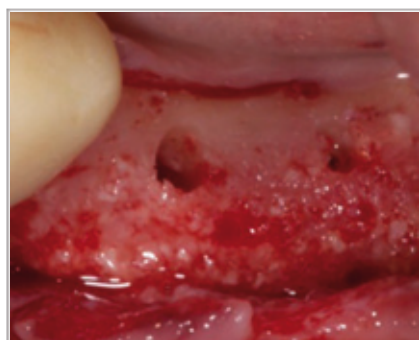Preoperative view



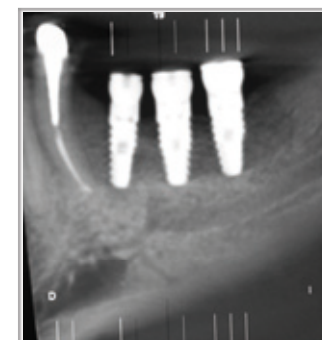
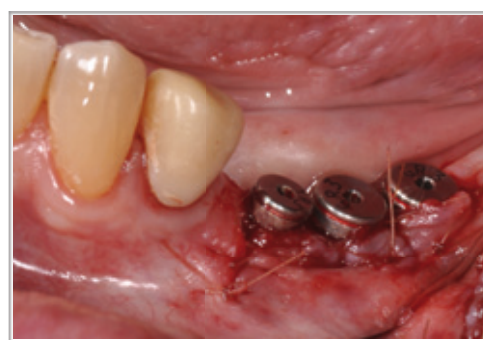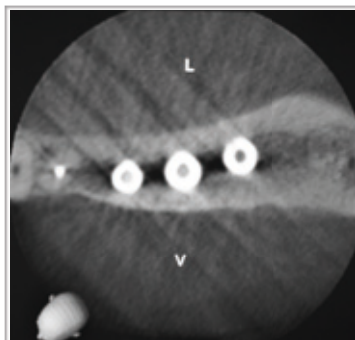
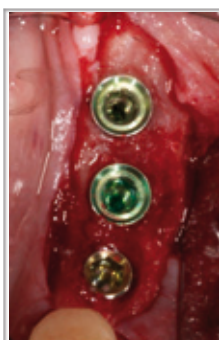Post operative view after 9 months



Occlusal view of new bone ridge



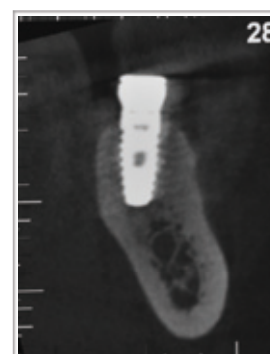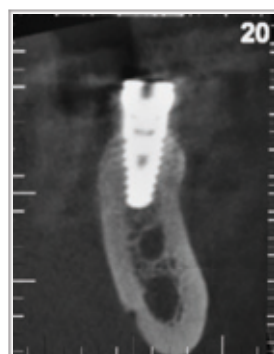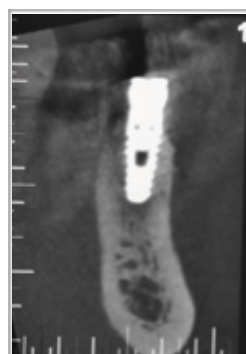
Clinical view of new bone formation



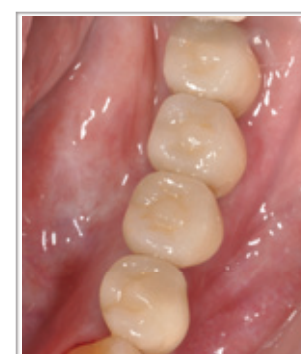One 3.8 x 10.5 mms Biohorizons® implant and two 4.6 x 10.5 mms Biohorizons® implants in position. Clinical and radiographic views.

Conclusions

The treatment of horizontally deficient alveolar ridges with the GBR technique using autogenous bone mixed with ABBM and a natural collagen resorbable barrier membrane can be regarded as succesful. The osteogenics properties of the autogenous bone, the low resorption rate and osteoconductive properties of the ABBM and the physical properties of a native porcine collagen membrane contribute in the survival of the bone graft.



CBCT showing amount of bone surrounding each implant after 14 months of bone regeneration



Final crowns

1. Rothamel D, Schwarz F, Sculean A, Herten M, Scherbaum W, Becker J. Biocompatibility of various collagen membranes in cultures of human osteoblast-like cells. Clin Oral Implants Res. 2004;14(4):443-9
2. Hammerle CHF, Jung RE, Yaman D, Lang NP. Ridge augmentation by applying bioresorbable membranes and deproteinized bovine bone mineral: A report of twelve consecutive cases. Clin Oral Impl Res 2008;19:19-25
3. Urban IA, Nagursky H, Lozada JL. Horizontal ridge augmentation with a resorbable membrane and particulated autogenous bone with or without anorganic bovine bone-derived mineral: A prospective case series in 22 patients. Int J Oral Maxillofac Implants 2011;26(2):404-14.
4. Urban IA, Nagursky H, Lozada JL, Nagy K. Horizontal ridge augmentation with a collagen membrane and a combination of particulated autogenous bone and anorganic bovine bone-derived mineral: A prospective case series in 25 patients. Int J Periodontics Restorative Dent 2013;33:299-307

* Specialist Periodontal Prosthesis CES University Medellin, Colombia. Master Clinician in Implant Dentistry gIDE/UCLA Los Angeles, California. Private Practice Medellin, Colombia. mejia697@hotmail.com