

A digital technique for Smile Analysis and Design-digital mock-up

Language: English

Authors:

Dr. Ana Petre,

Oral Rehabilitation Department, University of Medicine and Pharmacy Carol Davila, Bucharest, Romania

Dr. Cosmin Circu,

Oro-dental Prevention Department, Faculty of Dentistry, University of Medicine and Pharmacy Carol Davila, Bucharest, Romania

Date/Event/Venue:

June 16-18, 2011

International Dental Congress "Timmedica"

Timisoara, Romania

Introduction

Using the general criteria of "beauty", experts in Dental Aesthetic have succeeded in standardization of the characteristics of "the perfect smile" with all its components: lips, attached gingiva and teeth. Each of them has a few variables that must be analyzed and corrected in order to achieve the "perfect smile"[1]. Usually, we achieve this goal by an analogue analysis of patient's clinical features, but nowadays, due to the continuous evolution of Dentistry, dental treatments have to involve some digital features. The availability of digital photography permits digital estimation of existing smile features and an easier way of planning the dental treatment, actually we are able to obtain a "digital mock-up".

Objectives

Our aim is to provide a simple digital method that could ease and specify the Smile Correction Protocol. Due to this technique, the doctor is able to send to the dental technician just the "blue-prints" of the patient's "new smile".

Material and Methods

The Aesthetic Smile Criteria [2] and usual software were used for this process developing. To exemplify the technique, we present a clinical case with one right lateral upper incisor in malposition due to a small mesio-buccal rotation and a lingual inclination (Fig. 1). The digital picture of smile area that must be restored is opened with Microsoft Power Point® or similar software. The patient's photo must be checked if is well orientated in both, horizontal and vertical axis - blue lines: facial midline parallel with vertical axis and incisal curvature symmetric to horizontal one. Small rotations can be fixed with draw tools. "Line" and "curvature" tools (Fig. 2) are used to mark midline and respectively incisal curvature - red lines (Fig. 3). The marked image is all selected and "group". The new image can be rotated using "rotation" tool until the red lines are parallel with blues ones (Fig. 4). In the next step we have to "ungroup" the ensemble and delete the lines red and blue. The image is saved as pictures and after that the crop tool resizes the picture in correct position (Fig. 5). Further, the final picture (Fig. 6) is inserted into a new slide and with "freeform" tool (Fig. 7) we copy the shape of the other lateral incisor, which is in right position (Fig. 8). The newly created form is duplicated (Fig. 9) and positioned after "horizontal flip" (Fig. 10) over the image of right upper lateral incisor (Fig. 11). Filled form shows us the ideal shape of the lateral incisor and the marginal line gives us information about its ideal contour (Fig. 12). Finally, both images are saved as pictures and analyzed.

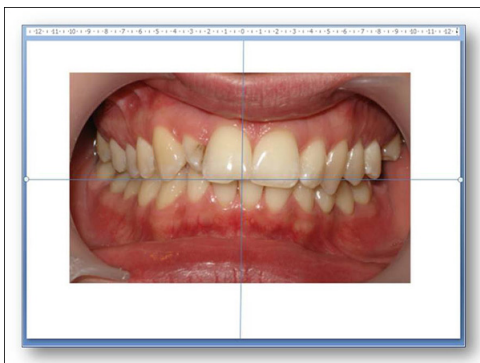


Fig. 1: Initial patient's photo

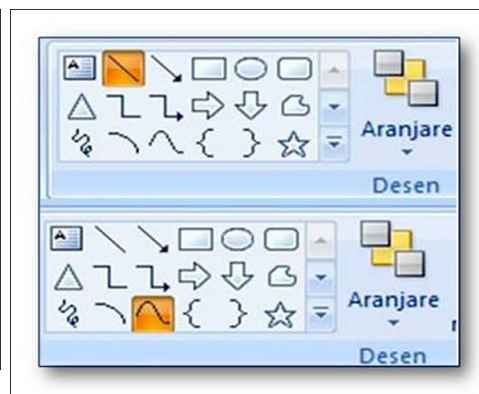

Fig. 2: Line and curvature tools

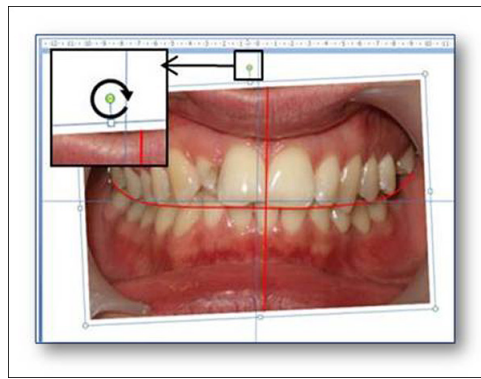
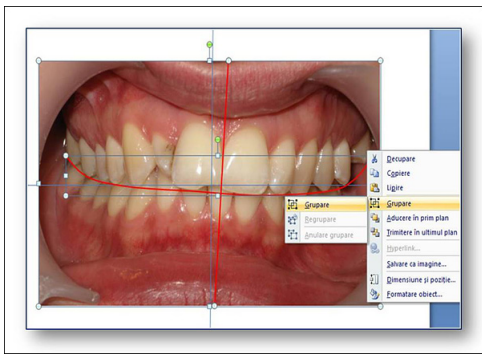


Fig. 3: Midline and incisal curvature

Fig. 4: Rotation tool

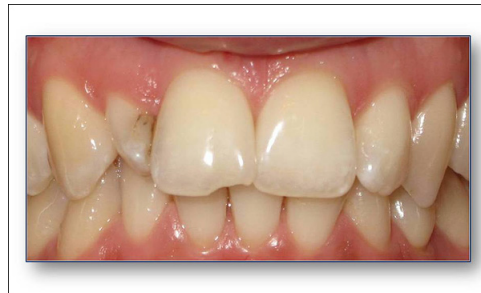
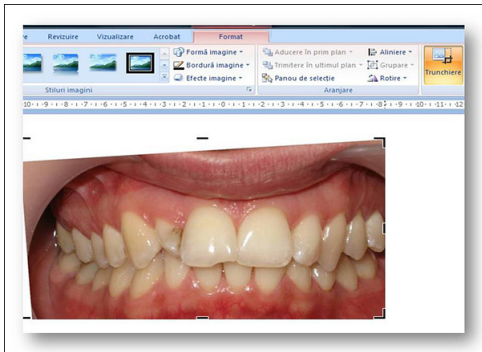
Fig. 5: Crop tool

Fig. 6: Final pictures

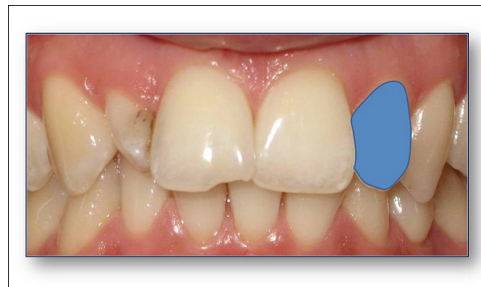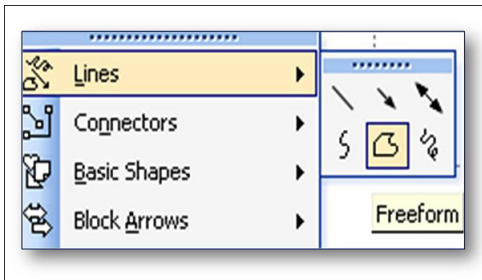


Fig. 7: Freeform tool

Fig. 8: Filled form

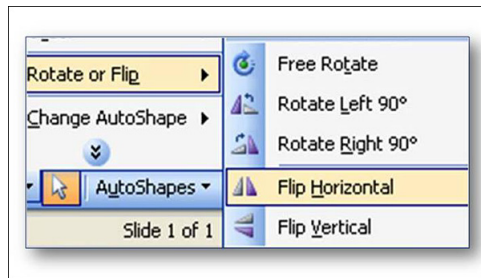
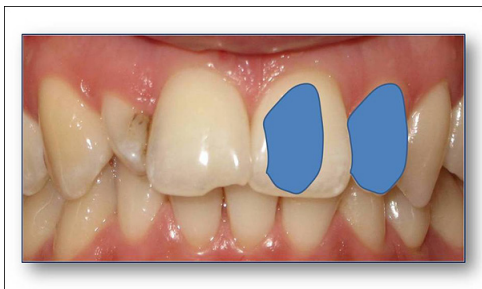

Fig. 9: Duplicated form

Fig. 10: Flip tool

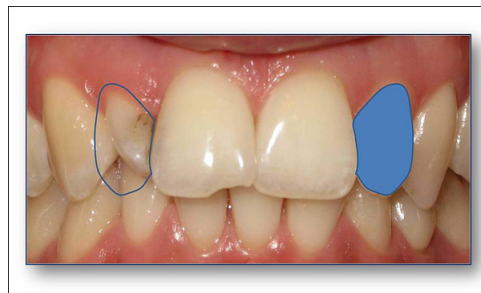
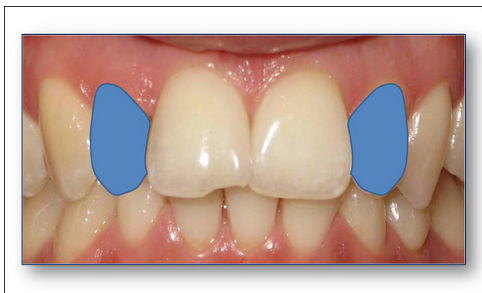

Fig. 11: First shape copied end horizontal flipped

Fig. 12: The ideal contour of lateral right incisor

Results

Some of worldwide accepted aesthetic criteria [3] are used to analyze the smile: facial midline, gingival embrasures, dental axis, gingival zenith, gingival contour, contact points position, incisal edge line and incisal curvature. All these elements have to be symmetrical to midline and horizontal line (Fig. 13).

In this particular clinical case, we can observe that, due to the modified position, the appearance of 12 is different from its homologue. The gingival contour is situated in a lower position and the visible contour is significantly smaller affecting the incisal and buccal curvature.

Regarding to "digital mock-up", in this simple way we can observe the changes we have to operate in order to obtain an aesthetic smile: small gingival recontouring and a ceramic veneer with shape similar to 22. This technique would improve the communication with technicians who usually build the wax-up on gyps model without any clinical information. By sending these pictures to dental technician we provide very important and exact information about patient's clinical features.

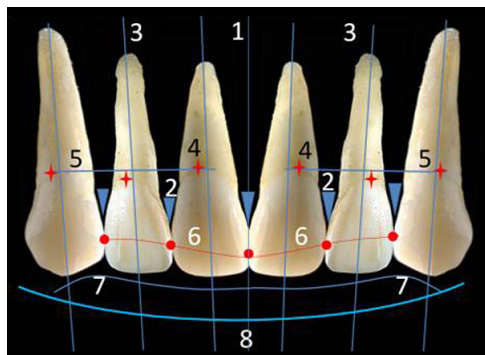


Fig. 13: The facial midline (1), the gingival embrasures (2), the tipping of dental axis (3), the gingival zenith (4), the gingival contour (5), the contact points(6), the incisal edge line (7), the incisal curvature (8)

Conclusions

The utilization of computer in Smile Design process permits us to achieve better results from aesthetic treatments. The Digital Smile Analysis process is less difficult and more accurate. All the information are easily stored, processed and archived. Moreover we can avoid any misunderstanding that may occur during the communication with the dental laboratory.

Literature

1. Geissberger M., Esthetic Dentistry in Clinical Practice, Wiley- Blackwell, Ames 2010, ISBN:0813828252:9-17
2. Levin El., Dental esthetics and the golden proportion, J Prosthet Dent. 1978 Sept; 40(3):244-52
3. Magne P, Belser U, Restauraciones de Porcelana Adherida en los Dientes Anteriores: Método Biomimético, Editorial Quintessence, S.I., Barcelona, 2004:70-2

This Poster was submitted by Dr. Ana Petre.

Correspondence address:

Dr. Ana Petre
University of Medicine and Pharmacy Carol Davila
Oral Rehabilitation Department
31, Anton Pann Str.
Bucharest
Romania



A digital technique for Smile Analysis and Design Digital mock-up

Dr. Ana PETRE¹, Dr. C. CÎRCLU²

¹ Oral Rehabilitation Department, ² Oro-dental Prevention Department
University of Medicine and Pharmacy "Carol Davila", Faculty of Dentistry, Bucharest, Romania

Introduction: Using the general criteria of "beauty", experts in Dental Aesthetic have succeeded in standardization of the characteristics of "the perfect smile" with all its components: lips, attached gingiva and teeth. Each of them has a few variables that must be analyzed and corrected in order to achieve the "perfect smile"[1]. Usually, we achieve this goal by an analogue analysis of patient's clinical features, but nowadays, due to the continuous evolution of Dentistry, dental treatments have to involve some digital features. The availability of digital photography permits digital estimation of existing smile features and an easier way of planning the dental treatment, actually we are able to obtain a "digital mock-up".

Aim and objectives: Our aim is to provide a simple digital method that could ease and specify the Smile Correction Protocol. Due to this technique, the doctor is able to send to the dental technician just the "blue-prints" of the patient's "new smile".

Material and Method: The Aesthetic Smile Criteria [2] and usual software were used for this process developing.

To exemplify the technique, we present a clinical case with one right lateral upper incisor in malposition due to a small mesio-buccal rotation and a lingual inclination (Fig.1).

The digital picture of smile area that must be restored is opened with Microsoft Power Point® or similar software. The patient's photo must be checked if it is well orientated in both, horizontal and vertical axis - blue lines: facial midline parallel with vertical axis and incisal curvature symmetric to horizontal one. Small rotations can be fixed with draw tools. "Line" and "curvature" tools (Fig.2) are used to mark midline and respectively incisal curvature - red lines (Fig.3). The marked image is all selected and "group". The new image can be rotated using "rotation" tool until the red lines are parallel with blue ones (Fig.4). In the next step we have to "ungroup" the ensemble and delete the lines red and blue. The image is saved as pictures and after that the crop tool resizes the picture in correct position (Fig.5). Further, the final picture (Fig.6) is inserted into a new slide and with "freeform" tool (Fig.7) we copy the shape of the other lateral incisor, which is in right position (Fig.8). The newly created form is duplicated (Fig.9) and positioned after "horizontal flip" (Fig.10) over the image of right upper lateral incisor (Fig.11). Filled form shows us the ideal shape of the lateral incisor and the marginal line gives us information about its ideal contour (Fig.12). Finally, both images are saved as pictures and analyzed.

Fig. 1 Initial patient's photo

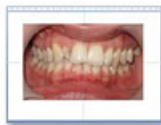

Fig. 1 Initial patient's photo

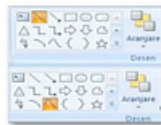

Fig. 2 Line and curvature tools

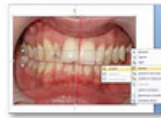

Fig. 3 Midline and incisal curvature

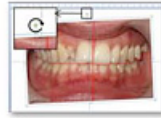

Fig. 4 Rotation tool

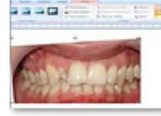

Fig. 5 Crop tool

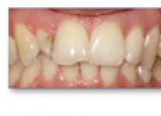

Fig. 6 Final picture

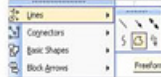


Fig. 7 Freeform tool

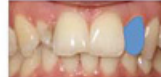

Fig. 8 Filled form

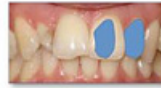

Fig. 9 Duplicated form

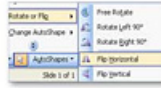


Fig. 10 Flip tool

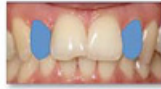

Fig. 11 First shape copied end horizontally flipped

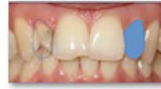

Fig. 12 The ideal contour of lateral right incisor

Results and discussions: Some of worldwide accepted aesthetic criteria [3] are used to analyze the smile: facial midline, gingival embrasures, dental axis, gingival zenith, gingival contour, contact points position, incisal edge line and incisal curvature. All these elements have to be symmetrical to midline and horizontal line (Fig.13).

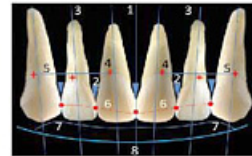


Fig. 13. The facial midline (1), the gingival embrasures (2), the tipping of dental axis (3), the gingival zenith (4), the gingival contour (5), the contact points (6), the incisal edge line (7), the incisal curvature (8)

In this particular clinical case, we can observe that, due to the modified position, the appearance of 12 is different from its homologue. The gingival contour is situated in a lower position and the visible contour is significantly smaller affecting the incisal and buccal curvature.

Regarding to "digital mock-up", in this simple way we can observe the changes we have to operate in order to obtain an aesthetic smile: small gingival recontouring and a ceramic veneer with shape similar to 22. This technique would improve the communication with technicians who usually build the wax-up on gypsum model without any clinical information. By sending these pictures to dental technician we provide very important and exact information about patient's clinical features.

Conclusions: The utilization of computer in Smile Design process permits us to achieve better results from aesthetic treatments. The Digital Smile Analysis process is less difficult and more accurate. All the information are easily stored, processed and archived. Moreover we can avoid any misunderstanding that may occur during the communication with the dental laboratory.

Bibliography

- Geissberger M., Esthetic Dentistry in Clinical Practice, Wiley- Blackwell, Ames 2010, ISBN 0813828252 9-17
- Levin E., Dental esthetics and the golden proportion, J Prosthet Dent, 1978 Sept, 40(3):244-52
- Magne P., Belsier U., Restauraciones de Porcelana Adherida en los Dientes Anteriores Método Biomimético, Editorial Quintessence, S.L, Barcelona, 2004:70-2

Contact Dr. Ana Petre
ana.petre@dental-studio.ro