

Subepithelial Connective Tissue Grafts to Improve Tissue Biotype Control in Peri-implant Disease: A Case Series

Peng LI¹, De Li LI¹, Hua Allen CHEN², Zhi Hui TANG¹

Three patients diagnosed with peri-implant disease after osseointegration exhibited soft tissue oedema and fistulae. Treatment options for controlling the fistulae were investigated. Free subepithelial connective tissue grafts (SCTGs) and microinvasive surgery were used to improve the soft tissue biotype of the patients with fistulae. After SCTG surgery, the fistulae disappeared. The clinical outcomes were stable and aesthetic outcomes were satisfactory after 3–5 years of follow-up. Based on this study, utilising SCTG to improve the tissue biotype may be an effective clinical approach for controlling fistulae occurring during peri-implant disease.

Key words: connective tissue, follow-up, microinvasive surgery, peri-implant disease, tissue biotype

Chin J Dent Res 2020;23(2):151–156; doi: doi: 10.3290/j.cjdr.a44751

Peri-implant disease is an inflammatory reaction in the tissues surrounding a dental implant, characterised by the loss of supporting bone after osseointegration¹. Typical clinical signs and symptoms are bleeding on gentle probing, as well as suppuration, swelling and redness of the marginal tissues. The likelihood of peri-implant disease varies, and it is typically not accompanied by pain¹. Gingival oedema is occasionally not obvious, and a small fistula may be present without suppuration. The fistula occasionally disappears when the abutment and crown are removed, cleaned, and then reinserted. In some cases, however, this approach is not effective. An effective treatment option for fistulae must therefore be identified. This case series explores one option for the treatment of fistulae and describes the clinical outcomes after a long-term follow-up.

Clinical case reports

Case 1

A 40-year-old woman underwent extraction of the right maxillary central incisor, followed by immediate implant surgery (Certain Prevail, Biomet 3i, Palm Beach Gardens, FL, USA) (Fig 1a). Bio-Oss (Geistlich Pharma AG, Wolhusen, Switzerland) bone grafting material was placed in the gaps surrounding the implant, and a subepithelial connective tissue graft (SCTG) was harvested from the right palate and placed horizontally and sutured on the buccal site of the labial bone (Figs 1b and 1c). Three months later, osseointegration was achieved between the implant and alveolar bone. The soft tissue contour showed a good healing outcome, and the implant platform was 5 mm beneath the gingival margin with a well-healed gingival cuff (Figs 1d and 1e). A screw-retained provisional crown was made on a UCLA abutment (Fig 1f), and all occlusal contacts on this crown were removed. An “emergency profile” was created by adding a small amount of resin at the neck of the provisional crown every month, with vigorous polishing. The gingival tissue appeared healthy over the following four months. Impressions were then taken to prepare for the final restorative treatment. However, when the patient returned for placement of the final restoration, tissue oedema was observed, accompanied by a fistula (Figs 1g and 1h).

1 The Second Dental Center, Peking University School and Hospital of Stomatology, National Engineering Laboratory for Digital and Material Technology of Stomatology, Beijing Key Laboratory of Digital Stomatology, Beijing, P.R. China.

2 Department of Periodontics, University of Washington School of Dentistry, Seattle, WA, USA.

Corresponding author: Dr Peng LI, The Second Dental Center, Peking University School and Hospital of Stomatology, B5 Anli Garden, #66 Anli Road, Chao Yang District, Beijing 100101, P.R. China. Tel: 86-10-82196322; Fax: 86-10-64907970. Email: kqlipeng05420533@sina.com

This work was supported by the National Nature Science Foundation of China (Grant No: 81200784).

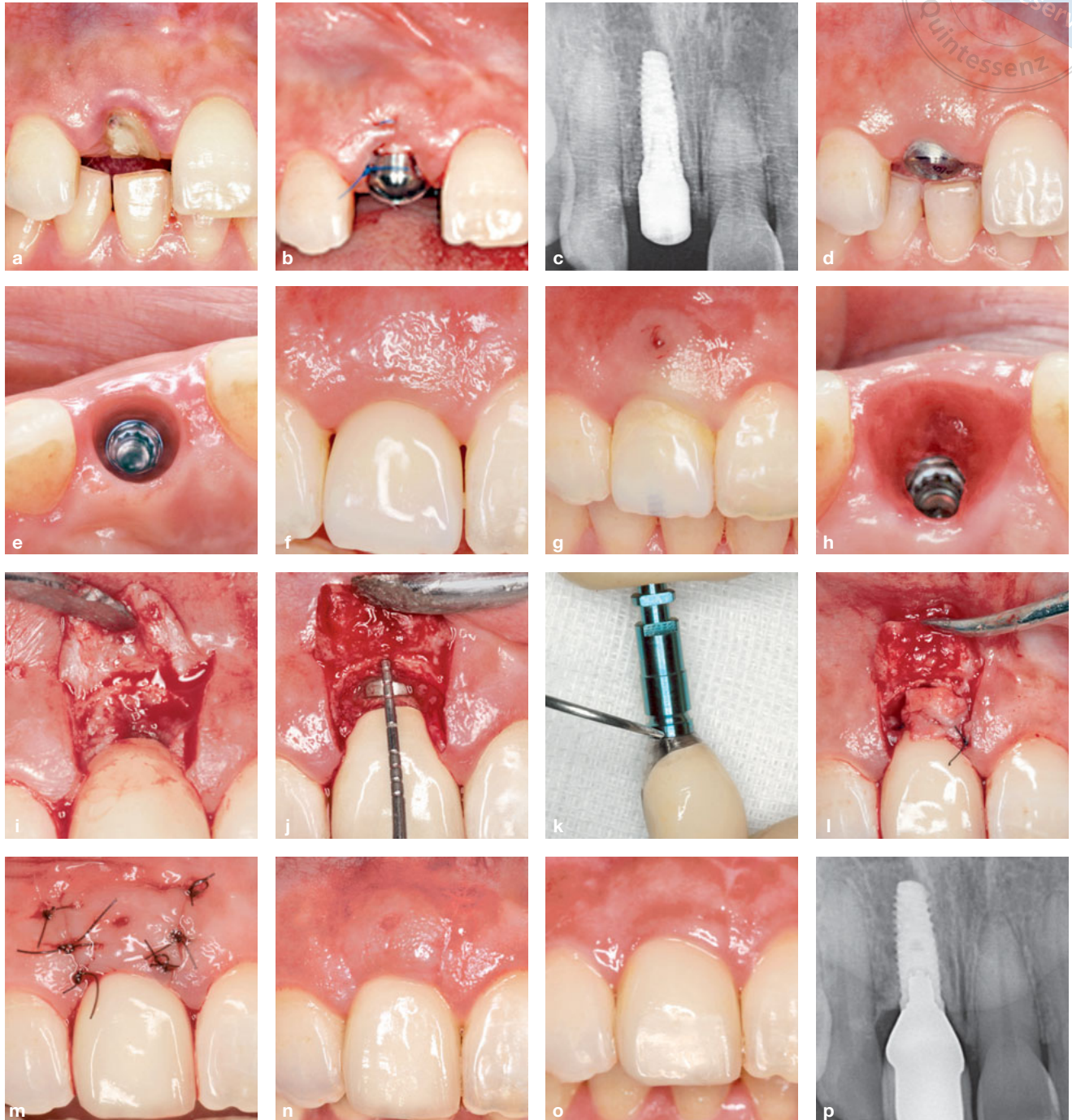


Fig 1 (a) The right maxillary central incisor was prepared for extraction. (b) Photograph taken immediately after implant placement. (c) Radiograph taken immediately after implant placement. (d) Normal-appearing soft tissue before the impression was taken. (e) Image showing good healing of the gingival cuff. (f) Image taken after placement of the provisional crown. (g) 4 months after formation of the “emergency profile”, a fistula was detected in the buccal gingiva. (h) Occlusal view of a fistula emerging through the buccal wall of the gingival cuff. (i) Photograph showing granulation at the implant platform. (j) The marginal bone crest was absorbed 2 mm apical to the crown margin and 4 mm apical to the gingival margin of the adjacent tooth. (k) An over-contoured permanent crown was observed at the implant–abutment interface. (l) Connective tissue graft sutured on the exposed decontaminated implant surface and partial crown surface. (m) Sutures after periodontal plastic surgery. (n) Photograph taken 2 weeks after subepithelial connective tissue graft (SCTG) surgery. (o) Photograph taken 60 months after SCTG surgery. (p) Radiograph taken 60 months after SCTG surgery.

Table 1 Details of our cases treated with SCTG surgery.

| Case | Tooth | Implant system | T1 | Implant debridement | T2 | PD | BOP | Pli | KG |
|------|---------------------------------|-------------------------|----|---------------------|----|-------------|-------------|-------------|-------|
| 1 | Right maxillary central incisor | 3i osseotite 4.0*13 mm | 4 | 0.9% saline | 60 | 1,1,1,1,1,2 | 0,0,0,0,0,0 | 0,0,0,0,0,0 | 7,6,8 |
| 2 | Mandibular left lateral incisor | Nobel Replace 3.5*13 mm | 21 | 0.9% saline | 36 | 2,2,2,3,2,2 | 0,1,1,0,0,0 | 0,0,0,0,0,0 | 5,3,5 |
| 3 | Right maxillary central incisor | Bicon 4.0*8 mm | 11 | Implantoplasty | 41 | 2,2,3,2,1,1 | 0,0,0,0,0,0 | 0,0,0,0,1,0 | 8,6,7 |

T1, Time for a fistula to appear after osteointegration (months); T2, Follow-up period after SCTG (months); PD, Probing depth (mm) at six sites at T2; BOP, Bleeding on probing at six sites at T2; 0, No bleeding present; 1, Bleeding present; Pli, Plaque index (Silness & Loe, 1964) at six sites at T2; KG, Keratinised gingiva width (mm) at three buccal sites at T2.

The temporary restoration was removed and 0.2% chlorhexidine was used to irrigate the sulcus. The permanent restoration was placed because it had a contour identical to the temporary restoration, and a much smoother surface. Initial therapy included oral hygiene instruction, ultrasonic supragingival scaling and rubber cup polishing. After one week, the fistula remained, 3 mm apical to the gingival margin. Surgery was indicated, and the patient thus underwent flap surgery with a microinvasive surgical instrument. Two vertical papilla-preserving incisions were made and a full thickness flap was elevated (Fig 1i); the granulation tissue was removed and a 2-mm labial implant surface was observed. The bone crest was 4 mm apical to the gingival margin of the left maxillary central incisor (Fig 1j). No foreign body material (e.g., cement or food residue) was found in the peri-implant mucosal sulcus. The only finding presumably contributing to inflammation was that the diameter of the prosthesis was larger than that of the implant at the implant–abutment interface (Fig 1k). Reduction of the diameter of the permanent prosthesis at the neck was performed *in vitro* and the crown was well polished. It was then fixed and torqued to 30 N/cm. A 6 mm × 8 mm SCTG with a thickness of approximately 1.5–2 mm was harvested to aid in closure of the fistula. After decontaminating the exposed implant surface with cotton soaked in physiological saline, the SCTG was sutured onto the exposed surface of the implant, and beneath the fistula, using simple interrupted sutures (Fig 1l). The full thickness flap was then sutured back to the original position with 5-0 nylon sutures and a microsurgical instrument, with the aid of magnifying glasses (4×) (Fig 1m). The patient was advised to rinse with 0.12% chlorhexidine solution twice a day for 1 week, and not to brush the treated area for 2 weeks after surgery. The patient was recalled after 1 week, 2 weeks (Fig 1n), 1 month, 3 months, 6 months and 1 year. Thereafter, the patient was recalled for an annual follow-up until 5 years after surgery (Figs 1o

and 1p). No oedema or fistula was observed again. By the 5-year follow-up, the probing depths around the implant were less than 3 mm and there was no bleeding on probing (Table 1). The patient did not exhibit any discomfort at this follow-up, and the good aesthetic outcome was maintained.

Case 2

A 32-year-old man who had undergone replacement of the mandibular left lateral incisor with an implant-supported restoration (Nobel Replace, Nobel Biocare, Gothenburg, Sweden) 21 months prior exhibited an asymptomatic fistula at the buccal gingiva of the implant (Fig 2a). The fistula was located opposite to the implant–abutment interface (Fig 2b). After 3 years of nonsurgical treatment and observation, the fistula remained (Figs 2c and 2d). Flap surgery was then performed with a microinvasive surgical instrument. During the surgery, the buccal bone showed apical absorption with a distance of 2 mm from the shoulder of the implant. The thickness of the buccal bone was approximately 1 mm (Fig 2e) and SCTG surgery was performed (Fig 2f). The fistula did not recur and the gingival probing depth, bleeding index and keratinisation were stable during 36 months of follow-up (Figs 2g and 2h and Table 1).

Case 3

A 51-year-old woman who underwent replacement of the maxillary right central incisor with an implant-supported restoration (Bicon, Boston, MA, USA) 11 months prior exhibited an asymptomatic fistula at the buccal gingiva (Figs 3a and 3b). After SCTG surgery with a microinvasive surgical instrument combined with implantoplasty (Figs 3c to 3g), the fistula did not recur, and the gingival probing depth, bleeding index and keratinisation were stable during 41 months of follow-up (Figs 3h to 3j and Table 1).

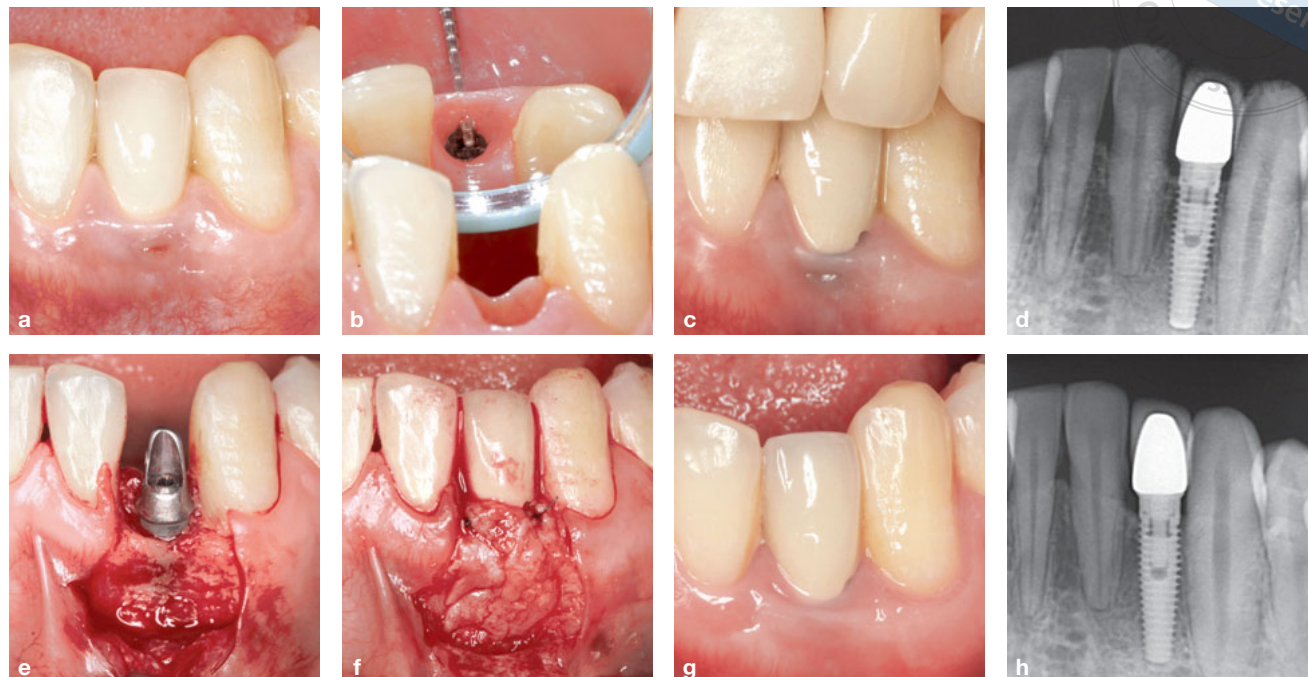


Fig 2 (a) Fistula in the buccal gingiva of an implant-supported restoration of the mandibular left lateral incisor. (b) Fistula opposite the implant–abutment interface. (c) By the 3-year follow-up, the fistula remained. (d) Radiograph taken before SCTG surgery. (e) During surgery, the buccal bone showed apical absorption at a distance 2 mm from the shoulder of the implant, and the buccal bone thickness was only 1 mm. (f) A SCTG was sutured on the implant surface. (g) During 36 months of follow-up, the fistula did not recur. (h) Radiograph taken after 36 months of follow-up.

Discussion

Causes and risk factors of peri-implant disease

A cause-and-effect relationship has been established between biofilm and peri-implant disease^{1,2}. There are numerous risk factors for peri-implant disease, such as excess cement³, a microgap between the implant and abutment⁴, thin tissue biotype⁵ and an excessively large abutment and crown⁶. Excess cement around the implant can promote biofilm formation in the peri-implant sulcus³. A microgap between the implant and abutment can lead to a bacterial reservoir that might interfere with the long-term health of the peri-implant tissues⁴. In case 3, the biofilm was presumed to be the main aetiology for peri-implant disease. In case 2, the presence of a microgap seemed to be the main aetiology for peri-implant disease. In case 1, an excessively large abutment/crown may have exacerbated peri-implant disease. As previously reported, an oversized abutment or prosthesis can induce peri-implant gingival recession⁶. Histologically, collagen fibres appear as circular fibres at the level of the implant platform, and at the first implant thread level for implants without a platform⁷. These fibres pro-

mote mechanical retention of periodontal fibres, thus protecting the crestal bone⁷. One possible explanation for fistula development is tearing of the collagen fibres due to an over-contoured crown; alternatively, an over-contoured restoration may cause the sulcus to become tightly attached, such that bacteria at the bottom of the periodontal pocket cannot easily drain out of the peri-implant mucosal sulcus, instead draining directly from the gingival tissue.

To manage peri-implant disease, mechanical and biological causes must be addressed in that order. According to Okayasu’s decision tree⁸ for the management of peri-implant disease, initial therapy should be optimised before the actual operation and 2 mm bone loss around the implant can be controlled by treating the soft tissue.

Gingival biotype and free connective tissue graft techniques

For peri-implants, similar to natural teeth, gingival thickness is more important than the volume of keratinised gingiva. A thick gingival biotype promoted good long-term aesthetic outcomes of implant restoration⁵.

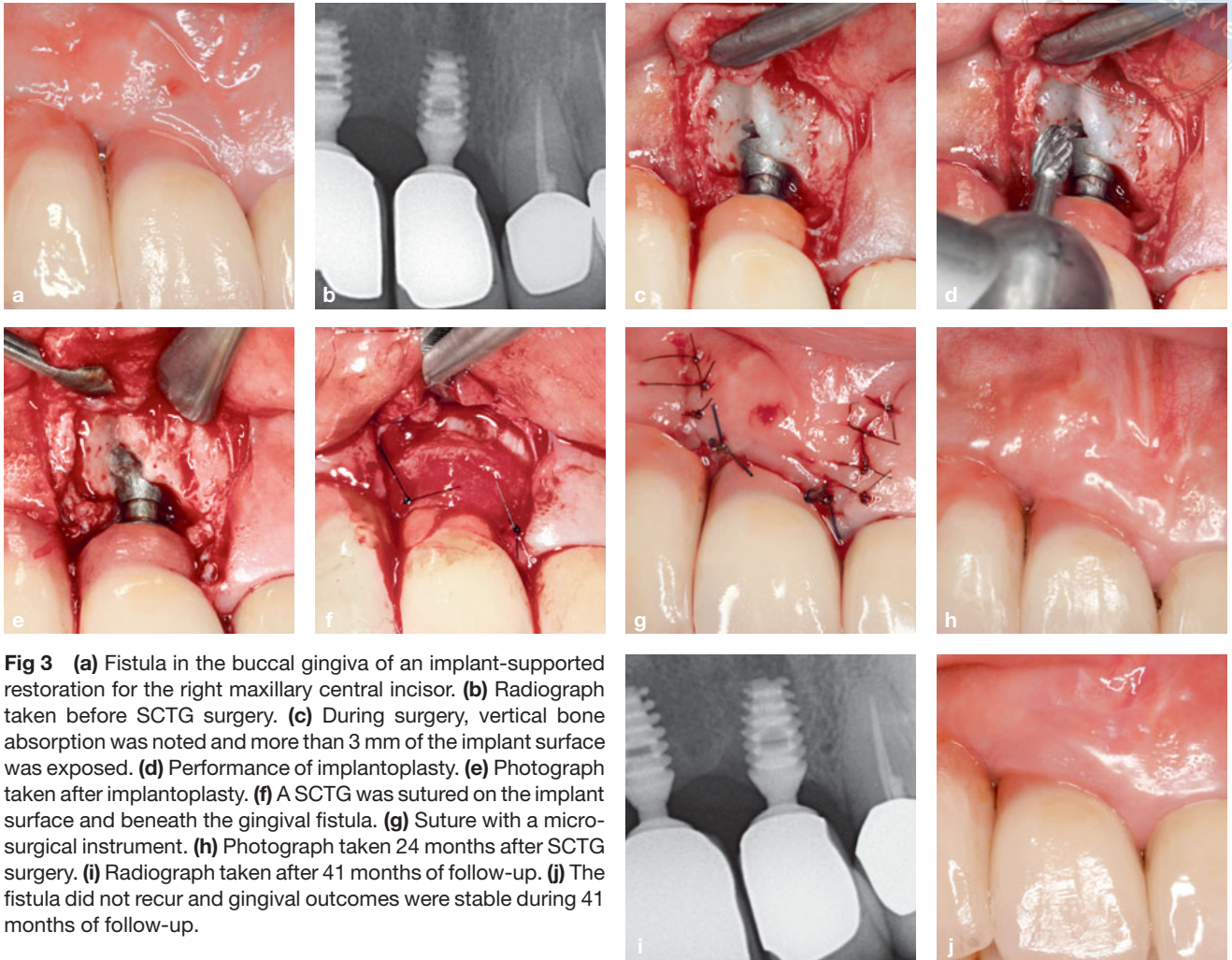


Fig 3 (a) Fistula in the buccal gingiva of an implant-supported restoration for the right maxillary central incisor. (b) Radiograph taken before SCTG surgery. (c) During surgery, vertical bone absorption was noted and more than 3 mm of the implant surface was exposed. (d) Performance of implantoplasty. (e) Photograph taken after implantoplasty. (f) A SCTG was sutured on the implant surface and beneath the gingival fistula. (g) Suture with a microsurgical instrument. (h) Photograph taken 24 months after SCTG surgery. (i) Radiograph taken after 41 months of follow-up. (j) The fistula did not recur and gingival outcomes were stable during 41 months of follow-up.

When the peri-implant soft tissue is thicker initially, there is less radiographic marginal bone loss following implant placement⁹.

Free CTGs combined with a coronally repositioned flap have been used to address soft tissue discrepancies around single implant restorations. Zucchelli et al¹⁰ used a coronally advanced flap in combination with SCTG for reduction of the implant abutment and restoration and the mean soft tissue dehiscence coverage was 96.3% at 1 year after surgery. These findings suggested that SCTG is effective for promoting soft tissue stability. Schwarz et al¹¹ combined SCTG (for augmentation of soft tissue volume) with bone regeneration for treatment of localised alveolar ridge defects in peri-implant disease; minimal gingival recession occurred in the short term. With the exception of

effective apical-coronal gingival volume maintenance, SCTG was shown to increase the gingival volume in the horizontal plane. Stefanini et al¹² reported that SCTG increased soft tissue volume in both the vertical and horizontal planes around single implants with shallow buccal bone dehiscence, with no buccal mucosal recession or clinical signs of peri-implant disease. SCTG can increase mucosal thickness in both dogs¹³ and humans¹⁰. De Bruyckere et al¹⁴ reported that in patients with a horizontal alveolar defect requiring contour augmentation for aesthetic reasons, the soft tissue volume increased by a mean of 1.07 mm immediately after CTG and after 1 year, the mean increase was 0.97 mm. However, few previous studies showed that SCTG could be utilised to control gingival fistulae around implants.

Microinvasive surgery

Nearly all attempts to control peri-implant soft tissue defects involved application of a microinvasive surgery technique^{10,11,14}. Microinvasive surgery can minimise gingival recession, even when using the original flap; it can also reduce scar formation, increase blood supply and improve the long-term aesthetic outcome¹⁵. The key to successful management of the cases presented herein was utilisation of SCTG to increase soft tissue thickness and maintain the emergency profile with minimal trauma.

Conflicts of interest

The authors declare no conflicts of interest related to this study.

Author contribution

Drs Peng LI, De Li LI and Zhi Hui TANG performed the clinical treatments; Dr Peng LI collected the data and wrote the manuscript; Dr Hua Allen CHEN revised the manuscript.

(Received Mar 11, 2019; accepted Oct 17, 2019)

References

- Schwarz F, Derks J, Monje A, Wang HL. Peri-implantitis. *J Clin Periodontol* 2018;45:S246–S266.
- Zhang Q, Qin XY, Jiang WP, Zheng H, Xu XL, Chen F. Comparison of subgingival and peri-implant microbiome in chronic periodontitis. *Chin J Dent Res* 2015;18:155–162.
- Pesce P, Canullo L, Grusovin MG, de Bruyn H, Cosyn J, Pera P. Systematic review of some prosthetic risk factors for periimplantitis. *J Prosthet Dent* 2015;114:346–350.
- Scarano A, Valbonetti L, Degidi M, et al. Implant-abutment contact surfaces and microgap measurements of different implant connections under 3-dimensional x-ray microtomography. *Implant Dent* 2016;25:656–662.
- Aguirre-Zorzano LA, Vallejo-Aisa FJ, Estefania-Fresco R. Supportive periodontal therapy and periodontal biotype as prognostic factors in implants placed in patients with a history of periodontitis. *Med Oral Patol Oral Cir Bucal* 2013;18:e786–e792.
- Soadoun AP, Touati B. Soft tissue recession around implants: is it still unavoidable?--Part II. *Pract Proced Aesthet Dent* 2007;19:81–87; quiz 88.
- Rodríguez X, Vela X, Calvo-Guirado JL, Nart J, Stappert CF. Effect of platform switching on collagen fiber orientation and bone resorption around dental implants: a preliminary histologic animal study. *Int J Oral Maxillofac Implants* 2012;27:1116–1122.
- Okayasu K, Wang HL. Decision tree for the management of periimplant diseases. *Implant Dent* 2011;20:256–261.
- Suárez-López Del Amo F, Lin GH, Monje A, Galindo-Moreno P, Wang HL. Influence of soft tissue thickness on peri-implant marginal bone loss: a systematic review and meta-analysis. *J Periodontol* 2016;87:690–699.
- Zucchelli G, Mazzotti C, Mounssif I, Mele M, Stefanini M, Montebugnoli L. A novel surgical-prosthetic approach for soft tissue dehiscence coverage around single implant. *Clin Oral Implants Res* 2013;24:957–962.
- Schwarz F, Sahn N, Becker J. Combined surgical therapy of advanced peri-implantitis lesions with concomitant soft tissue volume augmentation. A case series. *Clin Oral Implants Res* 2014;25:132–136.
- Stefanini M, Felice P, Mazzotti C, Marzadori M, Gherlone EF, Zucchelli G. Transmucosal implant placement with submarginal connective tissue graft in area of shallow buccal bone dehiscence: a three-year follow-up case series. *Int J Periodontics Restorative Dent* 2016;36:621–630.
- Schwarz F, Mihatovic I, Shirakata Y, Becker J, Bosshardt D, Sculean A. Treatment of soft tissue recessions at titanium implants using a resorbable collagen matrix: a pilot study. *Clin Oral Implants Res* 2014;25:110–115.
- De Bruyckere T, Eghbali A, Younes F, De Bruyn H, Cosyn J. Horizontal stability of connective tissue grafts at the buccal aspect of single implants: a 1-year prospective case series. *J Clin Periodontol* 2015;42:876–882.
- Burkhardt R, Lang NP. Coverage of localized gingival recessions: comparison of micro- and macrosurgical techniques. *J Clin Periodontol* 2005;32:287–293.