

A Novel Approach Using 15% Natural Chitosan Gel in the Management of Intrabony Defects: A Pilot Study

Irfana BABRAWALA¹, Prabhuji MUNIVENKATAPPA LAKSHMAIAH VENKATESH¹, Karthikeyan BANGALORE VARADHAN¹

Objective: To evaluate the effectiveness of 15% chitosan in gel form as a periodontal regenerative material in the periodontal intrabony defects.

Methods: A pilot study split-mouth design of 10 patients within the age group of 30 to 55 years with bilateral intrabony defects ≥ 3 mm and clinical attachment levels (CAL) ≥ 5 mm were selected. The test site received open flap debridement with 15% Chitosan gel as a regenerative material and the controlateral side that acted as a control received only open flap debridement. Clinical and radiographic measurements were recorded at baseline, and 3, 6 and 9 months after the treatment.

Results: Data revealed that there was a significant improvement in both clinical and radiographic parameters when intragroup comparison was performed. When intergroup comparison was done, there was a mean difference in CAL (5.8 ± 1.398 mm) and the depth of the intrabony defect (3.41 ± 1.17 mm) at 9 months when compared to baseline.

Conclusion: Within the limitations of the study, it can be concluded that a 15% concentration of chitosan gel is a promising aid and could be used as an effective material in periodontal regeneration.

Key words: bone graft, chitosan, periodontal regeneration, wound healing
Chin J Dent Res 2016;19(4):231–237; doi: 10.3290/j.cjdr.a37148

Recent developments in the field of dentistry have revolutionised the approach towards the management of periodontal disease¹. Failure to control the progression of periodontal disease leads to the development of intrabony defects. These osseous defects, if left untreated, may adversely affect the long-term prognosis of the tooth.

Complete removal of calculus is possible by surgical access to the intrabony defect. Regeneration in these osseous defects can be achieved with an array of available regenerative materials^{2,3}, with guided bone/tissue regeneration methods using barrier membranes⁴ and a combination of bone grafts and membranes. Every regenerative material recorded in the literature has its own unique regenerative potency with certain limita-

tions such as additional surgery, inadequate bone supply, donor pain⁵, inappropriate biodegradation, immune response and low tissue compatibility⁶.

These concerns and limitations have evoked a substantial interest in the development of artificial materials as bone graft substitutes⁷ that are natural in origin. Recently, with the discovery of a novel natural polymer, chitosan is considered a boon in regenerative dentistry. Chitosan, which is a natural carbohydrate polymer, has gained great attention in the field of regenerative therapy⁸ because of its biological properties such as non-toxicity, anti-inflammatory, biocompatibility, biodegradability and bioadhesion⁹⁻¹⁴. In dentistry, chitosan has been used in various forms such as films, mouthwashes¹⁵ and as a carrier for local drug delivery.

Chitosan possesses bioactive properties such as antimicrobial, hemostatic, tissue-regenerative activities like activating osteoblasts that would eventually increase osteoconductivity¹⁶ and neovascularisation¹⁷, and leads to accelerated bone growth^{18,19}. Furthermore, chitosan has been evaluated for its bone regenerative potential by incorporating chitosan in guided tissue

¹ Department of Periodontology, Krishnadevaraya College of Dental Sciences and Hospital, Bangalore, India.

Corresponding author: Dr Prabhuji MLV, Department of Periodontology, Krishnadevaraya College of Dental Sciences and Hospital, Hunsmanahalli, Near International Airport Road, Bangalore 562157, India. Tel: 91 9448057407 Email: prabhujimlv@gmail.com

regeneration (GTR) membrane and bone grafts and it has shown high tissue compatibility with no evidence of a inflammatory reaction²⁰. Since chitosan has a good regenerative capacity, Boynuegriet al²⁰ evaluated the chitosan preparation (1% chitosan gel) alone for the treatment of periodontal intraosseous defects and reported favourable bonefill. Subsequently, an in vitro study by Weir et al²¹ in 2010 also showed that chitosan, at 15% concentration, was very effective and had a superior regenerative potential than lower concentrations of chitosan when amalgamated with bone grafts. Since 15% chitosan, when used in combination with bone graft has shown more promising regenerative potential, it is speculated that 15% chitosan alone, if used in periodontal intraosseous defects, may show better potential as a regenerative material. However, there are no clinical studies to date, testing the efficacy of standalone chitosan preparation as a 15% chitosan gel in the treatment of periodontal intrabony defects. Hence, we aim to evaluate the efficacy of 15% chitosan gel alone, as a bone regenerative material in the management of intrabony defects in patients with chronic periodontitis.

Materials and methods

Source of data

The present split-mouth randomised controlled trial with 80% power consisted of a total of 10 patients including 7 males and 3 females attending the outpatient section of the Department of Periodontology, Krishnadevaraya College of Dental Sciences and Hospital in Bangalore, India. The study protocol was reviewed and approved by the institutional ethical committee and review board. The patients were informed about the design and nature of the clinical trial and the potential risks if any. Signed informed written consent for their participation was obtained.

Selection criteria

Systemically healthy patients aged ≥ 28 years with the presence of clinical attachment level (CAL) ≥ 5 mm²⁰, associated with a 2-wall, 3-wall or a combined 2- to 3-wall intrabony defect ≥ 3 mm deep (assessed by transgingival probing and to be confirmed after flap elevation); with the defect not extending to a root furcation area and associated tooth; with neighbouring teeth being vital with ≤ 1 mm of tooth mobility; and had no invasive periodontal therapy carried out in the past 6 months,

were included in the study. Phase 1 therapy i.e. scaling and root planning was performed.

Re-evaluation was carried out 8 weeks²⁰ after completion of the aetiologic therapy and patients with unacceptable levels of oral hygiene (plaque index (PI) >1.5), pregnant and lactating women, smokers, patients with suspected or a known allergy to chitosan or on medications known to interfere with periodontal wound healing, and immunocompromised patients, were excluded from the study.

Intra-examiner calibration

Prior to the commencement of the study, intra-examiner calibration was achieved by examining 20 patients two times (24 h apart). Calibration was established if measurements at baseline and 24 h were analogous within 1 mm at the 95% level.

Presurgical therapy

Patients satisfying the inclusion and exclusion criteria were randomly allocated by means of flipping a coin into group 1 - open flap debridement (OFD) and group 2- OFD and 15% chitosan gel. One examiner (IB) performed all the surgeries while another examiner (PMLV) performed all the clinical and radiographic measurements without knowledge of the groups. Patients were blinded for allocation to a particular group and treatment.

Clinical and radiographic measurements

Prior to surgery, the clinical parameters recorded were pocket probing depth (PPD) and relative attachment level (RAL), from the apical extent of a grooved customised acrylic stent to the base of the defect with a UNC-15 (University of North Carolina -15 periodontal probe – Hu Friedy, Illinois, USA) manual probe, to ensure reproducible placement of the probe for each successive measurement. All the radiographs were recorded using a paralleling technique of Radiovisiography (RVG), pre-operatively at baseline and postoperatively at 3, 6 and 9 months. For measurements, calibrated measurement software called Digimizer (version 4.0, Image analysis software, MedCalc software, Ostend, Belgium) was used. The cemento-enamel junction (CEJ), the crest of the alveolar bone (AC) and the base of the defect (BD) were marked on the image. A line was drawn from CEJ to BD. The software then displayed the distance between these two points. The same procedure was then repeated to obtain the distance between CEJ and AC. Subtract-

ing the two measurements; the depth of the osseous defect was obtained. The total bonefill was measured subtracting the depth of the osseous defect at 9 months from the baseline measurement. All clinical and radiographic measurements were performed by one examiner (PMLV), who was blinded to the surgical procedures performed.

Formulation of 15% chitosan gel

Chitosan was used after purification by dissolution-precipitation and dialysis, and reacetylation up to a 50% degree. Fifteen percent chitosan solution (chitosan and sterile distilled water at pH 7.2) was used to produce gels at 37°C following simple neutralisation with sodium hydroxide, although with very slow gelation and a weak increase in viscosity. In order to produce a stable formulation for a medical application, thermosetting properties were tested before and after lyophilisation. Addition of trehalose preserved the thermosetting properties. The 15% concentration of chitosan gel was prepared in accordance with Weir et al²¹ in a laboratory (Essence biotech research laboratory, Kochi, Kerela).

Surgical procedure

After administration of local anesthesia with 2% lignocaine hydrochloride (Lignox 2%; Indoco Remedies, Goa, India) and an epinephrine concentration of 1:80,000, sulcular incisions were made on the buccal and lingual aspects of the involved sites, with full thickness mucoperiosteal flaps raised. Area-specific curettes and ultrasonic scalers were used for thorough debridement (Fig 1). In group 2, 15% chitosan gel was used as a bone regenerative material to fill the intrabony defect (Fig 2). Thereafter, the flaps were sutured to its original position with 3-0 silk sutures (Mersilk, Ethicon, Johnson & Johnson, Himachal Pradesh, India). Simple interrupted sutures were given to achieve primary closure followed by placement of periodontal dressing (Coe pack, GC America, Illinois, USA).

Postoperative wound management

Immediately following surgery, 500 mg of amoxicillin every 6 h for 5 days, 400 mg of Ibuprofen every 8 h and 0.2% chlorhexidine digluconate twice daily for 4 weeks post-surgically was prescribed to the patient. Patients were re-evaluated for pain, sensitivity and discomfort, if any. Patients were recalled after 7 days for suture removal. Hard and soft tissue measurements were taken at 3, 6 and 9 months post-surgically (Figs 3 and 4).

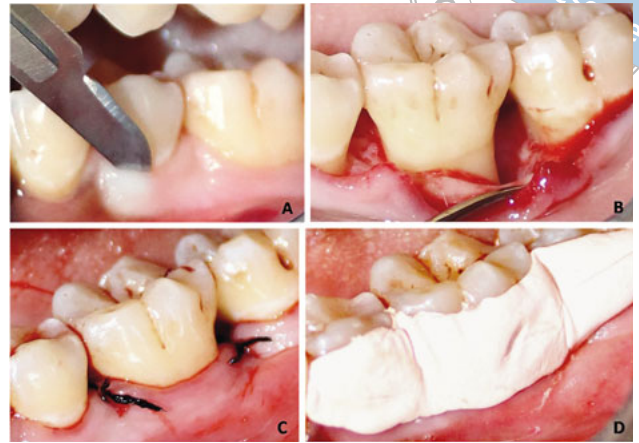

Fig 1 The surgical procedures for Group 1: A) Intraculcular incision given; B) raising the full thickness mucoperiosteal flap followed by debridement; C) primary closure with simple interrupted sutures; D) the periodontal dressing given.

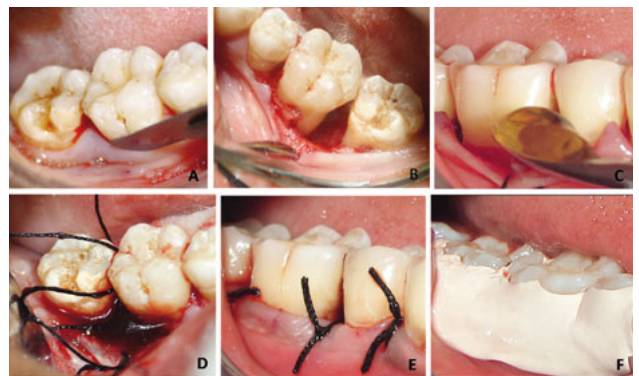


Fig 2 The surgical procedures for Group 2: A) Intraculcular incision given; B) raising the full thickness mucoperiosteal flap followed by debridement; (C and D) 15% chitosan gel packed in the defect; E) primary closure with simple interrupted sutures; F) periodontal dressing given.

Statistical analysis

The data collected was entered in Microsoft Excel and statistical analyses were performed using the Statistical Package for Social Sciences (SPSS version 10.5, Illinois, USA) software. The Shapiro-Wilks test was carried out to test the normalcy of the data and the data was found to be normally distributed. Therefore, parametric statistical tests were applied. Intragroup analysis was carried out by performing Analysis of Variance (ANOVA) at differ-

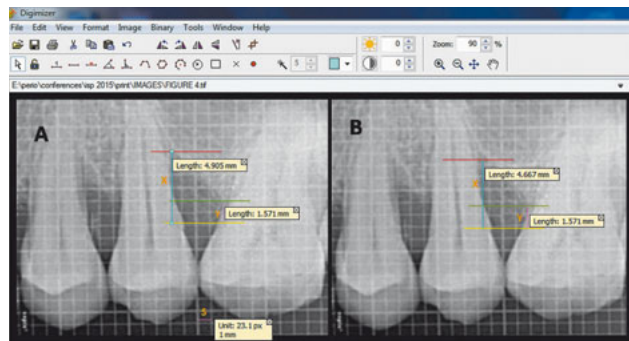
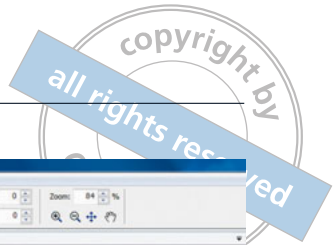

Fig 3 Radiographic analysis for Group 1 to determine the depth of the intrabony defect with three reference lines i.e the yellow line represents the cemento-enamel junction (CEJ) of the tooth; the green line represents the level of the alveolar crest (AC) and the red line represents the base of the alveolar defect (BD) using a software known as Digimizer (ver 4.0). Standardisation of the radiograph (S). X is the distance from CEJ to BD and Y is the distance from CEJ to AC. The depth of the intrabony defect = X-Y. A) Preoperative radiograph; B) 9-month postoperative radiograph.

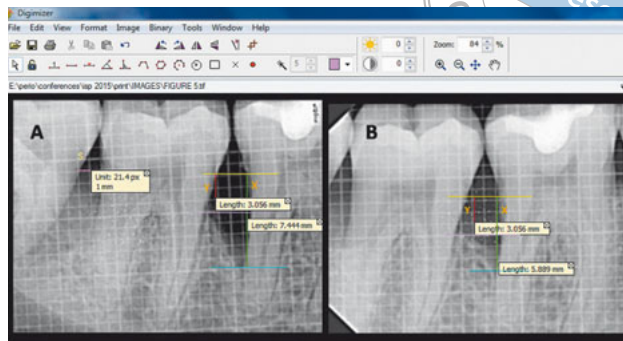


Fig 4 Radiographic analysis for Group 2 to determine the depth of the intrabony defect with three reference lines i.e. the yellow line represents the cemento-enamel junction (CEJ) of the tooth; the purple line represents the level of the alveolar crest (AC) and the blue line represents the depth of the alveolar defect (BD) using a software known as Digimizer (ver 4.0). Standardisation of the radiograph (S). X is the distance from CEJ to BD and Y is the distance from CEJ to AC. The depth of the intrabony defect = X-Y. A) Preoperative radiograph; B) 9-month postoperative radiograph.

ent time intervals. Intergroup analysis was done using an unpaired student t- test. In the above tests, $P < 0.05$ was considered to be statistically significant.

Results

A total of 20 defects in 10 patients were evaluated. The treated sites were evaluated for clinical parameters at baseline, and 3, 6 and 9 months postoperatively. No patient dropped out during the study and uneventful healing was observed. Good oral hygiene was maintained by the patients during the study period.

Both groups exhibited a significant reduction in clinical attachment level (CAL) gain at 9 months. The mean difference in CAL gain was significantly higher in Group 2 (8.50 ± 1.354 mm vs 2.70 ± 1.337 mm) compared to Group 1 (7.70 ± 1.337 mm vs 5.10 ± 1.287 mm) at 9 months (Table 1).

The mean amount of defect fill observed in Group 2 and Group 1 from baseline to 3 months (0.96 ± 0.48 mm vs 0.32 ± 0.07 mm), 6 months (2.19 ± 0.69 mm vs 1.14 ± 0.15 mm) and 9 months (3.41 ± 1.17 mm vs 1.81 ± 0.89 mm) was recorded (Table 1). Statistically significant differences in the amount of defect fill were observed between the two groups at 6 and 9 months. The percentage of defect fill observed for Group 2 and Group 1 at 9 months was 80.49 ± 7.50 and 47.87 ± 14.28 , respectively (Table 2). Intragroup analysis demonstrated statistically significant results for both groups at different visits for PPD, CAL and defect fill (Table 3).

Discussion

Chitin is the second most copious polysaccharide found in nature, after cellulose²² from the exoskeleton of species of different crustaceans (shrimps, crabs, etc). The alluring ability of this polysaccharide graft to potentiate the differentiation of osteoprogenitor cells that may facilitate bone formation⁸ makes it a very promising scaffold material in tissue engineering.

In this study, the effect of chitosan gel alone on periodontal regeneration was compared with open flap debridement. To the best of our knowledge, this is the first study in which chitosan gel at a concentration of 15% was evaluated for the purpose of repairing bone defects. The results of the present study demonstrated that there were significant improvements observed in both clinical and radiographic parameters.

Intrabony defects when treated with 15% chitosan gel that was used as a bone graft (Group 2) exhibited a significant PPD reduction of 5.8 ± 1.39 mm, a CAL gain of 5.8 ± 1.39 mm, a greater reduction in IBD depth of 3.41 ± 1.17 mm and a defect resolution of 80.49 ± 7.50 % at 9 months. This data was statistically significant when compared to open flap debridement (Group 1), where PPD reduction was 2.6 ± 1.26 mm, CAL gain was 2.6 ± 1.26 mm, IBD depth reduction was 1.81 ± 0.89 mm and defect resolution was 47.87 ± 14.28 % at 9 months.

In the present study, inflammation was assessed based on the plaque index (PI) and gingival bleeding index (GBI), since these indices reflect the status of

Table 1 Intergroup comparative evaluation of clinical attachment level (CAL) and radiographic bonefill in millimeters (mm) between Group 1 and Group 2 at different visits

Parameters	Visit	Group	N	Mean	SD	P value
CAL	Baseline	Group 1	10	7.70	1.337	0.200
		Group 2	10	8.50	1.354	
	3 months	Group 1	10	6.80	1.549	0.411
		Group 2	10	6.30	1.059	
	6 months	Group 1	10	6.10	1.370	0.024*
		Group 2	10	4.70	1.160	
	9 months	Group 1	10	5.10	1.287	0.001*
		Group 2	10	2.40	1.337	
Bonefill	Baseline	Group 1	10	4.11	1.19	0.912
		Group 2	10	4.17	1.24	
	3 months	Group 1	10	3.79	1.124	0.190
		Group 2	10	3.21	0.76	
	6 months	Group 1	10	2.97	1.04	0.017*
		Group 2	10	1.98	0.55	
	9 months	Group 1	10	2.20	0.95	0.001*
		Group 2	10	0.76	0.30	

* $P \leq 0.05$ is statistically significant

Table 2 Percentage of defect fill observed for Group 1 and Group 2 at 9 months.

Parameter	Group	N	Mean (%)	Standard deviation	P value
Defect resolution	Group 1	10	47.87%	14.28%	0.003*
	Group 2	10	80.49%	7.50%	

* $P \leq 0.05$ is statistically significant

Table 3 Intragroup comparative evaluation of clinical attachment level (CAL) and radiographic bonefill in millimeters (mm) for Group 1 and Group 2 at different visits.

Groups	Visits	CAL (Mean \pm SD)	Bonefill (Mean \pm SD)
Group 1	Baseline	7.70 \pm 1.337	4.30 \pm 1.160
	3 months	6.80 \pm 1.549	3.90 \pm 1.101
	6 months	6.10 \pm 1.370	3.00 \pm 1.155
	9 months	5.10 \pm 1.287	2.30 \pm 0.823
P value		0.002	0.001*
Group II	Baseline	8.50 \pm 1.354	4.30 \pm 1.252
	3 months	6.30 \pm 1.059	3.20 \pm 0.919
	6 months	4.70 \pm 1.160	2.00 \pm 0.471
	9 months	2.70 \pm 1.337	0.80 \pm 0.422
P value		0.001*	0.001*

* $P \leq 0.05$ is statistically significant

gingival inflammation. No inflammatory reactions along with the total biological acceptance were noticed. Furthermore, statistical analysis revealed that there is no statistical difference between the group selection, with respect to clinical and radiographic parameters. To ensure standardisation, properly calibrated examiners recorded the measurements and randomisation (flip a coin) was performed for unbiased allocation of the groups.

When the results of our study are compared to a previous study conducted by Boyneugri et al²⁰ on 1% chitosan gel for intraosseous defects, it was reported that there was a reduction in PPD by 1.60 mm for 1% chitosan and 2.0 mm for open flap debridement. Even at 6 months the results showed a PPD reduction of 3.8 mm for 15% chitosan, which is superior. Also, according to Boyneugri et al²⁰, the mean amount of defect fill observed at 6 months was 1 mm in comparison to 2.19 ± 0.69 mm observed in the current study.

Similarly, our results were better in comparison with another study where chitosan gel was applied for the treatment of chronic periodontitis. It was noted that after 6 months there was a reduction in PPD by 1.21 mm for chitosan and 0.94 mm for the control¹⁴.

Furthermore our results are in accordance with the previous studies where they combined chitosan with hydroxyapatite, PDGF-BB and chitosan in combination with collagen membrane, indicating that chitosan improves clinical parameters and radiographic bone resolution²⁰.

The noteworthy improvements noticed in the current study can be substantiated by reviewing the commendatory properties of chitosan on regeneration. The structural characteristics of chitosan are similar to the glycosaminoglycans, specifically hyaluronic acid that is found in extracellular matrices of numerous tissues and may mimic its functional behaviour. Hyaluronic acid is thought to facilitate the migration and proliferation of progenitor cells facilitating tissue regeneration²³. Chitosan may enhance osteoblastic differentiation and interfere with the fibroblast function to inhibit bone formation and indirectly facilitate osteogenesis⁸. The significant advantage of chitosan is that its degradation product is neutral to weak base sugar as opposed to certain graft materials that generate acidic degradation by products evoking an undesirable tissue reaction²¹.

However, the results of this study should be interpreted with caution as there are certain inherent limitations. Chitosan itself has some limitations despite the fact that it is a propitious material. This polysaccharide has poor solubility²⁴ and lacks long-term stability. The mechanical strength of the chitosan scaffold needs to

be improved²⁵. In order to attain the desired mechanical properties of chitosan scaffold, hydroxyapatite²⁶ or gelatine²⁷ can be used. In the future, there is a need for long-term randomised clinical trials and histometric analysis should be conducted in order to ratify the outcome of this study.

With the limited evidence available, it can be concluded that 15% chitosan gel may have osteogenic regenerative potential and may be used in the management of intraosseous defects.

Conflicts of interest

The authors reported no conflicts of interest to this study.

Author contribution

Dr Irfana Babrawala for the study execution and manuscript preparation; Dr Prabhuji Munivenkatappa Lakshmaiah Venkatesh for the research design and the study execution; and Dr Karthikeyan Bangalore Varadhan for the manuscript preparation.

(Received Apr 19, 2016; accepted Sep 13, 2016)

References

1. Gupta SC. Local drug delivery in periodontics. *Indian J Dental Sci* 2010;2:32–34.
2. Garrett S. Periodontal regeneration around natural teeth. *Ann Periodontol* 1996;1:621–666.
3. Laurell L, Gottlow J, Zybuz M, Persson R. Treatment of intrabony defects by different surgical procedures. A literature review. *J Periodontol* 1998;69:303–313.
4. Joly JC, Palioto DB, de Lima AF, Mota LF, Caffesse R. Clinical and radiographic evaluation of periodontal intrabony defects treated with guided tissue regeneration. A pilot study. *J Periodontol* 2002;73:353–359.
5. Wagh AS. *Chemically Bonded Phosphate Ceramics: Twenty-First Century Materials with Diverse Applications*. New York: Elsevier Science, 2004.
6. Suzuki JB, Goodman SB, Phillips B. Comparison of clinical healing of human periodontal defects with HTR synthetic grafts. *J Dent Res* 1989;68:409 (Abstr. 1822).
7. Giannoudis PV, Dinopoulos H, Tsiridis E. Bone substitutes: an update. *Injury* 2005;36:S20–S27.
8. Klokkevold PR, Vandemark L, Kenney EB, Bernard GW. Osteogenesis enhanced by chitosan (poly-N-acetyl glucosaminoglycan) in vitro. *J Periodontol* 1996;67:1170–1175.
9. Senel S, Kas HS, Squier CA. Application of chitosan in dental drug delivery and therapy. In: Muzzarelli RAA. *From Dietary Supplement to Drug Carrier*. Atec: Grottammare, 2000:241–256.
10. Senel S, Ikinici G, Kaş S, Yousefi-Rad A, Sargon MF, Hincal AA. Chitosan films and hydrogels of chlorhexidine gluconate for oral mucosal delivery. *Int J Pharm* 2000;193:197–203.
11. Ikinici G, Senel S, Akincibay H, et al. Effect of chitosan on a periodontal pathogen *Porphyromonas gingivalis*. *Int J Pharm* 2002;235:121–127.

12. Fakhry A, Schneider GB, Zaharias R, Senel S. Chitosan supports the initial attachment and spreading of osteoblasts preferentially over fibroblasts. *Biomaterials* 2004;25:2075–2079.
13. Aksungur P, Sungur A, Unal S, Iskit AB, Squier CA, Senel S. Chitosan delivery systems for the treatment of oral mucositis: in vitro and in vivo studies. *J Control Release* 2004;98:269–279.
14. Akncbay H, Senel S, Ay ZY. Application of chitosan gel in the treatment of chronic periodontitis. *J Biomed Mater Res B Appl Biomater* 2007;80:290–296.
15. Archana V, Prabhujji MVL, Karthikeyan BV, Arul KS. Control of *Streptococcus sanguinis* oral biofilm by novel chlorhexidine-chitosan mouthwash: An in vitro study. *J Exp Integr Med* 2013;3:165–169.
16. Park YJ, Lee YM, Park SN, Sheen SY, Chung CP, Lee SJ. Platelet derived growth factor releasing chitosan sponge for periodontal bone regeneration. *Biomaterials* 2000;21:153–159.
17. Chevrier A, Hoemann CD, Sun J, Buschmann MD. Chitosan–glycerol phosphate/blood implants increase cell recruitment, transient vascularization and subchondral bone remodeling in drilled cartilage defects. *Osteoarthritis Cartilage* 2007;15:316–327.
18. Wang M. Developing bioactive composite materials for tissue replacement. *Biomaterials* 2003;24:2133–2151.
19. Jayasuriya AC, Kibbe S. Rapid biomineralization of chitosan microparticles to apply in bone regeneration. *J Mater Sci Mater Med* 2010;21:393–398.
20. Boynueğri D, Ozcan G, Senel S, et al. Clinical and radiographic evaluations of chitosan gel in periodontal intraosseous defects: a pilot study. *J Biomed Mater Res B Appl Biomater* 2009;90:461–466.
21. Weir MD, Xu HH. Osteoblastic induction on calcium phosphate cement-chitosan constructs for bone tissue engineering. *J Biomed Mater Res A* 2010;94:223–233.
22. Swatantra KSK, Awani KR, Satyawan S. Chitosan: A platform for Targeted Drug Delivery. *Int J PharmTech Res* 2010;2:2271–2282.
23. Adzick NS, Longaker MT. Characteristics of fetal tissue repair. In: Adzick NS, Longaker MT (eds). *Fetal Wound Healing*. New York: Elsevier Science, 1992:53–70.
24. Chen J, Li Q, Xu J, et al. Study on biocompatibility of complexes of collagen-chitosan-sodium hyaluronate and cornea. *Artif Organs* 2005;29:104–113.
25. Zhao L, Chang J, Zhai W. Preparation and HL-7702 cell functionality of titania/chitosan composite scaffolds. *J Mater Sci Mater Med* 2009;20:949–957.
26. Malafaya PB, Reis RL. Bilayered chitosan-based scaffolds for osteochondral tissue engineering: influence of hydroxyapatite on in vitro cytotoxicity and dynamic bioactivity studies in a specific double-chamber bioreactor. *Acta Biomater* 2009;5:644–660.
27. Jiankang H, Dichen L, Yaxiong L, et al. Preparation of chitosan-gelatin hybrid scaffolds with well-organized microstructures for hepatic tissue engineering. *Acta Biomater* 2009;5:453–461.