

# One-stage Operation for Noma-induced Bilateral Ankylosis Accompanied with Mouth Verrucous Carcinoma – a Case Report and Review of Literature

Xu Guang LU<sup>1</sup>, Zhi Gang CAI<sup>1</sup>, Yi ZHANG<sup>1</sup>, Yong Gang SUN<sup>1</sup>

*A rare case of a male patient who suffered from noma with sequelae of ankylosis in bilateral temporomandibular joints for 52 years and a neoplasm in the right commissure of the lips for 1 year, was operated on to resolve the ankylosis, remove the neoplasm and reconstruct the soft tissue defect with a forearm flap through a one-stage operation. The neoplasm pathology was verrucous carcinoma.*

**Key words:** noma, ankylosis, forearm flap, verrucous carcinoma

Noma (necrotising ulcerative stomatitis, stomatitis gangrenosum or cancrum oris) is a devastating orofacial gangrene that mainly occurs among children in the poorest areas of the world<sup>1,2</sup>. The disease is presently very rare in China.

## Case report

A 55-year-old male patient was referred in January 2007 with trismus for 52 years and a neoplasm in the right commissure of the lips for 1 year.

The patient suffered from noma in the right buccal mucosa after contracting the measles at 3 years of age. Antibiotics were given to control the infection in a rural clinic. Trismus occurred when the lesion healed. Because of the poor medical conditions in rural areas of China in the 1950s, forced opening of mouth was tried four times in vain. A scar excision was performed 41 years ago. However, trismus recurred half a year after that operation. One year ago, a neoplasm was found in the lip mucosa at the right commissure of the lips.

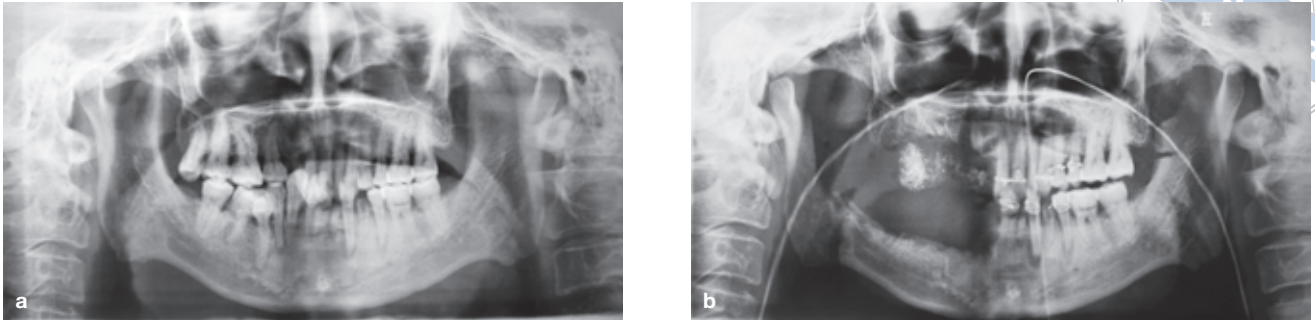
Because of no mobility in the jaw, only a large area of fibrous scar tissue in the right buccal mucosa was found during a physical examination. A panoramic radiograph and Schüller position film showed no obvious abnormal bone tissues in the bilateral temporomandibular joints. The obvious elongation of bilateral coracoid processes was observed on the panoramic radiograph (Fig 1).

The patient received general anaesthesia through nasal intubation. After the routine surgical preparations, a small piece of the neoplasm was excised for frozen section biopsy, which was diagnosed as verrucous carcinoma. Because of the long-standing trismus, a submandibular incision and osteotomy of the upper and lower alveolar processes were performed from canine to the third molar to access the safe margins of the cancer.

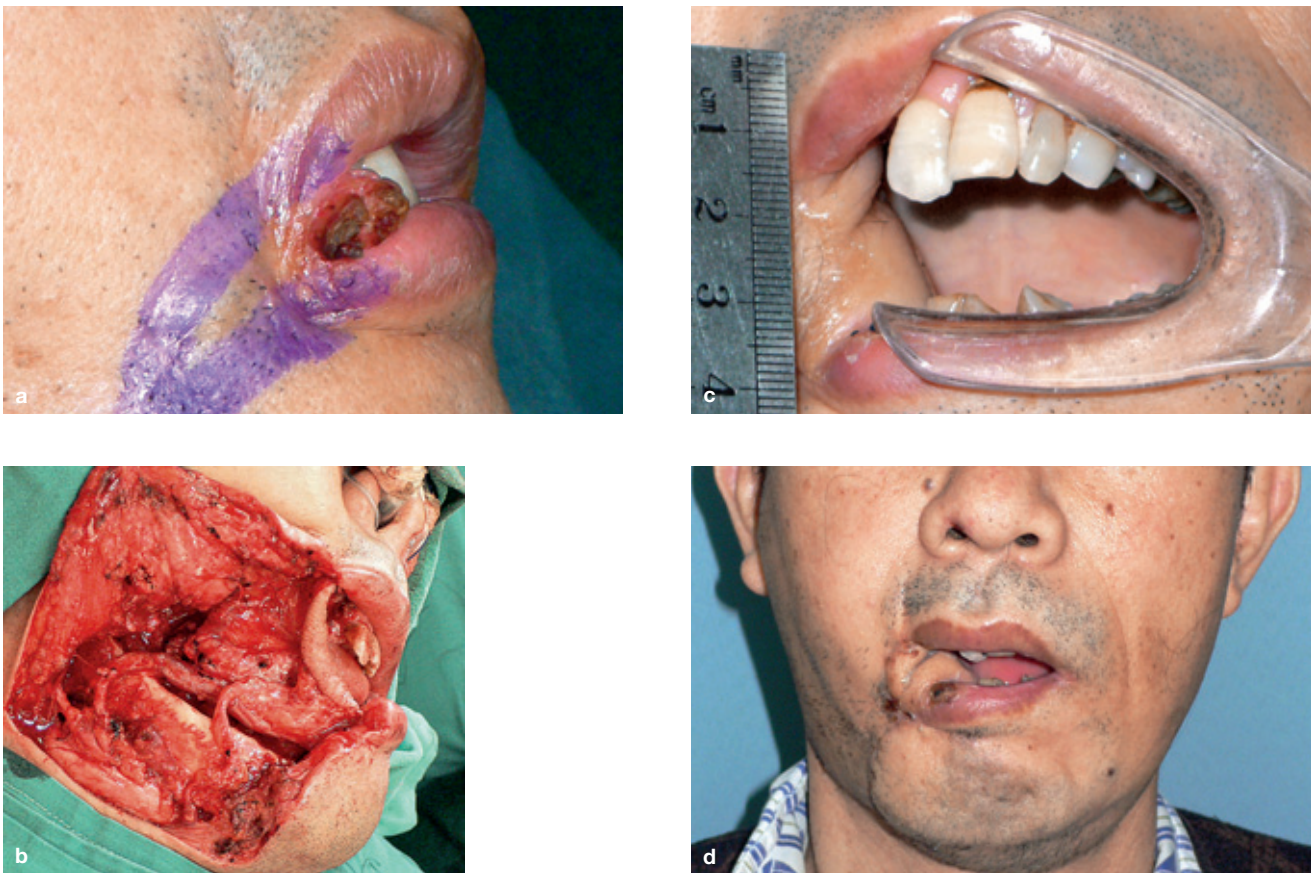After resecting the scar tissue, the right coracoid process was removed to avoid the attachment of the temporalis with fibrosis. However, no obvious improvement in mouth opening was observed after these were performed. Exploration of the left joint was performed through an intraoral incision in which the left coracoid process was also shown to be surrounded by the degenerated temporalis. Osteotomy of the left coracoid was performed through a resection of surrounding fibrous soft tissue. A passive interincisal mouth opening of 45 mm was achieved with no limitation of lateral movements of the mandible. The tissue lost in the right buccal side of the mouth was covered by a 6 cm × 8 cm left

<sup>1</sup> Department of Oral & Maxillofacial Surgery, Peking University School and Hospital of Stomatology, Beijing, P.R. China.

**Corresponding author:** Dr Zhi Gang CAI, Department of Oral & Maxillofacial Surgery, Peking University School and Hospital of Stomatology, #22 Zhongguancun Nandajie, Haidian District, Beijing 100081, P.R. China. Tel: 86-10-13910733943; Fax: 86-10-62173402. E-mail: czg4209@126.com



**Fig 1** (a) A panoramic radiograph before the operation. It shows no obvious abnormal bone tissues of the bilateral temporomandibular joints. The obvious elongation of bilateral coracoid processes was observed. (b) A panoramic radiograph after the operation. It shows that the upper and lower alveolar processes of the left side and both coracoid processes were removed.



**Fig 2** (a) Verrucous carcinoma in the right commissure. (b) Anastomosis of the forearm flap. (c) Mouth opening (1 month after operation). (d) Photo of front view (1 month after operation).

forearm flap. The external maxillary artery and anterior facial vein on the right side were chosen for vascular anastomosis.

A drainage tube was kept for 3 days. Elastic traction was kept for 2 weeks after the operation. The patient

was instructed in jaw-opening exercises during the postoperative days. Two months after the operation, there was still weakness in chewing, especially in the molar area (Fig 2). More exercises were prescribed to strengthen the surrounding muscles.

One year later, another operation was performed to improve the appearance of the right oral commissure (Fig 3). There was little improvement in occlusal force due to long-standing jaw immobility, but the patient could eat most food slowly without difficulty.

## Discussion

Noma appears to be limited to the undeveloped remote areas of Africa, Asia and South America<sup>2</sup>. There are also a few reports in developed countries<sup>3</sup>. The disease was not rare in China in the first half of last century with a high mortality rate<sup>4</sup>. There are few new cases in China nowadays, but sometimes sequelae from noma can be found in older people.

One of the most deleterious sequelae of noma is trismus<sup>2</sup>. In bilateral ankylosis, protracted immobilisation of the temporomandibular joint leads to adaptive muscle shortening, and gradual capsular and ligamentous shortening around the joint. The secondary changes may present bilaterally (especially in patients with long-standing lesions)<sup>5</sup>.

The improvement of trismus is a very important step in the treatment of noma. The scars in the present case caused trismus to extend from the lip to the tonsillar fossa, and to the surrounding tissues of the temporomandibular joint. It may be necessary to excise the condylar process and part of the ascending ramus to achieve jaw opening<sup>5,6</sup>. In the present case, the radiograph showed no abnormal changes in the bone tissue. The fibrous degeneration of the masticatory muscles is an important factor contributing to trismus. Mouth opening was improved after total excision of fibrous tissues with osteotomies of bilateral coracoid processes. A complete excision of the fibrous tissue was necessary. During surgery, adequate excision of the limiting scar tissue or any fibrous muscle is important<sup>5</sup>. Forcible opening of the mouth with a wrench is no substitute for proper scar excision. Such a forcible opening of the mouth cracks scars, creating new raw surfaces that then cause more fibrous tissue formation<sup>5</sup>.

The next step was to reconstruct the missing tissue. A skin graft is not recommended since it would heal with scar formation, which would result in the recurrence of ankylosis<sup>5</sup>. Different kinds of flaps have been applied to reconstruct the tissue defect. Some surgeons choose local flaps such as deltopectoral flaps and forehead flaps since they are easy to raise with little blood loss and relatively simple post-operation management<sup>7</sup>. In the present case, the excision of cancerous and fibrous tissues left a large soft tissue defect. A forearm flap was chosen since it would not produce an obvious second-

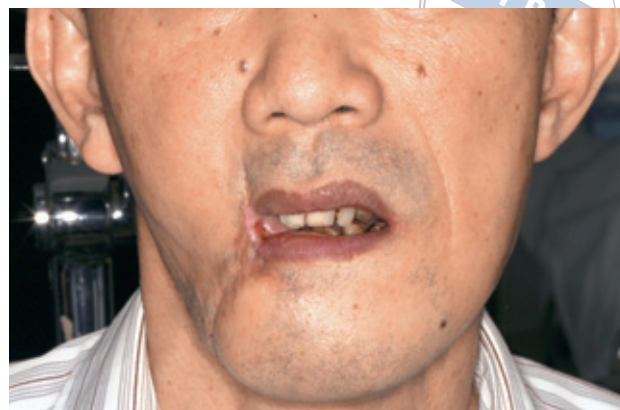

Fig 3 The facial appearance after the secondary operation.

ary deformity in the facial region. In the case of a child patient, the development of the orofacial region must be taken into consideration before a final decision is made.

Dean et al<sup>8</sup> suggested a one-stage operation for noma patients to save time and money. The authors also tried to solve more problems in one operation in the present study. But in order to achieve an ideal functional and cosmetic result, multi-stage operations may still be necessary.

The characteristics of the present case are the long-standing bilateral trismus and the reconstructive operation with a free flap. Although the carcinoma had no direct relationship with noma, it greatly increased the soft tissue loss and made the operation more complicated.

## References

1. Marck KW. A history of noma, the "face of poverty." *Plast Reconstr Surg* 2003;111:1702-1707.
2. Adolph HP, Yugueros P, Woods JE. Noma: a review. *Ann Plast Surg* 1996;37:657-668.
3. Buchanan JA, Cedro M, Mirdin A, Joseph T, Porter SR, Hodgson TA. Necrotizing stomatitis in the developed world. *Clin Exp Dermatol* 2006;31:372-374.
4. Chu FT, Fan C. Cancrum oris: a clinical study of 100 cases with special reference to prognosis. *Chin Med J* 1936;50:303-323.
5. Oluwasanmi JO, Lagundoye SB, Akinyemi OO. Ankylosis of the mandible from cancrum oris. *Plast Reconstr Surg* 1976;57:342-350.
6. Tempest MN. Cancrum oris. *Br J Surg* 1966;53:949-969.
7. Nath S, Jovic G. Cancrum oris: management, incidence, and implications of human immunodeficiency virus in Zambia. *Plast Reconstr Surg* 1998;102:350-357.
8. Dean JA, Magee W. One-stage reconstruction for defects caused by cancrum oris (noma). *Ann Plast Surg* 1997;38:29-35.