

A Systematic Review of the Uses of Fluoroscopy in Dentistry

Daniel UZBELGER FELDMAN¹, Jie YANG², Cristiano SUSIN³

Objective: *To determine the quality of the evidence for the uses of fluoroscopy in dentistry.*

Methods: *A systematic review using Ovid and MEDLINE was conducted to identify papers showing the uses of fluoroscopy in dentistry published between 1953 and September 2009. Human, animal and phantom/skull/mannequin studies on fluoroscopy with regard to its diagnostic value, research performance, and clinical and safety applications in dentistry were included in this analysis. Studies that were not in English, as well as those that employed fluoroscopy in dentistry without the use of image intensification, were excluded. Articles were evaluated, classified and graded by levels of evidence.*

Results: *Fifty-five out of 139 papers fulfilled the inclusion criteria. Amongst them, 19 were related to diagnosis, 15 to research, 12 to clinical and nine to safety applications. Fluoroscopy has contributed to nine different areas of dentistry. Also, it was used on 895 dental patients, 37 animals and 17 phantoms/skulls/mannequins. Two randomised controlled trials, two cohort studies, two case controls, 48 case reports and one expert opinion were found.*

Conclusion: *Fluoroscopy with image intensification has been a useful, but not consistently used tool in dentistry for over 50 years. Several lines of evidence have shown fluoroscopy's diagnostic potential, research use, and clinical and safety applications in dentistry.*

Key words: *fluoroscopy, radiology, systematic review, evidence-based dentistry, dental imaging*

Dentistry has always focused on improving dental diagnosis and treatment through the use of the latest available technology. In this regard, radiography was incorporated very early on, and this trend continued with the emergence of new technologies such as computed tomography (CT), digital radiography and cone beam CT^{1,2,3}. In contrast, fluoroscopy, a widely

used diagnostic tool that allows for the acquisition of continuous radiographic images for medical use, has not been definitively adopted in dentistry. Fluoroscopy is a dynamic radiograph, or radiographic movie, and differs from conventional dental radiography which is static. While physicians can observe these live imaging events, dentists' only possibility of monitoring treatment progress is by making radiographs before and after the procedure. As a result, craniofacial surgeries, endodontic treatments and conventional dental implant placement are invariably 'blind' procedures⁴. In addition, in order to avoid excessive radiation dosage, dentists have to leave the patient and stand 6.5 feet or more from the tube housing assembly while using currently available dental x-ray devices⁵.

These problems have been solved in the medical field through the introduction of the medical fluoroscope or C-arm. It has allowed physicians to 'see'

1 Kornberg School of Dentistry, Department of Endodontology at Temple University, Philadelphia, PA, USA.

2 Kornberg School of Dentistry, Department of Oral and Maxillofacial Pathology, Medicine and Surgery at Temple University, Philadelphia, PA, USA.

3 Department of Periodontics at Medical College of Georgia School of Dentistry, Augusta, GA, USA.

Corresponding author: Dr Daniel Uzelger Feldman, Kornberg School of Dentistry, Department of Endodontology at Temple University, 3223 North Broad Street, Philadelphia, PA 19140. Tel: 215-707-2948; Fax: 215-707-1482. E-mail: duzelger@dental.temple.edu

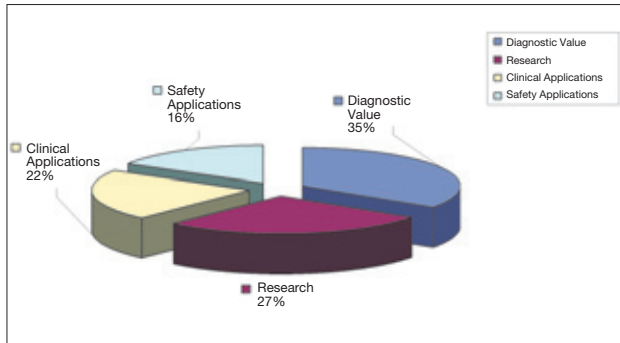


Fig 1 Uses of fluoroscopy in dentistry.

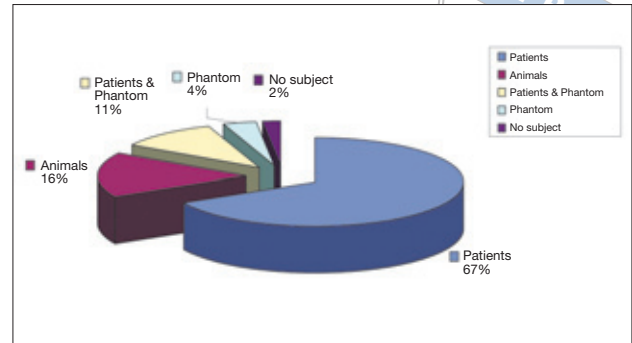


Fig 2 Fluoroscopy subject types used in dentistry.

their work while they work, allowing them to work easier and faster while staying there with the patient⁶. Fluoroscopy of the chest, blood vessels, digestive tract, urinary tract or reproductive tract is routinely performed in hospitals. In-office fluoroscopy has helped to fulfil a growing demand for minimally invasive procedures in traumatology, orthopaedics, endoscopy, pulmonology, paediatrics and urgent care medicine⁷. Today, fluoroscopy (medical fluoroscopes, C-arms and mini C-arms) accounts for 35% of the medical imaging market⁸.

In dentistry, William H Rollins described an early fluoroscope through which a dentist could observe portions of the oral cavity. Rollins' fluoroscope was not used in dentistry routinely. One major reason for that was the high level of radiation received by the patient while using these early fluoroscopes as well as the device's size and poor image resolution. However, since the introduction of image intensifying principles in 1942, and the first image intensification unit in 1953, the harmful effects of radiation have been considerably reduced^{9,10}. An image intensifier, in combination with the use of low milliamperage (mA) levels, lowers patient and operator dose, provides dynamic real-time imaging and allows the operator to position the patient to visualise anatomy and pathology of interest. Video images recorded this way or by digital detectors are stored in a computer, where they can be viewed on a monitor in real time or printed to film. To keep the radiation dose from becoming a health hazard, the exposure rate in fluoroscopic image intensification is several orders of magnitude lower than in radiography¹¹.

Fluoroscopy has been widely used in the medical field for more than 100 years now; however, the evidence of the contribution of fluoroscopy to dentistry has never been assessed⁴. The aim of this study was to determine the quality of the evidence for the uses of fluoroscopy in dentistry after the introduction of image intensification in 1953 with regard to its diagnostic value, research performance, and clinical and safety applications.

Materials and methods

A comprehensive search was conducted to identify studies on dental fluoroscopy published from 1953 to September 2009. Two reviewers used Ovid MEDLINE in-process, and other non-indexed citations in Ovid MEDLINE, and a manual search to retrieve abstracts and published papers. Combinations of the following medical subject headings were used: fluoroscopy, video-fluoroscopy, videofluorography, videoradiography, cineradiography, cineradiographic, cinefluorography, photofluorography, dental and dentistry. No efforts were made to identify unpublished studies. Duplicate references were removed. Using this method, 139 papers were selected for the review. The studies were then reviewed for inclusion based on the following inclusion criteria: (i) human, animal and phantom/skull/mannequin studies on fluoroscopy concerning its diagnostic value, research performance and clinical and safety applications in dentistry and (ii) intraoral and extraoral fluoroscopy modalities. Exclusion criteria were: (i) studies that were not in English and (ii) studies that employed fluoroscopy in dentistry without the use of image intensification. The selection of papers, decisions about eligibility and data extraction were conducted independently by three reviewers: one endodontist, one periodontist and one oral and maxillofacial radiologist. References retrieved from the search were screened and the articles were classified by levels of evidence (LOE) as follows: (1) randomised control trials (RCTs), meta-analyses or systematic reviews of RCTs; (2) cohort studies, systematic reviews of cohort studies and outcomes research; (3) case-control studies and systematic reviews of case-control studies; (4) poor-quality cohort and case-control studies and case series and (5) case reports and expert opinion without explicit critical appraisal¹².

Results

Among the 139 reviewed articles, 84 did not fulfil the inclusion criteria. Of the 55 articles selected, 19 studies were related to fluoroscopy’s diagnostic value¹³⁻³¹, 15 to research performance³²⁻⁴⁶, 12 to clinical applications⁴⁷⁻⁵⁸ and nine to safety⁵⁹⁻⁶⁷ in dentistry (Fig 1). Also, the fluoroscopy subject type used in dentistry can be seen in Figure 2 for a total of 895 dental patients, 37 animals and 17 phantoms/skulls/mannequins. Additionally, 12 papers were associated with prosthodontics^{23,28,30,34,47,49-53,55,56}, 12 with orthodontics^{16-21,26,27,36,43,54,59}, nine with oral and maxillofacial surgery^{13,24,29,31,46,48,57,58,62}, eight with radiology^{14,15,60,61,63-65,67}, eight with oral biology^{33,35,37,39-42,44}, two with endodontics^{45,66}, two with oral anatomy^{32,38}, one with paedodontics²⁵ and one with forensic dentistry²² (Fig 3). Only four studies^{62-64,66} out of 55 used intraoral fluoroscopy (Fig 4). There were no disagreements during the selection of the studies in the review. With regard to levels of evidence, two articles were RCTs^{23,43}, two cohort studies^{26,67}, two case controls^{30,48}, 48 case report studies^{13-21,24,25,27-29,31-42,44-47,49-66}, and one expert opinion report without explicit critical appraisal and literature review²² (Table 1).

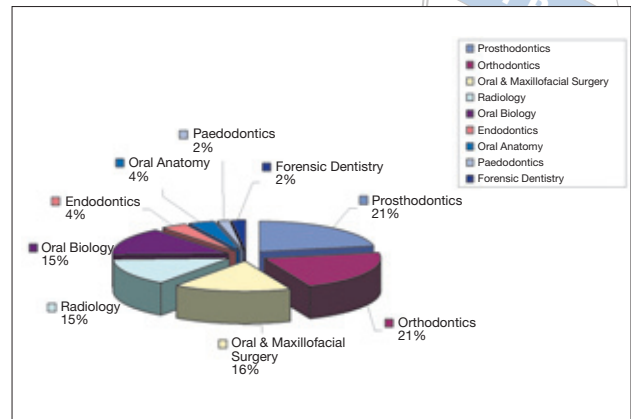


Fig 3 Uses of fluoroscopy according to dental specialty.

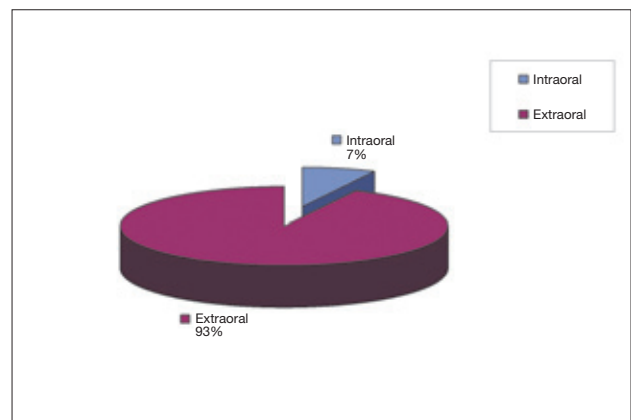


Fig 4 Fluoroscopy modalities used in dentistry.

Table 1 The use of fluoroscopy in dentistry: levels of evidence (LOE).

LOE	Type of study	Number of studies
1	Randomised controlled trials (RCTs) / systematic reviews	2
2	Low-quality RCTs / cohort studies	2
3	Case-control studies (CCS) / systematic reviews of CCS	2
4	Poor quality cohort and CCS / case series	48
5	Expert opinion without explicit critical appraisal	1
Total		55

Discussion

This paper presents a systematic review of the design and quality of studies published on the uses of fluoroscopy in dentistry with regard to its diagnostic value, research performance, and clinical and safety applications since the introduction of image intensification. Fluoroscopy has been an aid for diagnosis in several areas of dentistry such as prosthodontics, orthodontics, radiology, oral and maxillofacial surgery, paedodontics and forensic dentistry. For instance, it has been useful during functional evaluation of malocclusions²⁷; determination of diagnostic errors in condylar position throughout mandibular movements²⁸; development of a minimally invasive incision during palatopharyngoplasty procedures²⁹; information retrieval about oral, velopharyngeal and esophageal function during swallowing for prosthetic treatment purposes³⁰ as well as an evaluation method for diagnosing dysphagia³¹.

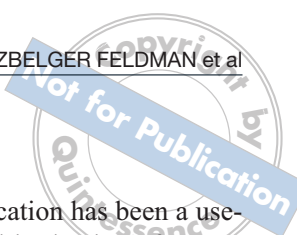
The preferred areas for the contributions of fluoroscopy in dental research were oral biology, oral and maxillofacial surgery, endodontics and the study of the masticatory cycle³²⁻⁴⁴. A root canal treatment on a zoo tiger showed the potential of fluoroscopy to provide an immediate image of the tooth in endodontics⁴⁵. Recently, a microfocus x-ray fluoroscope and microfocus x-ray CT techniques provided a clear and distinguishable image of the bone-implant interface due to their high spatial resolution⁴⁶.

During the 60s and 70s, fluoroscopy had clinical applications in prosthodontics, orthodontics, oral and maxillofacial surgery and oral anatomy for the study of physiological and non-physiological movements of the oral cavity. This knowledge has had direct implications on the design of removable and fixed prostheses. Fluoroscopy has also contributed to the management of temporomandibular joint disorders⁴⁷⁻⁵⁴. In addition, it determined the meniscus-condyle position in real time⁵⁵. The clinical use of fluoroscopy in oral surgery was demonstrated in two studies. Yoshino et al used it as an aid in the removal of stones obstructing the ducts of salivary glands. The device helped the surgeons find and remove the stones while being able to watch them through the ducts⁵⁷. Recently, Thompson et al demonstrated that fluoroscopy can be a useful technique in locating foreign bodies within head and neck tissues. As a result, surgeons were able to find and remove broken dental needles in the oral cavity⁵⁸.

Fluoroscopy's safety has been demonstrated in several studies that measured its radiation dosage and compared it with the existing dental technologies during the 50s, 60s and 70s⁵⁹⁻⁶⁴. The most recent papers

from the 80s showed that the lower radiation exposure required by the fluoroscopic system allowed motion studies which provided far more diagnostic information than still radiographs. Fluoroscopy has allowed for a reduction in patient exposure one hundred times lower than the average intraoral dental radiographs⁶⁵. In this regard, Saito et al showed that the risk of radiation exposure to the crystalline lens and the thyroid gland was negligible due to the extremely low radiation dosages used in fluoroscopy⁶⁶. Recently, Uzelger showed that fluoroscopy allowed an increase in the exposure time without increasing the dose equivalent of radiation received by the skull due to its low mA settings and the use of image intensification. This is in contrast to digital dental imaging and intraoral radiography⁶⁷.

Today, fluoroscopy not only has applications in the field of medicine to minimise radiation dosage, save working time, and prevent procedural accidents, but it is also useful to physiotherapists, veterinarians, criminologists, the army and airport security^{9,54}. Despite its early introduction to dentistry in 1896, the use of fluoroscopy in this profession has been inconsistent over the last 55 years due to radiation dosage concerns and the large size and low resolution of the devices used⁴. The major concerns about the use of ionising radiation in dentistry are the carcinogenic potential and the adverse effect upon living tissues⁶⁸. Over the years, dentists have been investigating how to reduce the radiation dose produced by the dental x-ray apparatus and the x-ray beam intensity. These studies have been focused on the reduction of the kVp, the use of high-speed films and the introduction of digital dental imaging. When compared to film-based dental radiography, the digital sensor offers the advantage of decreasing exposure time and as a result reduces radiation dosage. However, both the kVp and the mA settings have remained constant in both film-based and digital dental imaging systems^{2,69-75}. Despite all of these efforts, the mA range has not been taken into consideration in any of the attempts at reducing the radiation dose to which dental patients are being exposed. The quantity, or number of x-rays emitted from the tube head, is controlled by the mA. Milliamperage and exposure time are inversely related. When mA is decreased, the exposure time can be increased⁷⁶. In comparison to film-based and dental digital radiography, fluoroscopy uses very low mA settings as well as image intensification. As a result, low dose radiographic movies are made up to 5 minutes continuously without resetting⁸. On average, physicians use 51 seconds of fluoroscopy time per case, ranging from 6 seconds to 170 seconds⁷⁷. In addition, the physician's team is exposed to minimal radiation



during routine use of mini C-arm fluoroscopy, except when they are in the direct path of the radiation beam⁷⁸. Due to this technology's large medical background, in dentistry, the use of fluoroscopy with image intensification is approved in 28 US states while 11 US states have not ruled yet on its use. Intraoral fluoroscopy is disapproved in 11 US states⁷⁹.

Device size and image resolution have been important concerns for the adoption of fluoroscopy within dentistry. Thus, the medical fluoroscope, C-arm and mini C-arm are too large to fit in a dental office. In addition, digital resolution has not been available during past decades. However, new technological advances may improve its size and portability, safety, digital resolution and consequently its applications. With these developments, implant dentistry and endodontics are some emerging areas for fluoroscopy's potential use in clinical applications and research.

With regard to these future perspectives, to date, no clinical applications of fluoroscopy have been published in implant dentistry. The possibility of observing in real time the anatomical location of the drills within bone structures during surgical procedures has the potential to minimise clinical accidents. For instance, fluoroscopy could be used to establish the best drilling depth in order to avoid mandibular nerve damage or the best drilling position in order to avoid sinus perforation. In endodontics, fluoroscopy could be useful for finding access through crowns, bridges, and tilted and rotated teeth; finding calcified canals; negotiating canal curvatures; bypassing separated instruments; preventing procedural accidents such as canal transportation as well as performing minimally invasive surgical procedures and apicoectomies. For research purposes, it would be interesting to compare fluoroscopy not only to intraoral film-based and digital radiography but also to cone beam CT scans and panoramic x-rays in terms of radiation dosage. Further studies should include thermoluminescent dosimeters or ionisation chambers rather than film badge dosimeters for radiation measurements. Also, fluoroscopy's applications could be compared with non-radiation producing technologies such as optical coherence tomography, magnetic resonance imaging and ultrasound⁸⁰⁻⁸². Moreover, it appears that few high-level studies have been published in the past five decades related to the contributions of fluoroscopy to dentistry. The authors would like to emphasise the need for more randomised controlled trials and cohort studies with meaningful results and statistical analysis on dental fluoroscopy since most previous studies have been case reports.

Conclusions

Fluoroscopy with image intensification has been a useful, but not consistently used tool in dentistry for over 50 years. Several lines of evidence have demonstrated fluoroscopy's contribution to the dental profession by showing its diagnostic potential, research use and clinical and safety applications. Its main drawbacks have been the size and image resolution of the device. Nevertheless, recent advances in imaging devices could significantly increase the contributions of fluoroscopy in the near future by developing a safe technology that allows continuous or dynamic radiographic imaging for dental use. More research is needed to demonstrate this further.

Acknowledgements

The authors appreciate William J Dobkowsky's help for retrieving the papers and abstracts as well as Dr Larry Koren's and Dr Adam Bergman's review of the English.

References

1. Ames JR, Johnson RP, Stevens EA. Computerized tomography in oral and maxillofacial surgery. *J Oral Surg* 1980;38:145-149.
2. Mouyen F, Benz C, Sonnabend E, Lodter JP. Presentation and physical evaluation of RadioVisioGraphy. *Oral Surg Oral Med Oral Pathol* 1989;68:238-242.
3. Mozzo P, Procacci C, Tacconi A, Martini PT, Andreis IA. A new volumetric CT machine for dental imaging based on the cone-beam technique: preliminary results. *Eur Radiol* 1998;8:1558-1564.
4. Uzelger-Feldman D, Susin C, Yang J. The use of fluoroscopy in dentistry: a systematic review. *Oral Surg Oral Med Oral Pathol Oral Radiol Endod* 2008;105:e61.
5. American Dental Association. ANSI/ADA Specification No. 26. 1999.
6. Adler AN, Carlton RR. Introduction to radiologic sciences and patient care, ed 3. Philadelphia: Saunders, 2003:78-90.
7. Blinov NN, Mazurov AI. An analysis of the outlook for using C-arm-type mobile x-ray diagnostic apparatus. *Med Tekh* 2000;5:19-23.
8. U.S. Food and Drug Administration. 21 C.F.R. Part 1020. Federal Register. Electronic Products; Performance Standard for Diagnostic X-ray Systems and Their Major Components; Final Rule. 2005;70:33998-34042.
9. Eisenberg RL. Radiology: An illustrated history. St Louis: Mosby-Year Book, 1992:51-78.
10. Chamberlain WE. Fluoroscopes and fluoroscopy. *Radiology* 1942;38:383-413.
11. Carroll QB, Fuchs AW. Fuchs's Radiographic Exposure and Quality Control, ed 7. Springfield, IL: Charles C Thomas Publisher, 2003:451-469.
12. Torabinejad M, Bahjri K. Essential elements of evidenced-based endodontics: steps involved in conducting clinical research. *J Endod* 2005;31:563-569.
13. Berry HM Jr, Hofmann FA. Cinefluorography with image intensification for observing temporomandibular joint movements. *J Am Dent Assoc* 1956;53:517-527.

14. Dolowy WC, Yale SH. Stereoscopic projection of 35 mm still slides made by cinefluorography. *Oral Surg Oral Med Oral Pathol* 1962;15:1450-1452.
15. Sloan RF, Ricketts RM, Brummett SW, Bench RW, Westover JL. Quantified cinefluorographic techniques used in oral roentgenology. *Oral Surg Oral Med Oral Pathol* 1965;20:456-463.
16. Jensen R. Anterior teeth relationship and speech. Studies using cineradiography synchronized with speech recording. *Acta Radiol Diagn (Stockh)* 1968;Suppl 276:1+.
17. Vig P. Cinedots: a new method of cineradiographic analysis. *Dent Pract Dent Rec* 1969;20:28-34.
18. Subtelny JD. Malocclusions, orthodontic corrections and orofacial muscle adaptation. *Angle Orthod* 1970;40:170-201.
19. Milne IM, Cleall JF. Cinefluorographic study of functional adaptation of the oropharyngeal structures. *Angle Orthod* 1970;40:267-283.
20. Subtelny JD, Subtelny JD. Oral habits studies in form, function, and therapy. *Angle Orthod* 1973;43:349-383.
21. Beaton WD, Cleall JF. Cinefluorographic and cephalometric study of Class I acceptable occlusion. *Am J Orthod* 1973;64:469-479.
22. Besant-Matthews PE. Medical aspects of forensic medicine and dentistry. *Dent Clin North Am* 1977;21:33-45.
23. Karlsson S. Cineradiography in odontology. *Swed Dent J Suppl* 1979;4:1-63.
24. Caouette-Laberge L, Egerszegi EP, de Remont AM, Ottensey I. Long-term follow-up after division of a pharyngeal flap for severe nasal obstruction. *Cleft Palate Craniofac J* 1992;29:27-31.
25. Edwards M, Ashwood RA, Littlewood SJ, Brocklebank LM, Fung DE. A videofluoroscopic comparison of straw and cup drinking: the potential influence on dental erosion. *Br Dent J* 1998;185:244-249.
26. Fujiki T, Inoue M, Miyawaki S, Nagasaki T, Tanimoto K, Takano-Yamamoto T. Relationship between maxillofacial morphology and deglutitive tongue movement in patients with anterior open bite. *Am J Orthod Dentofac Orthop* 2004;125:160-167.
27. Cleall JF, BeGole EA. Diagnosis and treatment of class II division 2 malocclusion. *Angle Orthod* 1982;52:38-60.
28. Preti G, Fava C. Lateral transcranial radiography of temporomandibular joints. Part I: Validity in skulls and patients. *J Prosthet Dent* 1988;59:85-93.
29. Mendoza M, Molina F, Azzolini C, Ysunza Rivera A. Minimal incision palatopharyngoplasty. A preliminary report. *Scand J Plast Reconstr Surg Hand Surg* 1994 Sep;28:199-205.
30. Light J, Edelman SB, Alba A. The dental prosthesis used for intraoral muscle therapy in the rehabilitation of the stroke patient. A preliminary research study. *N Y State Dent J* 2001;67:22-27.
31. Tamura F, Ayano R, Haishima H, Ishida R, Mizukami M, Mukai Y. Distribution of causes and treatments of dysphagia at dysphasia/dysphagia rehabilitation clinic of Showa University Dental Hospital: 1999-2002. *Int J Orofacial Myology* 2004;30:53-62.
32. Hiiemae KM. Masticatory function in the mammals. *J Dent Res* 1967;46:883-893.
33. Crompton AW, Hiiemae K. Functional occlusion in tribosphenic molars. *Nature* 1969;222:678-679.
34. Hedegard B, Lundberg M, Wictorin L. Masticatory function--a cineradiographic study. IV. Duration of the masticatory cycle. *Acta Odontol Scand* 1970;28:859-865.
35. Carney PJ, Morris HL. Structural correlates of nasality. *Cleft Palate J* 1971;8:307-21.
36. Carlsson GE, Bratt CM, Helkimo M, Ingervall B. The rest position of the mandible. Cineradiographic study of registration of the temporomandibular joint capsule with and without anesthesia. *Dtsch Zahnratl Z* 1973;28:443-446.
37. Robins MW. Circadian pattern of the use of the incisor teeth by laboratory rats. *Arch Oral Biol* 1973;18:641-645.
38. Takano K. Studies on the morphological changes of the buccal mucous membrane during mastication by X-ray TV cinematography. *Shikwa Gakuho* 1979;79:1361-1453.
39. Hylander WL, Crompton AW. Jaw movements and patterns of mandibular bone strain during mastication in the monkey *Macaca fascicularis*. *Arch Oral Biol* 1986;31:841-848.
40. Thexton A, Hiiemae KM. The effect of food consistency upon jaw movement in the macaque: a cineradiographic study. *J Dent Res* 1997;76:552-560.
41. Palmer JB, Hiiemae KM, Liu J. Tongue-jaw linkages in human feeding: a preliminary videofluorographic study. *Arch Oral Biol* 1997;42:429-441.
42. Herrel A, Vree FD. Kinematics of intraoral transport and swallowing in the herbivorous lizard *Uromastix acanthinurus*. *J Exp Biol* 1999;202:1127-1137.
43. Sindelar BJ, Edwards S, Herring SW. Morphologic changes in the TMJ following splint wear. *Anat Rec* 2002;266:167-176.
44. Mioche L, Hiiemae KM, Palmer JB. A postero-anterior videofluorographic study of the intra-oral management of food in man. *Arch Oral Biol* 2002;47:267-280.
45. DeForge DH, Golden AL. Use of videofluoroscopy in zoo dentistry: endodontic procedure in a tiger. *J Vet Dent* 1997;14:31-33.
46. Kiba H, Hayakawa T, Oba S, Kuwabara M, Habata I, Yamamoto H. Potential application of high-resolution microfocus X-ray techniques for observation of bone structure and bone-implant interface. *Int J Oral Maxillofac Implants* 2003;18:279-285.
47. Behrman SJ. Magnets implanted in the mandible: Aid to denture retention. *J Am Dent Assoc* 1964;68:206-215.
48. Mazaheri M, Millard RT, Erickson DM. Cineradiographic comparison of normal to noncleft subjects with velopharyngeal inadequacy. *Cleft Palate J* 1964;12:199-209.
49. Modica R, Juliani G, Ragni G. Radiographic and cinematographic analysis of the masticatory movements in normal occlusion and in some dysgnathias. *Mondo Odontostomatol* 1968;10:213-234.
50. Laird WR. Application of videofluorography in prosthetic dentistry. A preliminary report. *Glasg Dent J* 1973;4:16-18.
51. Preti G. Roengenocinematographic studies on the stability of the total prosthesis during mastication. *SSO Schweiz Monatsschr Zahnheilkd* 1976;86:1070-1082.
52. Sheppard IM, Sheppard SM. The relationship of vertical dimension of atypical swallowing with complete dentures. *J Prosthet Dent* 1977;38:249-253.
53. Laird WR. Swallowing and denture occlusion. *J Prosthet Dent* 1978;40:614-618.
54. Miotti AM. Mandibular prognathism: a cineradiographic analysis of mandibular and hyoid bone movements before and after surgical correction. *Am J Orthod* 1982;82:310-317.
55. Tallents RH, Katzberg RW, Miller TL, Manzione JV, Oster C. Arthrographically assisted splint therapy. *J Prosthet Dent* 1985;53:235-238.
56. Jooste CH, Thomas CJ. Complete mandibular denture stability when posterior teeth are placed over a basal tissue incline. *J Oral Rehabil* 1992;19:441-448.
57. Yoshino N, Hosokawa A, Sasaki T, Yoshioka T. Interventional radiology for the non-surgical removal of sialoliths. *Dentomaxillofac Radiol* 1996;25:242-246.
58. Thompson M, Wright S, Cheng LH, Starr D. Locating broken dental needles. *Int J Oral Maxillofac Surg* 2003;32:642-644.
59. Cooper HK, Hofmann FA. The application of cinefluorography with image intensification in the field of plastic surgery, dentistry and speech. *Plast Reconstr Surg* 1955;16:135-137.
60. Berry HM, Hofmann FA. Preliminary work on cinefluorography with image intensifier in the study of the temporomandibular joint. *Oral Surg Oral Med Oral Pathol* 1957;10:63-68.

61. Smith NJ, Heighway WP. Patient dose in dental cinefluorography. *Oral Surg Oral Med Oral Pathol* 1969;27:349-357.
62. Carver GT. Intra-oral fluoroscope developed at UODS. *Dent Angles* 1969;10:3-4.
63. Savara BS, Parker WL, Irwin JW. Intraoral fluoroscopy at low radiation levels. *Oral Surg Oral Med Oral Pathol* 1970;30:639-645.
64. Ando S, Shinoda K, Noikura T, Inaba K. Real-time radiological survey by intraoral fluoroscopic TV system to minimize radiation dose. *Dentomaxillofac Radiol* 1979;8:57-63.
65. Berry HM Jr, Hofmann FA. A synchronized biplane videoradiographic system employing image manipulation for improved diagnosis and dose reduction. *Oral Surg Oral Med Oral Pathol* 1981;52:657-660.
66. Saito J. Studies for dental fluorographic imaging system (Dentalux): fundamental characteristics in endodontic practice. *Kanagawa Shigaku* 1987;21:567-582.
67. Uzelger D. Comparison between medical fluoroscopy, digital dental imaging and intraoral radiography. Presented at the IADR/AADR/CADR 83rd General Session, Baltimore, 10 March 2005.
68. Torabinejad M, Danforth R, Andrews K, Chan Ch. Absorbed radiation by various tissues during simulated endodontic radiography. *J Endod* 1989;15:249-253.
69. Hayakawa Y, Farman AG, Scarfe WC, Kuroyanagi K, Rumack PM, Schick DB. Optimum exposure ranges for computed dental radiography. *Dentomaxillofac Radiol* 1996;25:71-75.
70. Geist JR, Brand JW. Sensitometric comparison of speed group E and F dental radiographic films. *Dentomaxillofac Radiol* 2001;30:147-152.
71. Goren A, Bonvento M, Biernacki J, Colosi D. Radiation exposure with the NOMADTM portable X-ray system. *Dentomaxillofac Radiol* 2008;37:109-112.
72. Farman AG, Levato CM, Gane D, Scarfe WC. In practice: how going digital will affect the dental office. *J Am Dent Assoc* 2008;139 Suppl:14S-19S.
73. Miles DA. The future of dental and maxillofacial imaging. *Dent Clin North Am* 2008;52:917-928, viii.
74. Roberts JA, Drage NA, Davies J, Thomas DW. Effective dose from cone beam CT examinations in dentistry. *Br J Radiol* 2009;82:35-40.
75. Kim IH, Mupparapu M. Dental radiographic guidelines: a review. *Quintessence Int* 2009;40:389-398.
76. Haring JI, Jansen L. *Dental radiography. Principles and techniques*, ed 2. Philadelphia: Saunders, 2000:35-43.
77. Singer G. Radiation exposure to the hands from mini C-arm fluoroscopy. *J Hand Surg Am* 2005;30:795-797.
78. Giordano BD, Ryder S, Baumhauer JF, DiGiovanni BF. Exposure to direct and scatter radiation with use of mini-c-arm fluoroscopy. *J Bone Joint Surg Am* 2007;89:948-952.
79. U.S. Nuclear Regulatory Authority. Federal & State Materials & Environmental Management. Available at: <http://nrc-stp.omn.gov/>. Accessed 10 May 2010.
80. Shemesh H, van Soest G, Wu MK, Wesselink PR. Diagnosis of vertical root fractures with optical coherence tomography. *J Endod* 2008;34:739-742.
81. Lee SH, Yoon HJ. MRI findings of patients with temporomandibular joint internal derangement: before and after performance of arthrocentesis and stabilization splint. *J Oral Maxillofac Surg* 2009;67:314-317.
82. Aggarwal V, Logani A, Shah N. The evaluation of computed tomography scans and ultrasounds in the differential diagnosis of periapical lesions. *J Endod* 2008;34:1312-1315.