

# Idiopathic progressive condylar resorption



## Question

What are the clinical signs and possible causes of idiopathic progressive condylar resorption?

## Background

The term „idiopathic progressive condylar resorption“ has appeared in literature since the late 1990s [38]. It is a rare disease that involves the resorption of the mandibular condyle and it is accompanied by a progressive change of the bite position towards an Angle Class II [2, 3, 30, 46]. In the majority of cases, both condyles are affected [49]. The patient group consists mainly of young women subsequent to orthodontic or surgical treatment. The average age is 20.5 years [2].

Two forms of idiopathic condylar resorption can be distinguished:

- after the end of condylar growth in adulthood,
- during the growth phase in adolescents in which the growth rate of the condyle is restricted.

As seen on an X-ray, the mandibular condyle shows changes superiorly or anterior-superiorly (Fig. 1), but other condylar areas may also be affected. In the course of the disease, the shape of the condyle flattens; more pointed shapes are also found. On the other hand, the progressive destruction of the entire bone and an inflammatory infiltrate (articular effusion), which are typical of rheumatoid arthritis, as well as, typical repair processes with sclerosis, osteophytes (duckbill shape), or subcortical cysts, which are common in spondylitis

and psoriatic arthritis are rarely found [49]. Wolford estimates the condylar height loss to be approximately 1.5 mm/year [46]. However, the resorption of the condyle at the level of the condylar neck seems to come to a standstill in the course of the disease. As the overall height of the ascending mandibular ramus is reduced by resorption, the occlusal surfaces of the distal molars occlude prematurely during jaw closure. This premature contact acts like a lever arm; it opens the bite anteriorly and increasingly shifts the mandible towards an Angle Class II, or distocclusion [49] (Fig. 2). The clinical symptoms described by the patients vary. In addition to pain in the immediate area of the affected joint, patients complain about discomfort in the masticatory muscles and joint sounds. Cracking sounds due to disc displacement are present in some cases, as are crepitation noises.

With respect to the differential diagnosis of idiopathic condylar resorption, it is distinguished from:

- bite openings due to parafunctions in the context of „bad habits“ such as thumb-sucking or malfunctions of the tongue,
- bite openings due to wearing splints with an anterior bite block (anterior bite splints),
- bite openings in the context of advanced periodontitis („flaring“),
- congenital syndromes with condylar hypoplasia, e.g. Goldenhar syndrome [9], Treacher-Collins syndrome [1], or acrofacial dysostosis [14],

- iatrogenic bite openings, e.g. temporary in the course of orthodontic therapy,
- juvenile arthritis – patients < 16 years of age with fever, skin rash, arthritis, and mostly negative rheumatoid factors [35],
- osteoarthritis and rheumatic diseases [42],
- osteoarthritis of the temporomandibular joints (no origin in rheumatic disease),
- rachitic open bite (vitamin D deficiency),
- tumor diseases.

The diagnosis is based on a diagnosis of exclusion (collaboration with rheumatologists, internists [endocrinologists], and other specialists), imaging, medical history, and collected clinical findings. MRIs or CT scans help to assess the extent of resorption in three dimensions. The estimation of the activity of the resorption process can be visualized using radio-nuclides (technetium methylene diphosphate, <sup>99m</sup>Tc-MCP) in single photon emission computed tomography (SPECT). This method requires a very strict indication in adolescent patients due to a radiation exposure of around 4–6 mSV [38].

## Etiology

The etiology of idiopathic condylar resorption is to a large extent unclear [2, 49]. The spectrum of possible causes includes all possible disturbances in bone metabolism and it ranges from endocrine, hormonal or systemic diseases to mechanical stress factors which influence the tempo-

Translation from German: Cristian Miron

Citation: Behr M, Fanghänel J, Proff P, Strasser T, Schmid A, Kirschneck C: Idiopathic progressive condylar resorption. Dtsch Zahnärztl Z Int 2021; 3: 4–15

DOI.org/10.3238/dzz-int.2021.0001

romandibular joint. These various potential causes are discussed in more detail below.

### Endocrine diseases

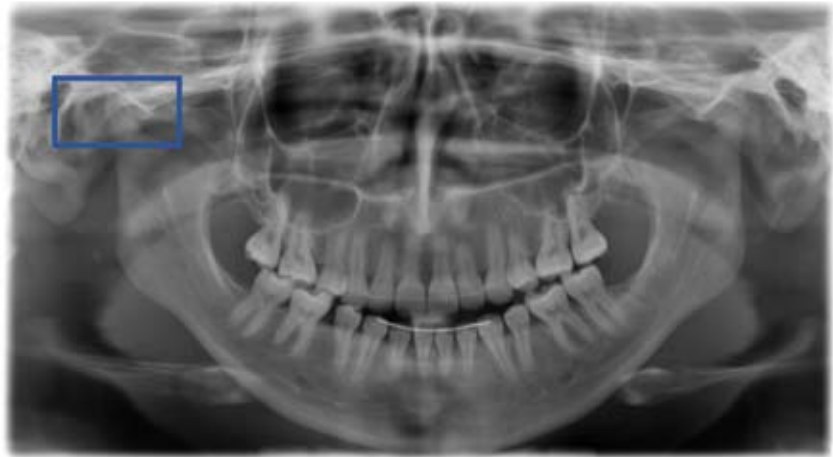Endocrine diseases, nutritional deficiencies (anorexia nervosa), infectious diseases, cardiovascular diseases with vascular involvement, excessive physical stress as well as autoimmune reactions lead to various vascular damages and vasculitides. Such vascular changes also affect the blood supply to the condylar bone and can lead to inflammatory metabolic states in bone and cartilage.

The possible hormonal influences that are considered in relation to idiopathic condylar resorption are:

- corticosteroids,
- estrogens,
- parathyroid hormone (hyperparathyroidism),
- prolactin.

### Hyperparathyroidism

Hyperparathyroidism, which is the excessive production and release of parathyroid hormone by the parathyroid glands, is considered to be a possible cause of idiopathic condylar resorption in literature [2]. However, it is unclear why this process would only affect the condyles of the temporomandibular joint in isolation and not other bone areas in the body. In the case of hyperparathyroidism, parathyroid hormone leads to an increased expression of the RANK ligand (RANKL, Receptor Activator of Nuclear Factor kappa B ligand) at the cell surface of osteoblasts and osteocytes or to its release as soluble RANKL. This RANK ligand binds to the RANK receptor of osteoclast precursor cells (preosteoclasts), which initiates their differentiation into mature, active osteoclasts that attach to the bone surface. So-called integrins in the cell membrane help to form a closed reaction space for the degradation of the inorganic and organic bone substance, the so-called Howship lacuna (Fig. 3). In this space, the pH is lowered by means of proton ATPases and the hydroxyapatite of the bone is dissolved [26]. The freed calcium and phosphate ions are released into the bloodstream. The release of antagonistic scavenger receptor, os-



**Figure 1** X-ray imaging of idiopathic condylar resorption. (Overall photo) Orthopantomogram of a patient with idiopathic condylar resorption. Blue frame: The X-ray on the right shows a section of the right mandibular condyle with anterior resorption of the condylar neck.

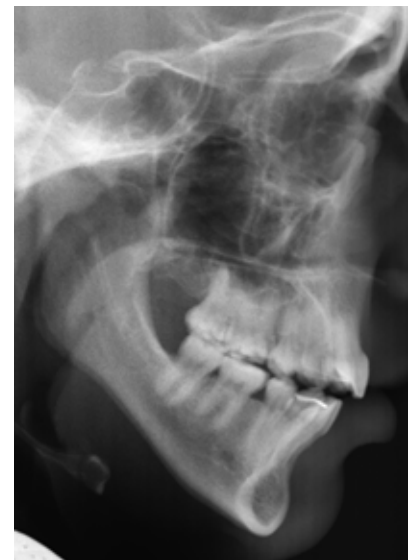teoprotegerin (OPG), by osteoblasts, among others, which binds to RANKL, can inhibit the binding of RANKL to the RANK receptor and thus regulate osteoclastogenesis (Fig. 3).

### Corticosteroids

High corticosteroid levels demineralize bone. They stimulate the expression of RANKL (Receptor Activator of Nuclear Factor kappa B ligand) by osteoblasts (Fig. 3) and simultaneously inhibit osteoprotegerin release. As a result, the osteoblast population decreases and the number of osteoclasts increases. The effect of corticosteroids therefore occurs indirectly due to osteoblast inhibition [26].

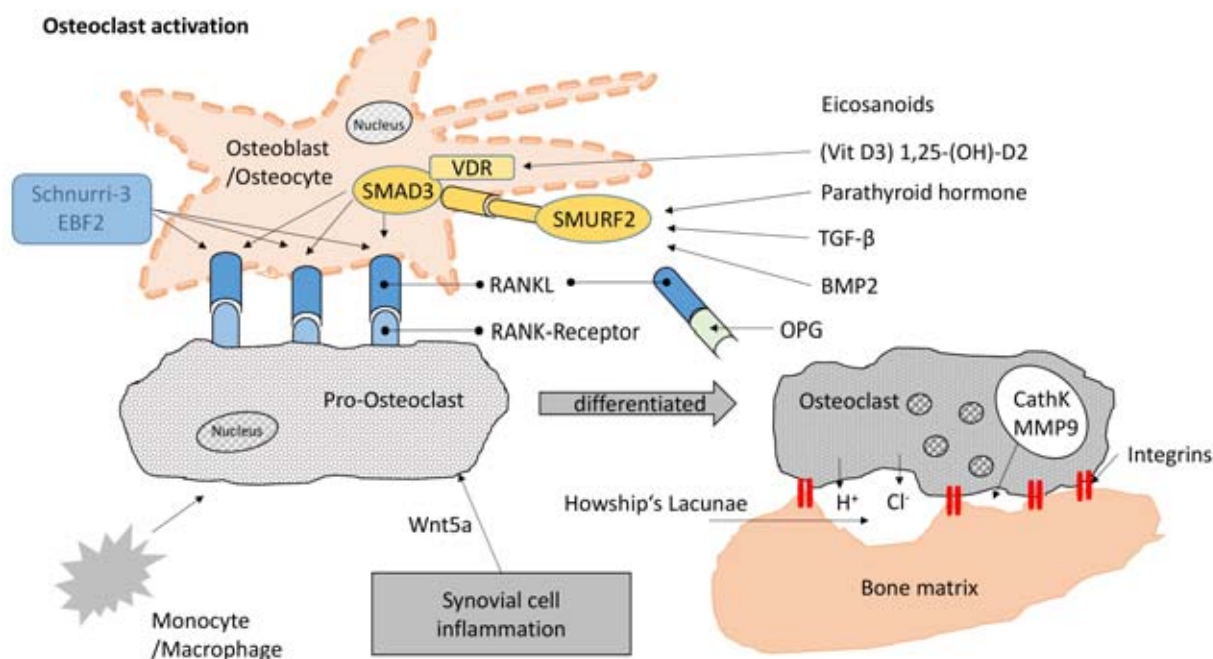
Furthermore, corticosteroids regulate various metalloproteinases (collagenases), which cleave the collagen fibrils of the bone matrix and lead to a reduction of the bone matrix. The missing matrix can no longer be mineralized [11]. In osteoblasts, corticosteroids counteract the growth factor IGF-1 (insulin-like-growth-factor-I). IGF-1 stimulates the synthesis of type I collagen in the bone matrix as well as the mineralization of the matrix [11].

Apparently, corticosteroids which are applied directly into the joint can initially “repair” the cartilage microstructure to some extent. However, after 14 days of therapy with dexa-



**Figure 2** Lateral cephalometric X-ray of a patient with idiopathic condylar resorption. Although the molars are in occlusion, skeletal open bite is present in the anterior region.

methasone, for example, thinned collagen fibers with a very diffuse fiber structure are seen in animal experiments [7, 19]. These structural changes in collagen fibers are more extensive when dexamethasone is applied than in untreated osteoarthritis [19]. Possible damage to cartilage and chondrocytes depends on the dose and frequency of corticosteroid administration as well as on the type of corticosteroid [7].



**Figure 3** Schematic of osteoclast activation. RANKL = receptor activator of nuclear factor- $\kappa$ B-ligand; OPG = osteoprotegerin; CathK = cathepsin K; MMP 9 = matrix metalloproteinase 9; VDR = nuclear vitamin D receptor; BMP = bone morphogenetic protein; SMADs comprise a family of proteins that are signal transducers for TGF- $\beta$  signaling; Schnurri: key regulator of osteoblasts; SMURF = SMAD3 specific E3 ubiquitin protein ligase; EBF is a transcription factor of early B-cells of a protein coding gene

### Prolactin

Prolactin is discussed as being another hormone that is responsible for the development of condylar resorption. [2]. The pituitary gland controls prolactin secretion. It is closely associated with estrogen metabolism. Prolactin stimulates the function of immune cells such as lymphocytes and macrophages, as well as, the release of cytokines, which in turn are involved in the breakdown of cartilage and bone.

### Estrogens

Disturbances in estrogen metabolism can also play a role in the etiology of idiopathic condylar resorption. Based on studies performed on the great apes, it is known that female animals have more estrogen receptors in the region of the temporomandibular joint, whereas males have fewer [29]. This fits the observation made by Tsai [44]; in the synovial fluid of inflamed knee joints, estrogen and estrogen receptors are found more frequently than in healthy joints. Estrogens inhibit the synthesis of cartilage cells and,

at the same time, promote the production of enzymes that degenerate the bone and cartilage matrix.

### Systemic diseases

Included among the possible systemic diseases which can be associated with idiopathic condylar resorption are:

- psoriatic arthritis,
- rheumatism,
- spondylopathies,
- other autoimmune diseases.

Many of these diseases can be identified by specific markers in the blood. As illustrated above, the rheumatic disease forms mostly show other radiological manifestations; at present, it must therefore be assumed that idiopathic condylar resorption represents an independent clinical picture.

### Mechanical causes

An important and possible chain of causation which can lead to the development of idiopathic condylar resorption are mechanical stress components such as:

- a change in occlusion (orthodontics, prosthetics),

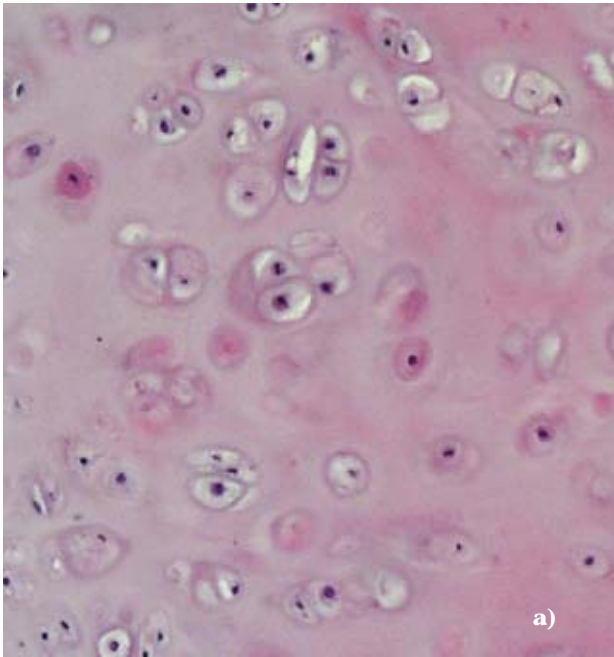
- parafunctions which damage the articular surfaces through mechanical load,
- traumas.

Mechanical stress is considered to be a possible cause of joint changes. The articular surfaces of physiologically functioning temporomandibular joints are largely load-free [6]. This is necessary in order to ensure that the ability of humans to speak through rapid, constantly changing movements of the lower jaw is retained. We know from animal experiments that a (normal) mechanical loading of the joint surfaces reduces or prevents the production and release of proteolytic enzymes in joints. Conversely, inactivity of a joint leads to the degradation of the articular cartilage [31]. Normal mechanical loading “protects” the joint surfaces.

Inflammatory processes in the temporomandibular joint can originate from 3 types of tissue: from cartilage, bone and cell structures of the synovial membrane.

### Articular cartilage

The temporomandibular joint contains hyaline cartilage on the condy-



(Fig. 4a, b: from B. Miehe; Institute of Anatomy and Cell Biology, University of Greifswald)

**Figure 4** Characteristics of cartilage cells of the temporomandibular joint: **a)** Cartilage cells with matrix. Hyaline cartilage in the cartilage layer of the mandibular fossa of the temporal bone. **b)** Fibrous cartilage of the articular disc. The collagen fibers are clearly visible.

lar process, in the mandibular fossa of the temporal bone and on the articular tubercle (Fig. 4a). The cartilage cells are scattered throughout the intercellular substance. The articular disc, on the other hand, consists of collagenous or fibrous cartilage (Fig. 4b). Unlike tissue structures, in which the cell walls lie close together, an extracellular matrix surrounds chondrocytes. In this way, each cell is separated from its neighboring cell. Both the cartilage capsule as well as the extracellular matrix are reinforced with fibrous structures. The magnitude of the load on the articulating surfaces determines the density and fiber reinforcement. A superficial fibrous layer with fibers arranged parallel to the articular surface, an intermediate layer having a fiber orientation in diverse spatial directions and a deep layer whose fibers run vertical to the articular surface and sprout into the mineralized subchondral zone of the bone can be distinguished [24]. Elastins, proteoglycans, hyaluronate and non-collagenous glycoproteins are the most important components of the extracellular matrix. Hyaluronic acid forms a scaffold to which proteoglycans with carbohydrate side chains attach to like plumage. Due to their hydrophilic character, the proteoglycans bind much water and, owing to their poly-

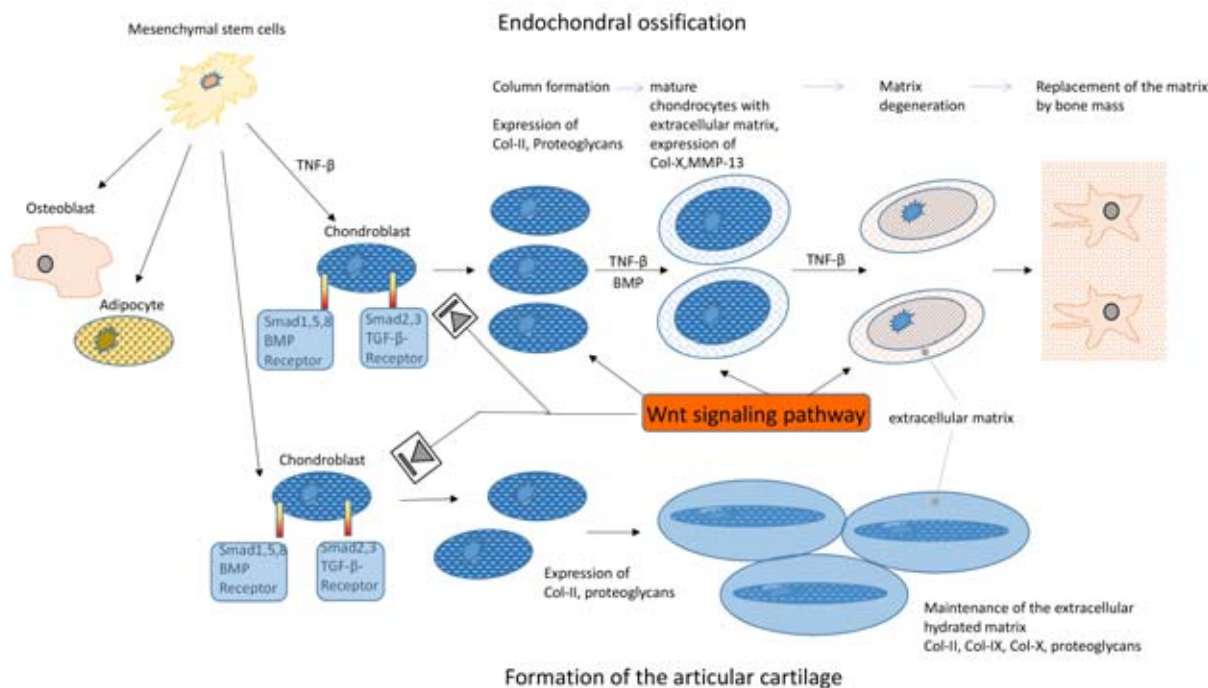
ionic structure, sodium, potassium, calcium and magnesium as well. Under load, the hydrophilic (fluid-rich) structures distribute the forces in the cartilage evenly, much like a cushion. Collagen fibers are intercalated between the proteoglycans for stabilization. The so-called non-collagenous proteins of the extracellular matrix include fibronectins and laminins among others. Fibronectins have the function of connecting together collagen fibrils. Special heterodimeric transmembrane proteins such as the classical fibronectin receptor  $\alpha 5\beta 1$  bind fibrinectin fragments (in the case of damages) and trigger growth factor gene expression via signal transduction in the chondrocyte. Laminins provide binding sites for collagen and glycosamines in the basement membrane region.

Cartilage cells develop differently depending on their future area of function. For instance, cartilage cells in the extremities progress through different developmental stages (Fig. 5). Initially, these cells form a cartilage matrix with type II collagen and proteoglycans. Afterwards, the cells mature into hypertrophic chondrocytes and express type X collagen. Finally, the hypertrophic chondrocytes differentiate. They secrete metalloproteinase-13 (MMP-13) so that the cartilage matrix is degraded

and increasingly replaced by bone substance. In this way, piece by piece, the cartilage is transformed into bone. In contrast to the chondrocytes of articular cartilage exhibit a low turnover rate. They do not participate in the maturation process described above up to the point of ossification. Rather, they acquire a flat spindle-shaped form and store collagen types I, IX and X in the matrix (Fig. 5). Due to a high proportion of proteoglycans, the extracellular matrix is hydrated. Thereby, the cartilage cells function like a cushion under load and they facilitate frictionless sliding of the joint surfaces [48].

In the case of osteoarthritis, the special cells of articular cartilage undergo the stages of further maturation irregularly and, consequently, of later extracellular matrix degeneration. Processes similar to those of enchondral ossification take place afterwards (Fig. 5). This results in a loss of articular cartilage and the formation of osteophytes.

Cartilage responds to physiological mechanical load by increasing metabolism through mechanotransduction. Mechanosensitive ion channels and receptors such as integrins, among others, are involved in registering the changes. Under tensile



**Figure 5** Differentiation of chondroblasts into chondrocytes. Development of chondrocytes during endochondral ossification and during specialization into articulating articular cartilage. Wnt (Wingless, Int-1), TNF-β (tumor necrosis factor β); Smad (intracellular proteins that relay extracellular TGF-β family signals from TGF receptors to the nucleus), MMP-13 (matrix metalloproteinase-13), BMP (bone morphogenetic protein), Col-II, IX, X (collagen type II, IX, X).

load, integrins and mechanosensitive ion channels promote the release of interleukin 4 and 10 (IL-4, IL-10) (Fig. 6). These interleukins increase the production of aggrecan (aggrecan binds H<sub>2</sub>O and gives cartilage its „shock-absorbing function“) and simultaneously reduce the expression of matrix metalloproteinase-3 (MMP-3, collagen-dissolving) as well as the transcription of NF-κB (nuclear factor „kappa-light-chain-enhancer“ of activated B-cells). Furthermore, IL-4 and IL-10 inhibit the expression of interleukin 1 (IL-1) and tumor necrosis factor α (TNF-α) [31] (Fig. 6). A joint which performs physiological movements is thus „metabolically protected“. Diseased joints also benefit from this. In osteoarthritic joints, regular exercise increases the expression of IL-10 and promotes „healing“ of the joint surfaces [4,31].

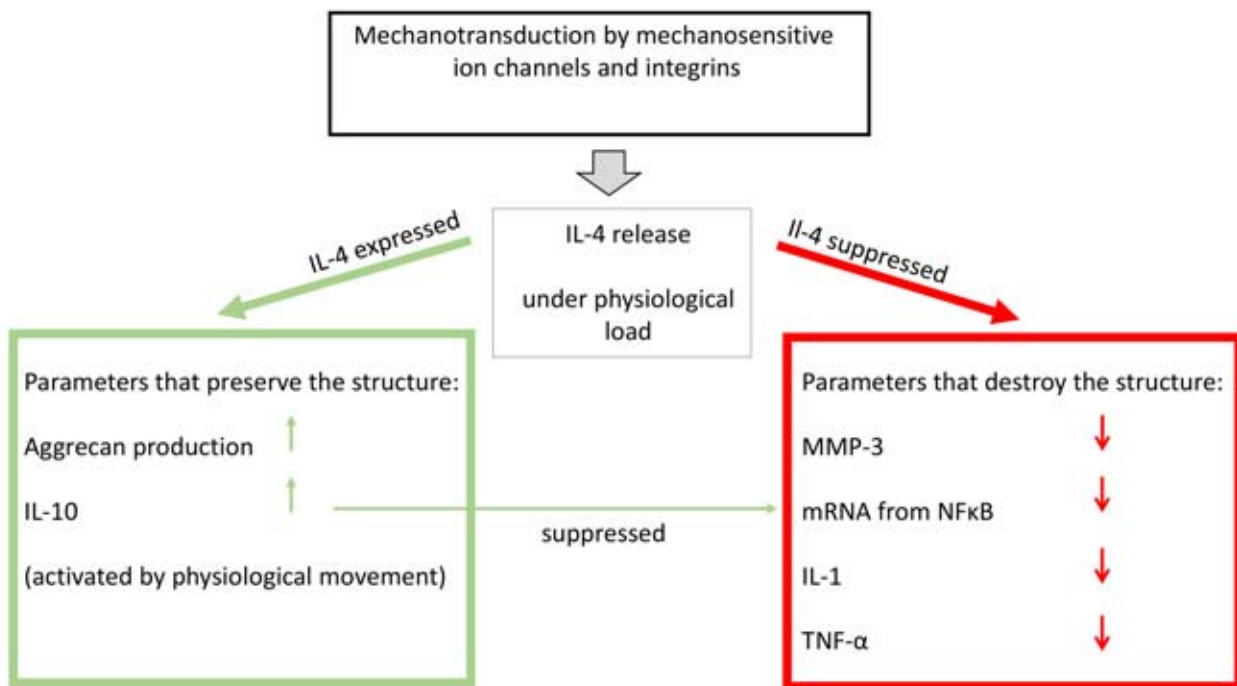
Trauma and non-physiological stress on articular cartilage surfaces are manifested, among other things, by the appearance of fragments of, for example, collagen or fibronectin. With the help of phagocytic cells, the so-called A cells of the synovial mem-

brane (s. below), the joint first attempts to eliminate these fragments. In the course of tissue damage, such fragments also bind to integrins and so-called Toll-like receptors (TLR) [23]. Integrins such as the classical fibronectin receptor α5β1 only bind to a single protein in the extracellular matrix. They cross-link proteins in the extracellular matrix on the extracellular side of the cell membrane with cytoskeletal proteins and actin filaments on the cytoplasmic side and mediate signals which are involved in regulating cell growth, cell differentiation or even apoptosis. The Toll-like Receptor (TLR) is part of the innate defense system and it recognizes structures that are found only on pathogens/foreign bodies, so-called PAMPs (Pathogen-Associated Molecular Patterns). The TLR controls the activation of the antigen-specific acquired immune system. In this way, NF-κB mediates the release of pro-inflammatory cytokines and chemokines such as IL-1, IL-6, IL-8, TNF-α, and ADAMTS (A Disintegrin and Metalloproteinase with Thrombospondin motifs) [21] (Fig. 7). This

release leads to the breakdown of the extracellular matrix in the course of the disease. Released proteoglycans such as decorin, components of collagen fibers such as fibromodulin or other components of the extracellular matrix in turn activate further integrins and TLR, which then stimulate the release of IL-1 and TNF-α and trigger nitric oxide and prostaglandin E<sub>2</sub>. Another NF-κB activation pathway which results in the release of IL-6, IL-8, TNF-α, MMP-3, and ADAMTS also occurs via receptors for glycation end-products which are termed RAGE or AGE (Receptor for Advanced Glycation End-Products, Advanced Glycation End-Products) [25, 43]. However, this pathway is mainly associated with (natural) aging processes and is therefore not likely to be considered in young patients with idiopathic condylar resorption.

### Cells of the synovial membrane

In addition to the chondrocytes of the articular cartilage and the subchondral bone cells, there are cells of the synovial membrane. In the case



**Figure 6** Processes that preserve and destroy the structure in articular cartilage under load application. IL-10 (interleukin-10), MMP-3 (matrix metalloproteinase-3), mRNA of NFκB (messenger ribonucleic acid of nuclear factor kappa B), TNF-α (tumor necrosis factor α).

of rheumatoid arthritis, it is considered with certainty that the origin of the autoimmune disease lies in the synovial membrane. The inflammatory changes then spread to the surrounding joint structures.

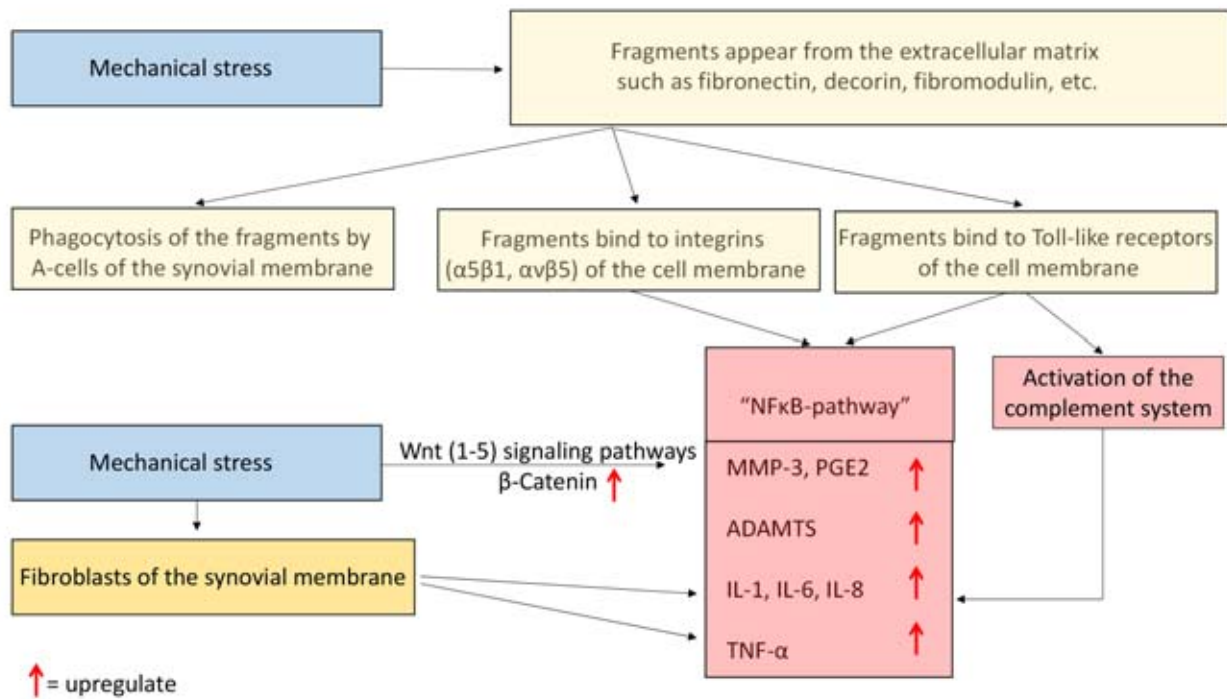
The inner joint space is bounded, on the one hand, by hyaline articular cartilage, which covers the mandibular condyle, the mandibular fossa as well as the articular tubercle and, on the other hand, by the synovial membrane of the joint capsule. The joint capsule consists of the fibrous membrane and the synovial membrane. The synovial membrane ends immediately at the cartilage edges. A synovial intimal layer, which is oriented toward the inner joint space, and a subintimal (subsynovial) layer can be distinguished [16]. The top layer consists mostly of 3 cell strata, which can form villi (Villi synoviales) and folds (Plicae synoviales). There exist 2 types of cells [18]: Type A is a round cell which is said to have phagocytic properties. This cell type is loosely embedded on the surface and it is found between larger fold and villus-forming B cells. The B cells

are partially located in several cell layers behind one another and are in contact with blood vessels. The job of the B cells is to produce and, if necessary, modify the synovial fluid in the presence of pathological influences. The B cells are assigned the role of producing hyaluronic acids, proteins, as well as collagen and fibronectin [37, 40], whereas the A cells remove cellular debris and foreign molecules from the joint space. Some authors also describe a so-called intermediate type [17]. This is based on the idea that cell types A and B can merge together. At present, it is assumed that around three quarters of synovial cells are B cells [33].

Synovial fluid is a blood-plasma dialysate. It differs from blood serum mainly through its composition of proteins and hyaluronic acids. Hyaluronic acid is a dimeric molecule of D-glucuronic acid and N-acetyl-D-glucosamine. The functions of hyaluronic acid are, on the one hand, to ensure the sliding properties of the joint surfaces and to nourish the cartilage components; on the other

hand, it is to regulate oxidative cell damage, to suppress the release of proteoglycans (inflammatory response) from cartilage as well as to participate in the chemotactic, proliferative, and phagocytic response of the joint to inflammatory changes [34]. The reported content of hyaluronic acid in synovial fluid is between 0.35 to 7.6 mg/ml [15]. On average, it is assumed to be 2–4 mg/ml [22].

In addition to hyaluronic acid, important components of the synovial fluid are the proteins albumin and γ-globulin. Both proteins are increasingly formed in the case of inflammatory joint diseases. Yet, only about 2 % of hyaluronic acid binds to proteins. Thus, its binding to proteins is not responsible for the rheological properties. Other proteins in synovial fluid are fibrinogen, immunoglobulin IgM, metalloproteinase inhibitor, α<sub>2</sub>-macroglobulin, and lubricin (glycoprotein). In addition to proteins, cytokines, collagens, enzymes, proteoglycans, fibronectin, uric acid, glucose, Na<sup>+</sup>, Cl<sup>-</sup> ions, lipids, and cellular components such



**Figure 7** Processes and stages of cartilage matrix degradation under nonphysiological load. MMP-3 (matrix metalloproteinase-3), PGE2 (prostaglandin E2), ADAMTS (A disintegrin and metalloprotease with thrombospondin-1-like domains), IL-1, IL-6, IL-8 (interleukin-1, 6, 8), TNF- $\alpha$  (tumor necrosis factor  $\alpha$ ).

as lymphocytes, monocytes, phagocytes, and leukocytes can be detected [15].

In the case of mechanical stress, Schröder et al. [39] considered the fibroblasts of the synovial membrane, which constitute the main part of the cellular structures in the synovial membrane, as the cause of inflammatory changes. Synovial fibroblasts from healthy subjects were found to express increased levels of pro-inflammatory cytokines such as TNF- $\alpha$ , prostaglandin E2, and IL-6 under mechanical load. TNF- $\alpha$  blocks proteoglycan synthesis and it is one of the most important modulators of inflammation in chondrocytes, osteoblasts, and synovial fibroblasts. Interestingly, synovial fibroblasts obtained from osteoarthritic joints did not further upregulate TNF- $\alpha$ , prostaglandin E2, and IL-6 under mechanical load. This fact can be interpreted as follows: the upregulation of the abovementioned cytokines seems to play a special role only in the initial period of osteoarthritis, and in

the course of the disease, other mediators maintain the inflammatory process [39]. In the case of inflammation, synovial cells also upregulate the release of Wnt5 and activate the so-called non-canonical Wnt signaling pathway (Fig. 3). The Wnt signaling pathway is discussed in more detail under the heading „bone“ (see below). This process ultimately activates osteoclasts and drives the destruction of the articular surfaces. The extent to which pathological processes in the synovial membrane are to be regarded as the starting point of idiopathic condylar resorption is currently unclear. The radiological findings – rarely joint effusion – tend to speak against it.

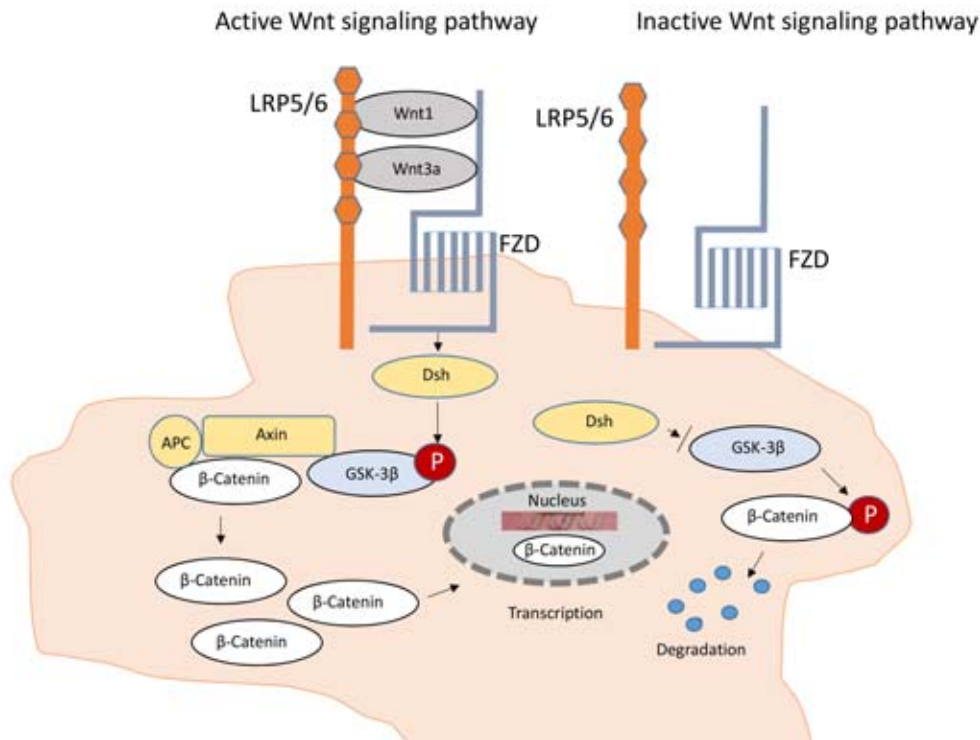
### Bone

Disturbances in bone metabolism may be considered in the development of idiopathic condylar resorption, as bone is another structure of the joint. The bone of the mandibular condyle develops from mesenchyme through desmal ossification.

Unlike other cranial bones, such as the temporal bone, there are no cartilaginous base structures in the mandibular bone. Articular cartilage also forms independently secondary to the mesenchyme (as does the articular disc) and attaches to the bony portion of the mandibular condyle [5, 28].

The so-called progenitor cells actively proliferate in bone tissue. These are spindle-shaped cells which are located in the area of the periosteum, endosteum and in the walls of the later Haversian canals. Under functional, as well as, under non-physiological stresses of the bone, the progenitor cells differentiate into osteoblasts, which are in contact with osteocytes via their cytoplasmic processes. Osteoblasts possess numerous receptors for hormones, cytokines and other signaling substances.

Osteoblasts can develop in different ways. Some of them remain on the bone surface and they slow down their synthetic cell activities to become bone lining cells. The other



**Figure 8** Active and inactive Wnt signaling pathways stimulating osteoblasts and osteocytes. Wnt1–5 (Wingless, Int-1), GSK-3 $\beta$  (Glycogen synthase-kinase 3), LRP4/5/6 (Low-density lipoprotein receptor-related protein 4/5/6), FZD (Frizzled-receptor), CAMKII (Ca<sup>2+</sup>/Calmodulin-dependent protein kinase II), DKK1 (Dickkopf Gen 1), ROR1/2 (receptor tyrosine kinase-like orphan receptor), RhoA (Ras Homologue Family Member A), Rac (Rho family of GTPases), JNK (c-Jun N-terminal kinases), PKC (Protein kinase C), Wnt/PCP (Wnt/planar cell polarity pathway), P (Phosphorylation).

part of the osteoblast population surrounds itself with osteoid. This basic organic substance of bone consists of type I collagen, proteoglycans, osteocalcin, osteonectin and osteopontin as well as various growth factors. The osteoid layer is increasingly mineralized. Ultimately, the cell cytoplasm is integrated into a bone lacuna. However, numerous projections emanate from there. These projections have contact with other osteocytes and with the bone canals. Via the projections, the „enclosed“ osteocytes always exchange signals with the osteoblasts and with the surrounding bone lining cells [24].

In recent years, the molecular processes underlying bone homeostasis and bone diseases have been further elucidated. The various forms of the Wnt/ $\beta$ -catenin signaling pathway play a special role in head morphogenesis, in the homeostasis of bone metabolism and also in the case of pathological processes or mechanical load on the bone [10, 32] (Fig. 8). According to Wu et al. [48], any

disturbance that affects the physiological function of the Wnt/ $\beta$ -catenin signaling pathway leads to dysregulations of osteoblast and chondrocyte function with changes in bone mass and degenerative joint disease.

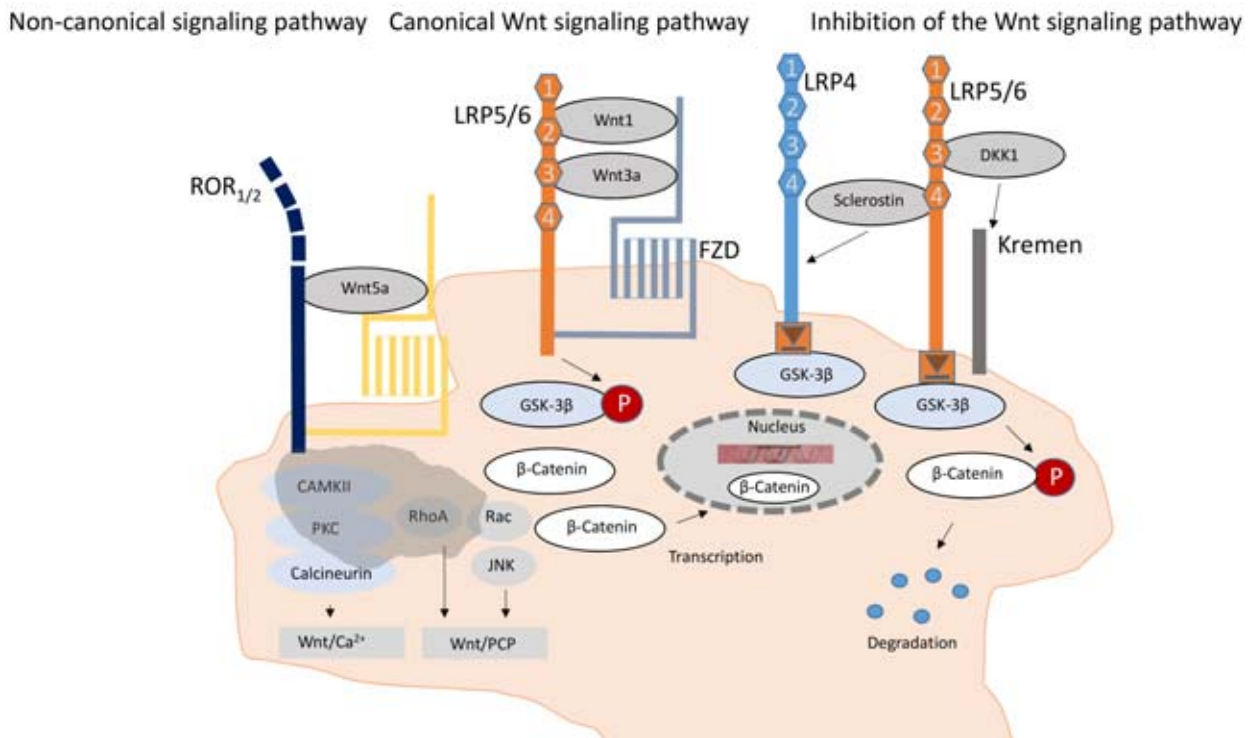
At the level of mesenchymal cells, the Wnt signaling pathway inhibits the differentiation of these cells into chondrocytes or fat cells and promotes osteogenesis. The Wnt pathway further stimulates osteogenesis by expressing the Runx2 gene and by stimulating osteoblast differentiation. It prevents apoptosis of osteoblasts and suppresses osteoclast differentiation [20].

In the Wnt signaling pathway, we distinguish a canonical Wnt signaling pathway and a non-canonical pathway (Fig. 9). The non-canonical Wnt pathway is activated via Wnt5a and induces osteoclast differentiation. In particular, synovial cells release a lot of Wnt5a during inflammatory processes. Through this process, the gene ROR2 (receptor tyrosine kinase-like orphan receptor) is

expressed, which converts osteoclast progenitor cells into active osteoclasts and activates the RANK receptors of the osteoclasts. In contrast, Wnt4 and Wnt16 block the expression of RANK.

When the canonical Wnt signaling pathway is stimulated, the concentration of  $\beta$ -catenin in the cell increases and this increases the transcription of genes in the nucleus [27]. In these cases, Wnt1 and Wnt3a first bind to the receptors „Frizzled“ and LRP5/6 (low-density lipoprotein receptor-related protein) on the outside of the cell membrane. As a result, GSK-3 $\beta$  (glycogen synthase kinase 3) is phosphorylated and inactivated inside the cell. GSK-3 $\beta$  can no longer inactivate  $\beta$ -catenin in turn, so that a high availability of  $\beta$ -catenin in the cell increases transcription (Fig. 9). According to current knowledge, the receptor LRP5 is considered to have more tasks in the maintenance of bone mass in adults, while the receptor LRP6 is considered to have tasks mainly in embryonic bone devel-





**Figure 9** Currently known Wnt signaling pathways involved in the regulation of bone metabolism. Wnt1–5 (Wingless, Int-1), GSK-3β (Glycogen synthase-kinase 3), LRP4/5/6 (Low-density-lipoprotein-receptor-related protein 4/5/6), FZD (Frizzled receptor), Dsh (Dishevelled), APC (Adenomatous-polyposis-coli-Protein).

opment, with both receptors having overlapping functions [20]. Activation of the canonical Wnt pathway stimulates osteoblast maturation and bone mass formation (Fig. 10).

The canonical Wnt signaling pathway appears to play a central role in osteoblast differentiation. Inhibitors of the Wnt signaling pathway are genes of the so-called Dickkopf family such as DKK1 in combination with the gene Kremen. DKK1 binds to the BP1 and BP3 domains of the Wnt receptor LRP6 (lipoprotein-related protein 6) (Fig. 8). LRP6 and the Wnt receptor „Frizzled“ are normally involved in signal transduction (β-catenin) in the osteocyte. The Dickkopf protein and Kremen bind to LRP6 to block signal transduction for transcription in the cell. The Dickkopf gene family is considered essential in the development of the head and limbs in mammals [32]. In the case of patients with overexpression of DKK1, lytic bone lesions occur. DKK1 reduces the formation of bone mass and prevents the formation of osteophytes. In

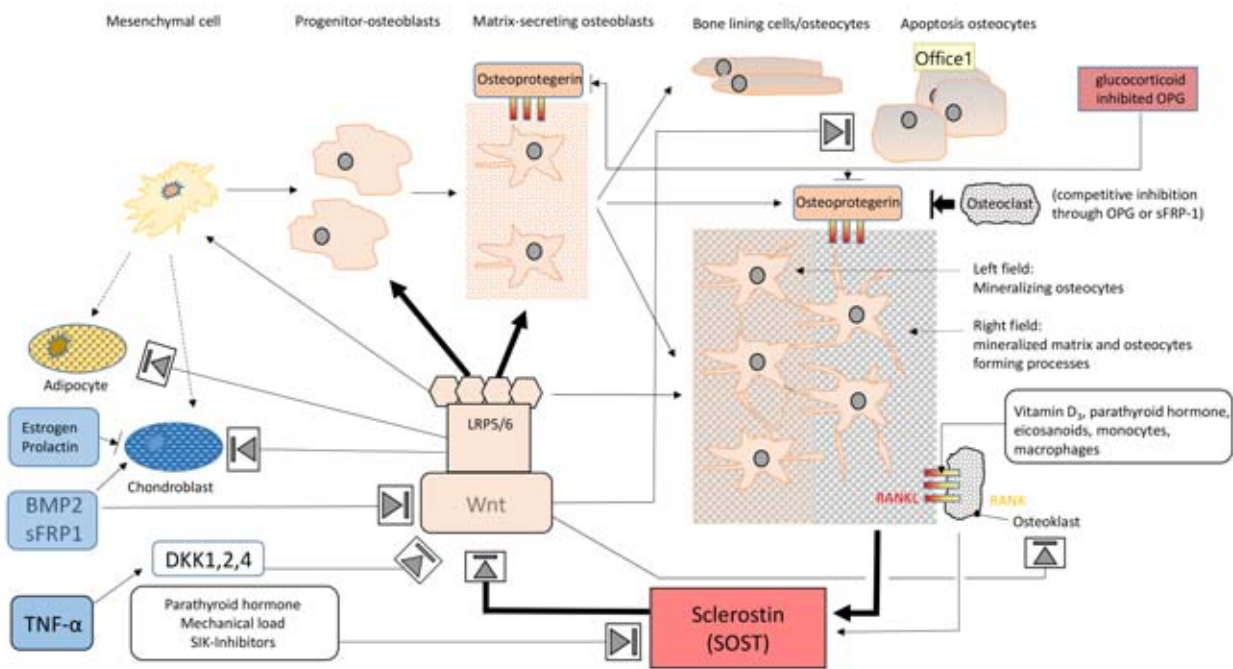
joints that are altered by inflammation, we find the expression of DKK1 especially in the synovial cells and in adjacent chondrocytes [13]. In rheumatoid arthritis, the serum concentration of 31.5 ± 2 pg/ml is twice as high as in healthy subjects, whereas the serum levels in patients with spondylitis are comparable to healthy subjects. DKK1 is regulated by TNF-α. In this way, the administration of TNF-α inhibitors lowers the serum level of DKK1 to a physiological level [13].

Unlike osteoblasts, osteoclasts are derived from the monocyte and macrophage cell lineages. The differentiation of an osteoclast precursor cell into an osteoclast is caused by the expression of RANKL and cytokines by osteoblasts and osteocytes. The binding of RANK ligand (RANKL) to the RANK receptor of osteoclast progenitor cells causes the osteoclast to mature and activate (Fig. 3). Osteoblasts and osteocytes counteract this process by secreting osteoprotegerin (OPG). The canonical Wnt signaling pathway enhances the expression of

osteoprotegerin and counteracts osteoclast differentiation (Fig. 10) [27]. This increases bone mass. Excessive bone formation inhibits the gene SOST via sclerostin („bone formation inhibitor“). The normally high level of sclerostin release by osteocytes indicates that the Wnt/β-catenin system is usually switched to „off“ (Fig. 10). The interplay of Wnt signaling and SOST regulate bone homeostasis. Mechanical load, IL-6, and parathyroid hormone suppress SOST expression in osteocytes and activate the Wnt signaling pathway. SIK (Salt-Inducible Kinase) inhibitors also hinder sclerostin release and the activation of RANKL so that osteoclast function and activation stops.

### Statement: hypothesis on the etiology of idiopathic condylar resorption

Many of the regulatory pathways and mechanisms of bone metabolism that have been described above are only partially known and understood. Regarding the origin of idiopathic condylar resorption, defini-



(Fig. 1–3, 5–10: M. Behr)

**Figure 10** Overview of regulatory mechanisms of bone metabolism under physiological and pathological conditions. Wnt1–5 (Wingless, Int-1), GSK-3 $\beta$  (Glycogen synthase-kinase 3), LRP4/5/6 (Low-density-lipoprotein-receptor-related protein 4/5/6), FDZ (Frizzled receptor), SOST (Sclerostin-gene), BMP2 (Bone morphogenetic protein 2), OPG (Osteoprotegerin), sFRP1 (Secreted Frizzled Related Protein 1), DKK1 (Dickkopf-Gen 1), RANKL (receptor activator of nuclear-factor-kappa B-ligand).

tively attributing it to a disturbance in a regulatory pathway is not possible at present. However, the following hypothesis should be formulated:

Imaging reveals that resorption mostly comprises of the anterior areas of the mandibular condyle. As already shown by Steinhardt [41], we normally find functional adaptations of bone and cartilage in the temporomandibular joint in the area of the articular tubercle as well as in the anterior area of the mandibular condyle; for example, in cases of an Angle Class II/2, bone and cartilage are reinforced. In deep bite, for example, before the mandibular body can be pushed forward, the condylar path along the tubercle is long until the dental arches are disengaged. As the disengagement of the anterior teeth progresses due to the rotational movement of the mandible, there is already a steady force vector in an anterior direction, which presses the condyle against the tubercle. In response to this functional stimulus, bone and cartilage physiologically respond through appositional growth.

Figure 10 illustrates how mechanical load normally downregulates sclerostin and activates the Wnt signaling pathway so that bone mass can be formed. The „off“ position of the Wnt pathway is lifted by mechanical load and bone growth is activated. In idiopathic condylar resorption, the balance between the anabolic function of the Wnt pathway and catabolic function of the SOST/sclerostin gene in bone might be disturbed. The localized resorptions (in contrast to multifocal responses in systemic disease) suggest the presence of localized (over)load application and a simultaneous defect in the SOST gene/Wnt pathway regulatory loop. Instead of growing additional bone under load, the regulatory mechanisms that break down bone are activated locally under load. For example, the disturbance could be due to the SOST gene or the LRP5/6 as well as the receptor „Frizzled“.

Conversely, if the SOST gene and sclerostin expression are suppressed, changes like in osteoarthritis are seen in cartilage due to activation of the

Wnt signaling pathway [12, 47]. Already Blechschmidt [8] and later Radlanski [36] pointed out that mechanical stimuli also lead to changes in the genome response (mechanical gene effects) and can obviously play a role in head morphogenesis and teratogenesis. In parallel to the disruption of the Wnt signaling pathway/SOST regulatory loop, fluctuations in estrogen and prolactin levels can contribute to damage of articulating surfaces. It is also known that especially chondrocytes can be very heterogeneous in shape, size and matrix [45], so that, in the case of idiopathic condylar resorption, less resilient chondrocyte types are perhaps present. Overall, the causes of idiopathic condylar resorption are likely to be a combination of local mechanical overload and disturbances in synovial membrane, cartilage, and/or bone metabolic regulatory loops.

### Therapy

Due to the unknown etiology, no causal therapeutic concepts are avail-

able at present. Current therapy initially aims to achieve symptomatic pain relief by supporting the bite position with bite blocks. In acute pain conditions, additional naproxen with gastric protection (e.g. Vimovo 500/20 mg, 1–0–1, cave hypertension, pregnancy) have proven effective. An important therapeutic guideline is the above described fact that, through physiological joint movements, metabolic processes, which are protective for the joint structure, can be initiated or maintained (Fig. 6) [31]. Thus, the combination of adjusted splints (facebow, centric registration is a must!) to correct the bite position with intensive physiotherapeutic exercise is an important component for re-establishing the physiological movement patterns of the temporomandibular joint in order to promote the healing process. In this context, the instruction of daily exercises which are to be performed by patients themselves is essential for success [4].

Since resorption appears to stop over time (> 5 years), further interventions which aim to correct the bite position are first indicated once there is freedom from symptoms for a period of more than 6 months and no radiological changes in resorption are detectable. Surgical, orthodontic and prosthetic measures may then have to be performed a second time [3, 49].

### Conflicts of interest

The authors declare that there is no conflict of interest as defined by the guidelines of the International Committee of Medical Journal Editors.

Michael Behr, Jochen Fanghänel,  
Peter Proff, Thomas Strasser,  
Alois Schmid, Christian Kirschneck,  
Regensburg

### References

- Aljerian A, Gilardino MS: Treacher Collins Syndrome. *Clin Plast Surg* 2019; 46: 197–205
- Arnett GW, Milam SB, Gottesman L: Progressive mandibular retrusion – idiopathic condylar resorption. Part I. *Am J Orthod Dentofacial Orthop* 1996; 110: 8–15
- Arnett GW, Milam SB, Gottesman L: Progressive mandibular retrusion-idiopathic condylar resorption. Part II. *Am J Orthod Dentofacial Orthop* 1996; 110: 117–127
- Behr K, van de Loo J, Behr M: Welche physiotherapeutischen Maßnahmen helfen bei kraniomandibulären Dysfunktionen? In: Behr M, Fanghänel J (Hrsg): *Kraniomandibuläre Dysfunktionen. Antworten auf Fragen aus der Praxis*. Thieme, Stuttgart, New York 2020, 237–261
- Behr M, Fanghänel J, Proff, P, Kirschneck C: Wie ist das kraniomandibuläre System entstanden? In: Behr M, Fanghänel (Hrsg): *Kraniomandibuläre Dysfunktionen. Antworten auf Fragen aus der Praxis*. Thieme, Stuttgart, New York 2020, 26–39
- Behr M, Fanghänel J: Wie funktioniert das Kiefergelenk des Menschen? In: Behr M, Fanghänel J (Hrsg): *Kraniomandibuläre Dysfunktionen. Antworten auf Fragen aus der Praxis*. Thieme, Stuttgart, New York 2020, 41–54
- Black R, Grodzinsky AJ: Dexamethasone. Chondroprotective corticosteroid or catabolic killer? *Eur Cell Mater* 2019; 38: 246–263
- Blehschmidt E: *Mechanische Genwirkungen – Funktionsentwicklung I*. Musterschmidt, Göttingen 1948
- Bogusiak K, Puch A, Arkuszewski P: Goldenhar syndrome. Current perspectives. *World J Pediatr* 2017; 13: 405–415
- Bonewald LF: The amazing osteocyte. *J Bone Miner Res* 2011; 26: 229–238
- Canalis E: Mechanisms of glucocorticoid-induced osteoporosis. *Curr Opin Rheumatol* 2003; 15: 454–457
- Chang JC, Christiansen BA, Murgesh DK et al.: SOST/sclerostin improves posttraumatic osteoarthritis and inhibits MMP2/3 expression after injury. *J Bone Miner Res* 2018; 33: 1105–1113
- Diarra D, Stolina M, Polzer K et al.: Dickkopf-1 is a master regulator of joint remodeling. *Nat Med* 2007; 13: 156–163
- Dimitrov B, Balikova I, Jekova N, Vakrilova L, Fryns J-P, Simeonov E: Acrofacial dysostosis type Rodríguez. *Am J Med Genet A* 2005; 135: 81–85
- Fam H, Kontopoulou M, Bryant JT: Effect of concentration and molecular weight on the rheology of hyaluronic acid/bovine calf serum solutions. *Biorheology* 2009; 46: 31–43
- Fanghänel J, Pera F, Anderhuber F, Nitsch R (Hrsg): *Waldeyer – Anatomie des Menschen. Lehrbuch und Atlas in einem Band*. De Gruyter, Berlin, New York 2009
- Fell HB, Glauert AM, Barratt ME, Green R: The pig synovium. I. The intact synovium in vivo and in organ culture. *J Anat* 1976; 122: 663–680
- Iwanaga T, Shikichi M, Kitamura H, Yanase H, Nozawa-Inoue K: Morphology and functional roles of synoviocytes in the joint. *Arch Histol Cytol* 2000; 63: 17–31
- Jaffré B, Watrin A, Loeuille D et al.: Effects of anti-inflammatory drugs on arthritic cartilage. A high-frequency quantitative ultrasound study in rats. *Arthritis Rheum* 2003; 48: 1594–1601
- Johnson ML: Wnt signaling and bone. In: Bilzikian JP, Raisz LG, Martin TJ (Hrsg): *Principles of bone biology*. Elsevier, Amsterdam, Boston 2008, 121–137
- Kelwick R, Desanlis I, Wheeler GN, Edwards DR: The ADAMTS (A disintegrin and metalloproteinase with thrombospondin motifs) family. *Genome Biol* 2015; 16: 113
- Krause WE, Bellomo EG, Colby RH: Rheology of sodium hyaluronate under physiological conditions. *Biomacromolecules* 2001; 2: 65–69
- Lim K-H, Staudt LM: Toll-like receptor signaling. *Cold Spring Harb Perspect Biol* 2013; 5: a011247
- Linß W, Fanghänel J: *Histologie. Zytologie, Allgemeine Histologie, Mikroskopische Anatomie*. De Gruyter, Berlin, New York 1999
- Loeser RF, Yammani RR, Carlson CS et al.: Articular chondrocytes express the receptor for advanced glycation end-products. Potential role in osteoarthritis. *Arthritis Rheum* 2005; 52: 2376–2385
- Löffler G: *Basiswissen Biochemie mit Pathobiochemie*. Springer, Heidelberg 2008
- Maeda K, Kobayashi Y, Koide M et al.: The regulation of bone metabolism and disorders by Wnt signaling. *Int J Mol Sci* 2019; Nov 6;20(22):5525. doi: 10.3390/ijms20225525.
- Mérida-Velasco JR, Rodríguez-Vázquez JF, Mérida-Velasco JA, Sánchez-Montesinos I, Espín-Ferra J, Jiménez-Collado J: Development of the human temporomandibular joint. *Anat Rec* 1999; 255: 20–33
- Milam SB, Aufdemorte TB, Sheridan PJ, Triplett RC, van Sickels JE, Holt GR: Sexual dimorphism in the distribution of estrogen receptors in the temporomandibular joint complex of the baboon. *Oral Surg Oral Med Oral Pathol* 1987; 64: 527–532
- Mitsimponas K, Mehmet S, Kennedy R, Shakib K: Idiopathic condylar resorp-

- tion. *Br J Oral Maxillofac Surg* 2018; 56: 249–255
31. Musumeci G: The effect of mechanical loading on articular cartilage. *J Funct Morphol Kinesiol* 2016; 1: 154–161
32. Niehrs C: Molekulare Pfadfinder: Wie Proteine Köpfe formen. <https://www.uni-heidelberg.de/presse/ruca/ruca03-2/molek.html> (last access on: 16.06.2020)
33. Okada Y, Nakanishi I, Kajikawa K: Secretory granules of B-cells in the synovial membrane. An ultrastructural and cytochemical study. *Cell Tissue Res* 1981; 216: 131–141
34. Praest BM, Greiling H, Kock R: Assay of synovial fluid parameters. Hyaluronan concentration as a potential marker for joint diseases. *Clin Chim Acta* 1997; 266: 117–128
35. Prakken B, Albani S, Martini A: Juvenile idiopathic arthritis. *Lancet* 2011; 377: 2138–2149
36. Radlanski RJ: Mechanische Genwirkungen? Eine Frage der Teratologie. In: Fanghänel J, Behr M, Proff P (Hrsg): *Teratologie heute*. Eigenverlag, Regensburg, Greifswald 2012, 83–90
37. Roy S, Ghadially FN: Ultrastructure of normal rat synovial membrane. *Ann Rheum Dis* 1967; 26: 26–38
38. Sansare K, Raghav M, Mallya SM, Karjodkar F: Management-related outcomes and radiographic findings of idiopathic condylar resorption. A systematic review. *Int J Oral Maxillofac Surg* 2015; 44: 209–216
39. Schröder A, Nazet U, Muschter D, Grässel S, Proff P, Kirschneck C: Impact of mechanical load on the expression profile of synovial fibroblasts from patients with and without osteoarthritis. *Int J Mol Sci* 2019; Jan 30;20(3):585. doi: 10.3390/ijms20030585
40. Schumacher HR: Ultrastructure of the synovial membrane. *Ann Clin Lab Sci* 1975; 5: 489–498
41. Steinhardt G: Zur Pathologie und Therapie des Kiefergelenkknackens. *Dtsch Zschr Chir* 1933; 241: 531–552
42. Stoll ML, Lio P, Sundel RP, Nigrovic PA: Comparison of Vancouver and International League of Associations for rheumatology classification criteria for juvenile psoriatic arthritis. *Arthritis Rheum* 2008; 59: 51–58
43. Teissier T, Boulanger É: The receptor for advanced glycation end-products (RAGE) is an important pattern recognition receptor (PRR) for inflamming. *Biogerontology* 2019; 20: 279–301
44. Tsai CL, Liu TK, Chen TJ: Estrogen and osteoarthritis. A study of synovial estradiol and estradiol receptor binding in human osteoarthritic knees. *Biochem Biophys Res Commun* 1992; 183: 1287–1291
45. Wilkens RJ, Browning JA, Urban JPG: Chondrocyte regulation by mechanical load. In: Stoltz JF (Hrsg): *Mechanobiology: cartilage and chondrocyte*. IOS Press, Amsterdam, Berlin 2000, 67–74
46. Wolford LM, Galiano A: Adolescent Internal Condylar Resorption (AICR) of the temporomandibular joint, part 1. A review for diagnosis and treatment considerations. *Cranio* 2019; 37: 35–44
47. Wu Q, Huang JH, Sampson ER et al.: Smurf2 induces degradation of GSK-3beta and upregulates beta-catenin in chondrocytes. A potential mechanism for Smurf2-induced degeneration of articular cartilage. *Exp Cell Res* 2009; 315: 2386–2398
48. Wu Q, Zhu M, Rosier RN, Zuscik MJ, O’Keefe RJ, Di Chen: Beta-catenin, cartilage, and osteoarthritis. *Ann N Y Acad Sci* 2010; 1192: 344–350
49. Young A: Idiopathic condylar resorption. The current understanding in diagnosis and treatment. *J Indian Prosthodont Soc* 2017; 17: 128–135



(Photo: UKR)

**PROF. DR. MED. DENT.  
MICHAEL BEHR**  
University of Regensburg  
Faculty of Medicine  
Franz-Josef-Strauss-Allee 11  
93053 Regensburg

[michael.behr@klinik.uni-regensburg.de](mailto:michael.behr@klinik.uni-regensburg.de)