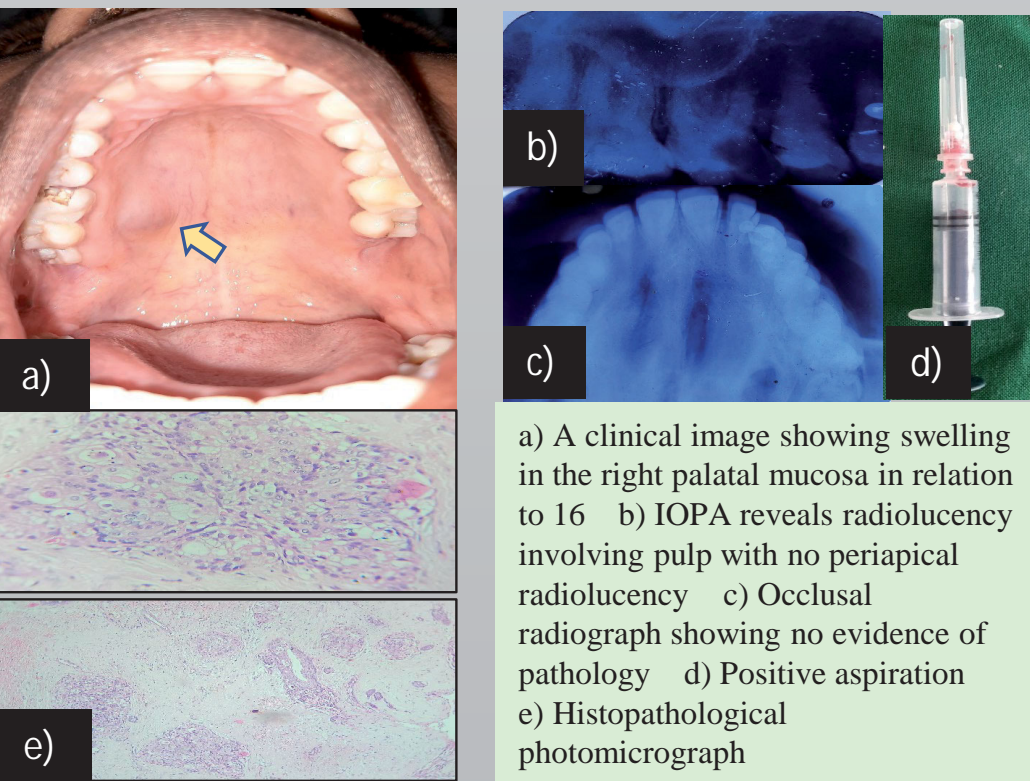


INTRODUCTION: Palatal swellings may result from a variety of etiological factors and can originate from the structures within the palate or beyond it. A mass or swelling of the palate can result from developmental, inflammatory, reactive, or neoplastic processes.

CLINICO RADIOLOGICAL APPROACH: For differential diagnosis, swellings must be considered based on their location (interior surface or posterior surface of hard palate or soft palate), by its origin (congenital or acquired), by its consistency (soft, firm or hard), and by its border (diffuse or localized)[1]. Radiographs can aid in ruling out pathologies such as abscesses and periapical inflammatory conditions. Routine panoramic radiography can help discover bony masses arising from the maxilla and salivary gland pathology. CBCT is particularly good at the detection of malignancies, especially those cases with extensive bony involvement, and can provide foresight into the treatment planning and be a valuable tool in assessing the clinical picture[2].

CASE 1

A 38-yr-old female patient presented with swelling in the upper jaw region for the past 6 months. Patient had no history of associated trauma.



a) A clinical image showing swelling in the right palatal mucosa in relation to 16 b) IOPA reveals radiolucency involving pulp with no periapical radiolucency c) Occlusal radiograph showing no evidence of pathology d) Positive aspiration e) Histopathological photomicrograph

PROVISIONAL DIAGNOSIS : Palatal abscess

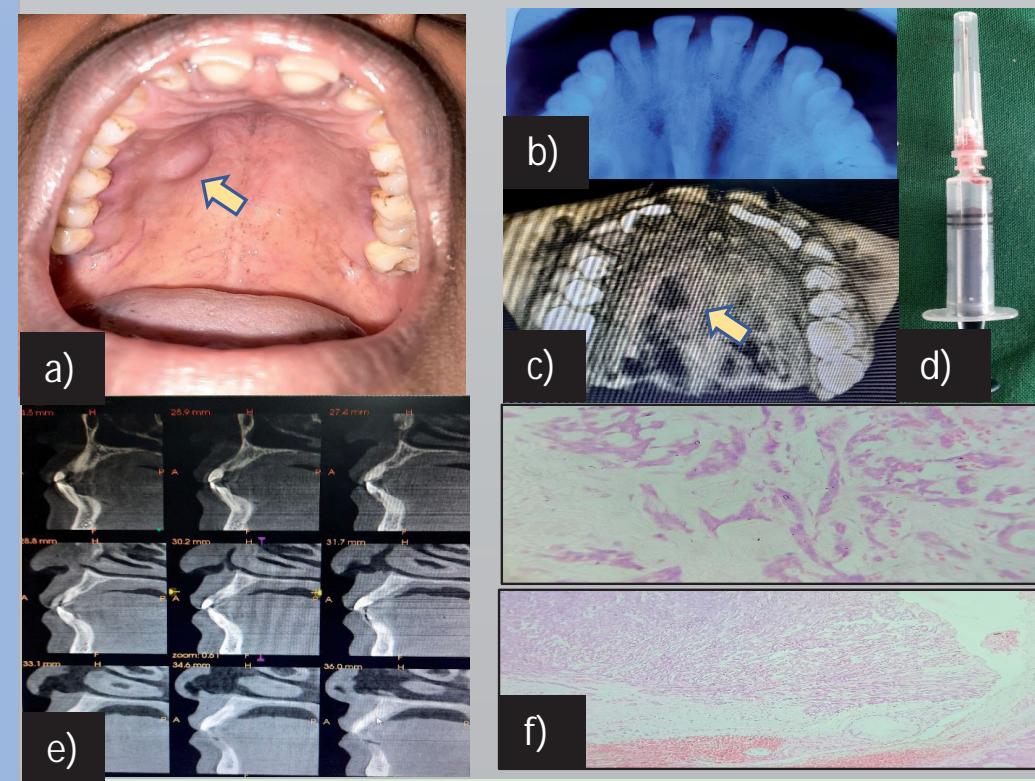
DIFFERENTIAL DIAGNOSIS : Benign minor salivary gland tumor, Malignant salivary gland tumor

FINAL DIAGNOSIS: Low grade mucoepidermoid carcinoma

TREATMENT PLAN: Excisional biopsy and follow-up

CASE 2

A 43-yr-old female patient presented with an incidental finding of swelling in the upper jaw region for the past year.



a) Clinical image b) 3D reconstruction reveals mild perforation of bone in right side of palate c) Occlusal radiograph reveals no specific changes d) Negative aspiration e) Sagittal section reveals thinning of palatal bone f) Histopathological photomicrograph

PROVISIONAL DIAGNOSIS: Benign minor salivary gland tumor

DIFFERENTIAL DIAGNOSIS: Malignant salivary gland tumor

FINAL DIAGNOSIS : Polymorphous adenocarcinoma

TREATMENT PLAN : Excisional biopsy

DISCUSSION

- Minor salivary gland tumor accounts for about 15% of all the salivary gland neoplasms, of which mucoepidermoid carcinoma accounts for about 35.9%.
- MEC occurs most frequently between the third and sixth decades of life and affects women more often than men, with a ratio of 3:2. It is frequently seen in the parotid gland, followed by minor salivary glands

CONCLUSION

Palatal swellings can at times be a challenging task for a clinician to diagnose. Thus, a palatal swelling may clinically resemble a dental cyst, an abscess, or any benign neoplasm, which leads to a delay in the diagnosis and treatment. Hence, prompt clinical and histopathological diagnosis of such lesions is of utmost importance for successful management.

REFERENCES

- 1) Ravikumar SS, Saranya V, Chandramohan K. Palatal swelling in a young adult. Journal of Oral and Maxillofacial Pathology: JOMFP. 2019 Feb;23(Suppl 1):27.
- 2) Jayachandran S, Riyaz MA. Assessment of salivary gland enlargements with the aid of ultrasound-guided FNAC, CT, and MRI: A hospital based diagnostic study. Journal of Indian Academy of Oral Medicine and Radiology. 2009 Oct 1;21(4):152.