

# CUSTOMISED AESTHETIC LINGUAL ARCH IN AN ADOLESCENT PATIENT -

## A NOVEL APPROACH

Dr SnigdhaGupta<sup>1</sup>

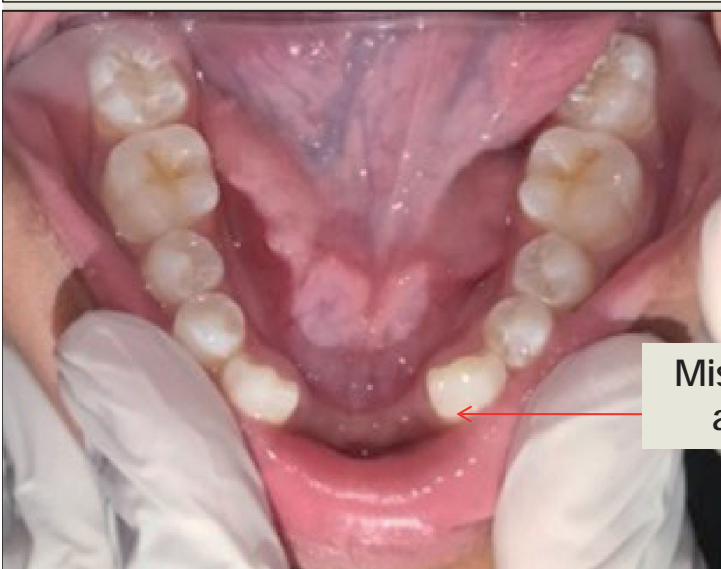<sup>1</sup>P.G. Resident, Department of Pediatric and Preventive Dentistry, Faculty of Dental Sciences, SGT University

### INTRODUCTION

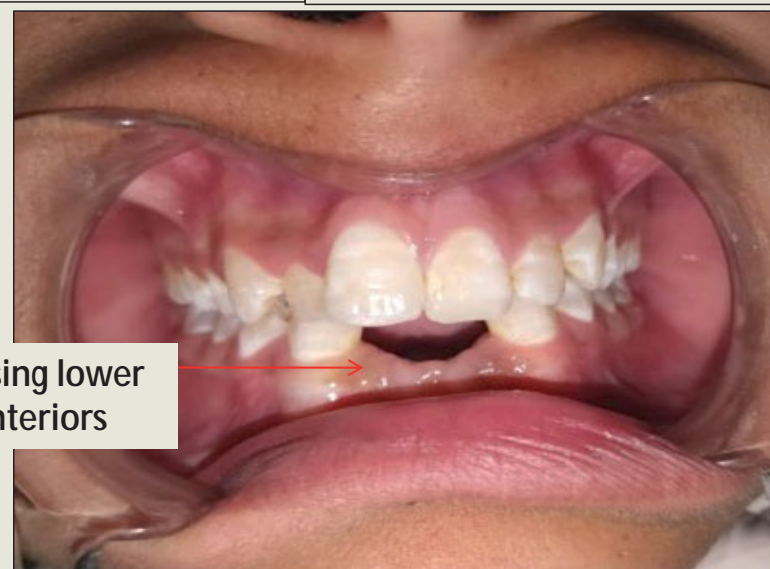Aesthetics is the major concern in cases of space management in preteens, specially when young permanent anterior teeth are lost due to trauma. We present a rare case report of missing permanent mandibular anterior teeth and rehabilitation using an innovative customised fixed appliance with the aim of aesthetic & space management till definitive treatment such as implants is carried out after growth completion.

### CASE DESCRIPTION

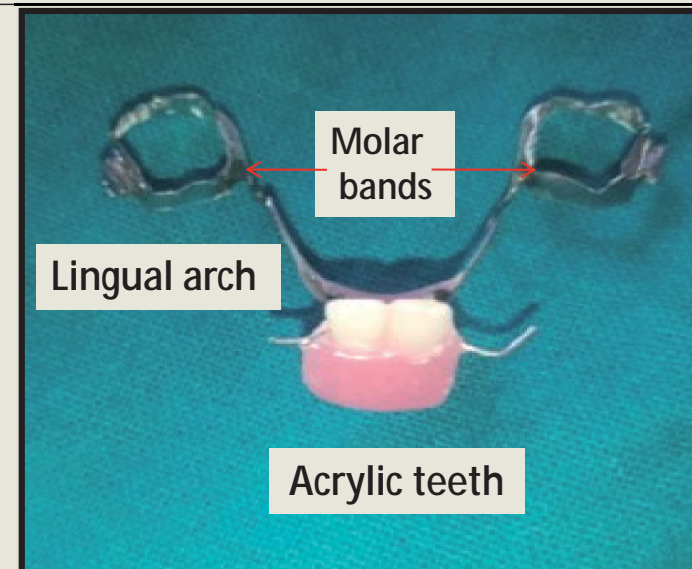
A 12-year-old boy presented with missing lower incisors with a history of extraction post trauma 3 years back. A novel appliance was designed and customised for the patient considering his demand of fixed aesthetic rehabilitation. Banding followed by construction of the lingual arch with only acrylic teeth attachment and stopper for adjacent canines was constructed; the shade and size selection of the teeth was done to meet aesthetic and functional demands.



Missing lower anteriors



PREOPERATIVE

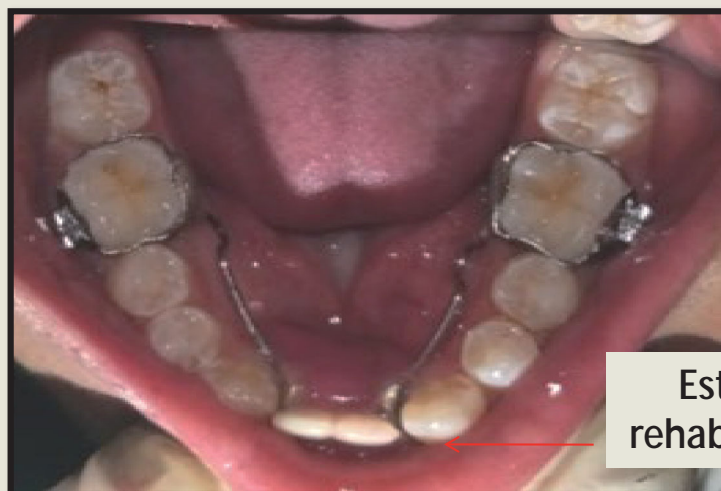

Lingual arch

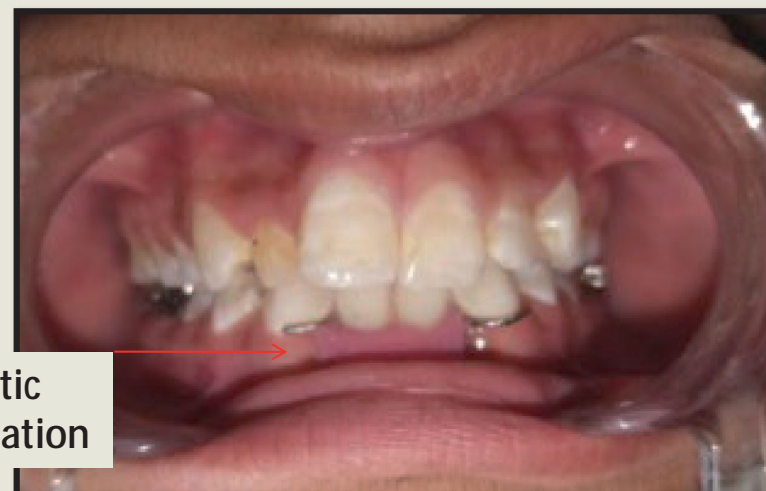Molar bands

Acrylic teeth

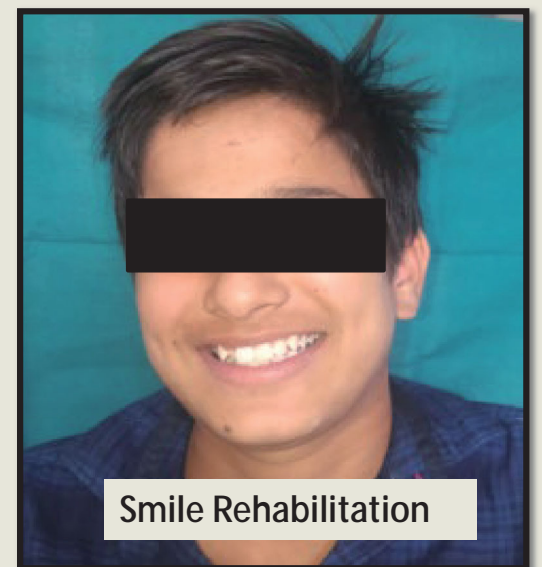
APPLIANCE DESIGN



Esthetic rehabilitation



POSTOPERATIVE



Smile Rehabilitation

### DISCUSSION

Young permanent tooth loss requires a combination of treatments addressing both aesthetics and function. A paediatric dentist should try to meet these demands while simultaneously considering the patient's socioeconomic status. Replacement of lost anterior teeth prevents psychological and social trauma to the growing patient.

### CONCLUSION

In the present case, a fixed innovative appliance customised for aesthetic purposes was constructed. This appliance can be an alternate interim treatment to a removable appliance, with higher acceptance and reliability and is easy and quick to fabricate.

### REFERENCES

- Chalakkal P, Ferreira AN, Da Costa GC, Aras MA. Functional Lingual Arch with Hinge-type Lockable Dentulous Component. International journal of clinical pediatric dentistry. 2017 Jul;10(3):302.
- Harrison SD, Park JH. A Modified Pontic Appliance for Missing Maxillary Incisors. Journal of Clinical Pediatric Dentistry. 2020;44(2):123-
- Kirtaniya BC, Kaur J, Lyall BS, Pathania V. Modified Nance Palatal Arch: An Aesthetic Approach To Missing Anterior Teeth-A Case Report. Indian Journal of Dental Sciences. 2015 Jun 1;7(2).6.

### ACKNOWLEDGEMENT

I deny any conflicts of interest related to this case. I would like to thank Dr Shalini Garg and Dr Anil Gupta for their contribution and endless support and guidance.