

Gabriel Schmidt Dolci, Donald Ferguson, Nikhilesh R Vaid, James Mah, Stefan Cardon

Hybrid mechanics for early interceptive treatment of anterior crossbite



Gabriel Schmidt Dolci

KEY WORDS anterior crossbite, Class III treatment, clear aligners, extraoral traction appliance, growing patient, in-office aligners, interceptive orthodontics, maxillary arch expansion, removable orthodontic appliances

Early interception of anterior crossbite has functional, structural and aesthetic benefits that have been widely enumerated in the literature. The goal of early interception usually involves proclination of the maxillary incisors, thus eliminating mandibular anterior shift; maxillary disjunction and protraction to correct transverse and sagittal deficiencies, respectively; and maintenance or improvement of mandibular compensation, thus creating as much horizontal overlap as possible. The present study illustrates a case treated for 24 months with a modified Catalan appliance incorporated into in-office aligners. The treatment results highlighted the

efficacy of hybrid mechanics for mandibular compensation and protraction of the maxillary dentition. The 5-year follow-up demonstrated relative stability of the final outcome.

Introduction

Skeletal Class III malocclusion represents a major clinical concern even among experienced orthodontists, and the benefits of its early treatment have long been debated¹⁻⁵. The literature indicates that cases of anterior crossbite (ACB) associated with true or pseudo-Class III malocclusion should be treated as soon as the malocclusion is diagnosed⁴⁻⁶.

Moreover, ACB can represent the phenotype of a complex skeletal Class III malocclusion, or can simply be associated with forward mandibular displacement to achieve maximum intercuspation, known as functional ACB or pseudo-Class III. The differential diagnosis between skeletal and pseudo-Class III is crucial and can be established following a detailed anamnesis and clinical and cephalometric examination⁷. Careful application of the Lin 3-Ring method can indicate the prognosis for the correction of ACB through nonsurgical treatment⁸.

The present case report illustrates a peculiar clinical condition in which a functional forward mandibular shift occurred in association with a Class III pattern, leading to ACB. Hybrid mechanics involving in-office aligners and fixed

Gabriel Schmidt Dolci, DDS, DMSc, PhD
Associate Professor, Department of Orthodontics, European University College, Umm Hurair 2Dubai Healthcare City, Dubai, United Arab Emirates

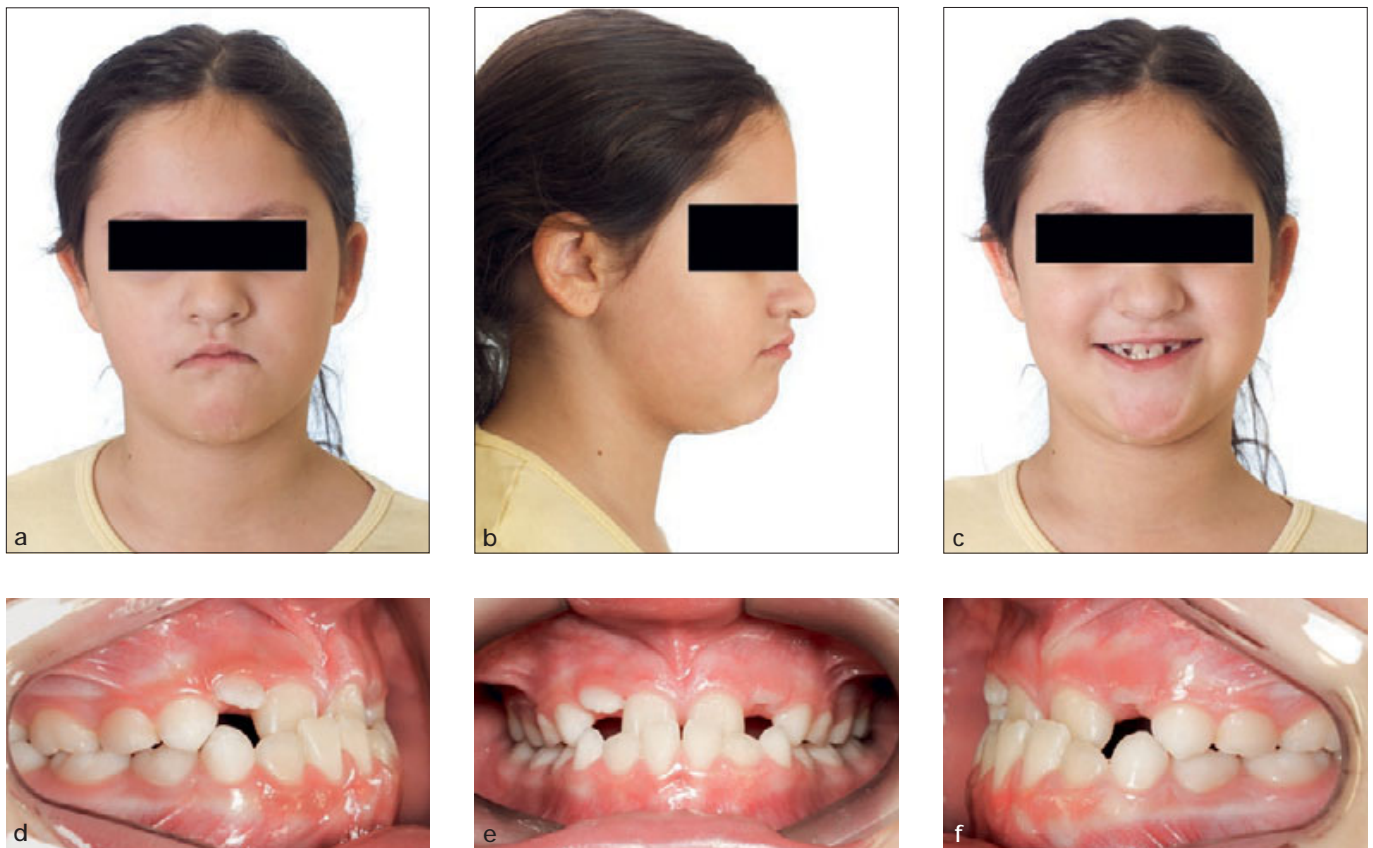Donald Ferguson, DDS, DMSc, PhD
Professor and Dean, Department of Orthodontics, European University College, Umm Hurair 2Dubai Healthcare City, Dubai, United Arab Emirates

Nikhilesh R Vaid, DMSc, PhD
Professor and Assistant Dean (Academics), Department of Orthodontics, European University College, Umm Hurair 2Dubai Healthcare City, Dubai, United Arab Emirates

James Mah, DDS, MSc, DMSc
Professor and Orthodontic Programme Director, University of Nevada, Las Vegas, NV, USA

Stefan Cardon, DDS, DMSc
Professor, Department of Orthodontics, Faculty of Dental Medicine, IMED-Porto Alegre, Porto Alegre, Brazil

Correspondence to: Dr Gabriel Schmidt Dolci, Department of Orthodontics, European University College, 4 26th Street, Umm Hurair 2Dubai Healthcare City, Dubai, United Arab Emirates.
Email: gabriel.dolci@euc.ac.ae



Figs 1a-f Pretreatment facial and intraoral photographs taken with the mandible in maximal intercuspation.

appliances were devised to intercept the malocclusion at an early stage, thus re-establishing the normal development of the dentition.

Case presentation

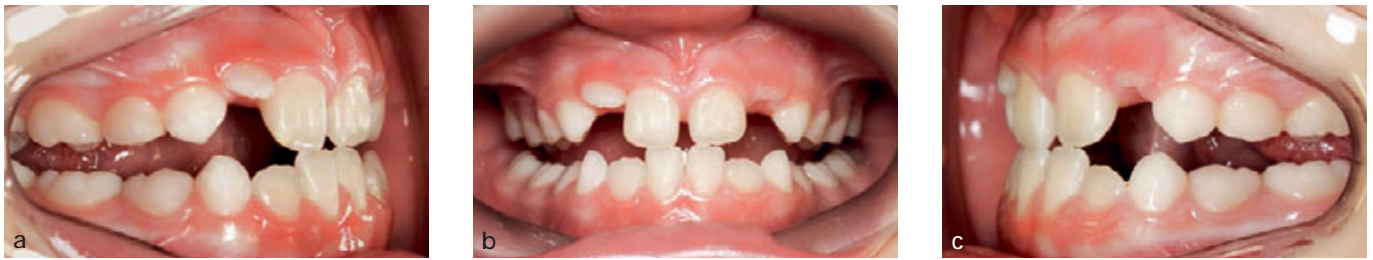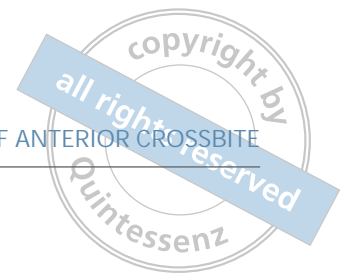
Diagnosis and treatment plan

An 8-year-old girl attended an orthodontic consultation at a private practice (SC) with the chief complaint of ACB associated with functional issues during mastication. She was in the first stage of mixed dentition, and the anamnesis indicated a family history of skeletal Class III malocclusion, nocturnal snoring and predominant mouth breathing.

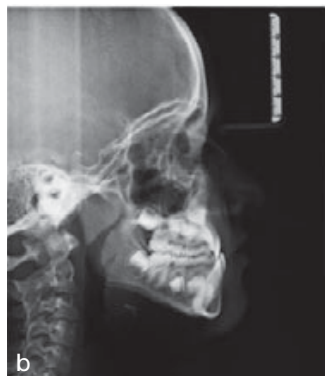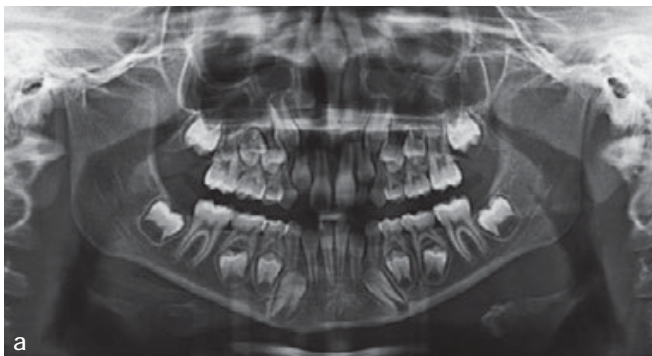
The clinical examination revealed a long lower facial height, midface deficiency, straight facial profile, reduced nasolabial angle, retrusive upper lip and large buccal corridor (Fig 1). In maximum intercuspation, the patient presented with the distal surfaces of the second molars in a

mesial step, ACB with a negative horizontal overlap of 2.0 mm, a 4.0-mm vertical overlap, and the upper and lower midlines coinciding with the facial midline; however, when the mandible was guided into centric relation, a premature occlusal contact was observed between the maxillary and mandibular central incisors (Fig 2). Consequently, it was supposed that ACB was mainly related to forward mandibular displacement during closure to maximum intercuspation. As such, further radiographic examinations were performed to define the differential diagnosis between skeletal and pseudo-Class III. Oral hygiene and periodontal status were verified. The clinical examination also indicated that the patient exhibited mixed breathing, and an otolaryngologist had already been consulted.

A panoramic radiograph showed the presence of all the permanent teeth except the third molars. The eruption sequence also appeared to be adequate (Fig 3). Cephalometric analysis^{9,10} revealed a Class III skeletal pattern with a sagittal maxillary deficiency and clockwise rotation of the



Figs 2a-c The mandible was manipulated into centric relation; note the premature contact between the maxillary and mandibular central incisors.



Figs 3a-b Pretreatment panoramic and lateral cephalometric radiographs taken with the mandible in edge-to-edge relation and maximal intercuspation, respectively, suggesting normal development of the dentition and retroclination of the maxillary and mandibular incisors.

mandible, determining a slight vertical growth pattern. The maxillary and mandibular incisors were retroclined, and significant nasopharyngeal obstruction was observed (Fig 3 and Table 1).

The treatment objectives were as follows:

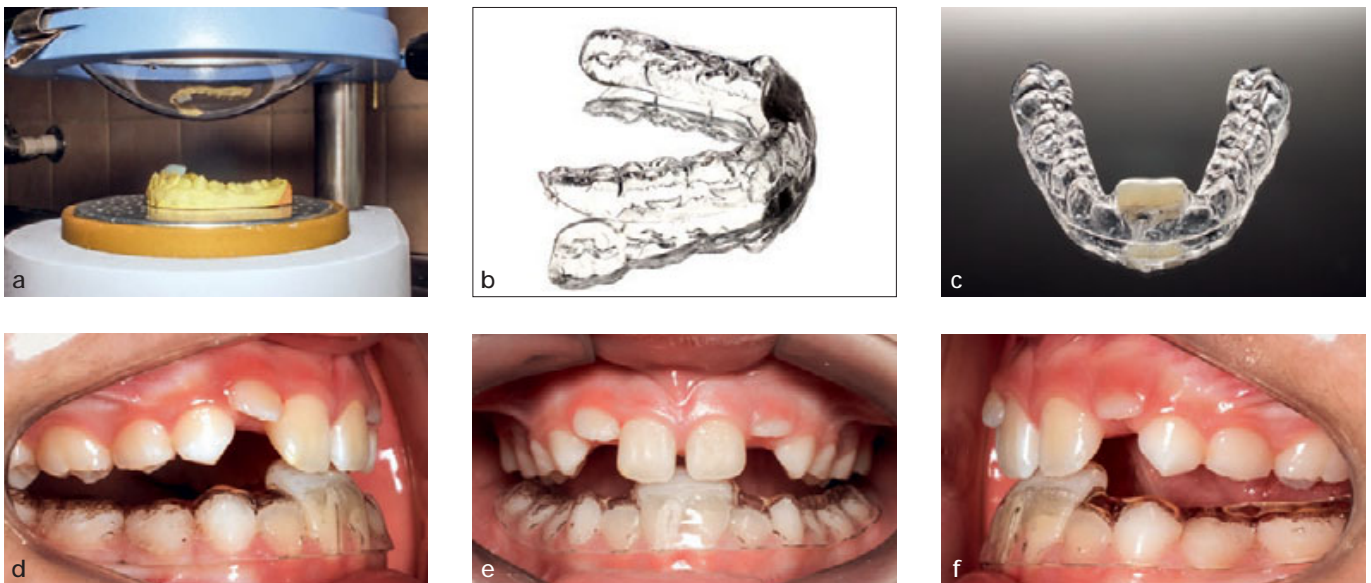
- to procline the maxillary incisors, thus eliminating mandibular anterior shift;
- to perform maxillary disjunction and protraction with the intention of correcting transverse and sagittal deficiencies, respectively;
- to maintain or even improve mandibular compensation, thus creating as much horizontal overlap as possible;
- to improve the nasal airway capacity;
- to allow normal development of the dentition.

Table 1 Cephalometric analysis. Initial data indicated a discrepancy between maxillary and mandibular lengths (Co-A and Co-Gn)

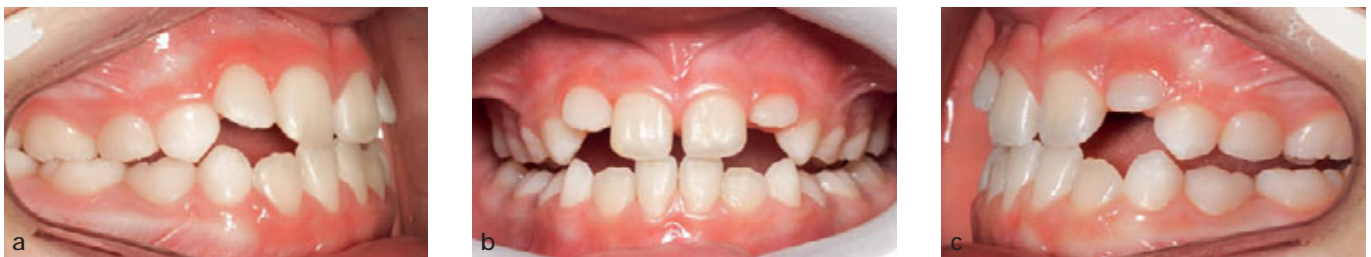Variable	Ideal	Pre-treatment	Post-treatment
SNA, degrees	82	78.3	80.0
SNB, degrees	80	77.3	77.0
ANB, degrees	2	1.0	3.0
SN-GoGn, degrees	32	39.5	43.3
Y-axis, degrees	59	61.2	63.1
NAPog, degrees	0	-4.4	5.2
1-NA, mm	5	1.8	3.0
1.NA, degrees	22	13.7	16.9
1-NB, mm	5	2.1	3.0
1.NB, degrees	25	16.8	19.3
A-NPerp, mm	0-1	1.0	2.9
Pog-NPerp, mm	6-8	9.4	2.3
Co-A, mm	75	75.2	88.0
Co-Gn, mm	92	101.1	118.2
ANS-Me, mm	54	53.5	68.0
Upper pharynx, mm	17.4	3.3	8.8
Lower pharynx, mm	10-12	11.5	12.3
FMA, degrees	25	23.6	28.0
IMPA, degrees	90	80.0	83.1

Treatment progress

First, an aesthetic removable inclined plane (modified Catalan appliance) was used to promote premature contact in the palatally displaced maxillary incisors^{11,12}, thus moving



Figs 4a-f (a to c) A polyethylene terephthalate glycol (PET-G) foil (1 mm) was thermoformed to construct an aesthetic removable bite plane. (d to f) Intraoral aspects at placement of the appliance.

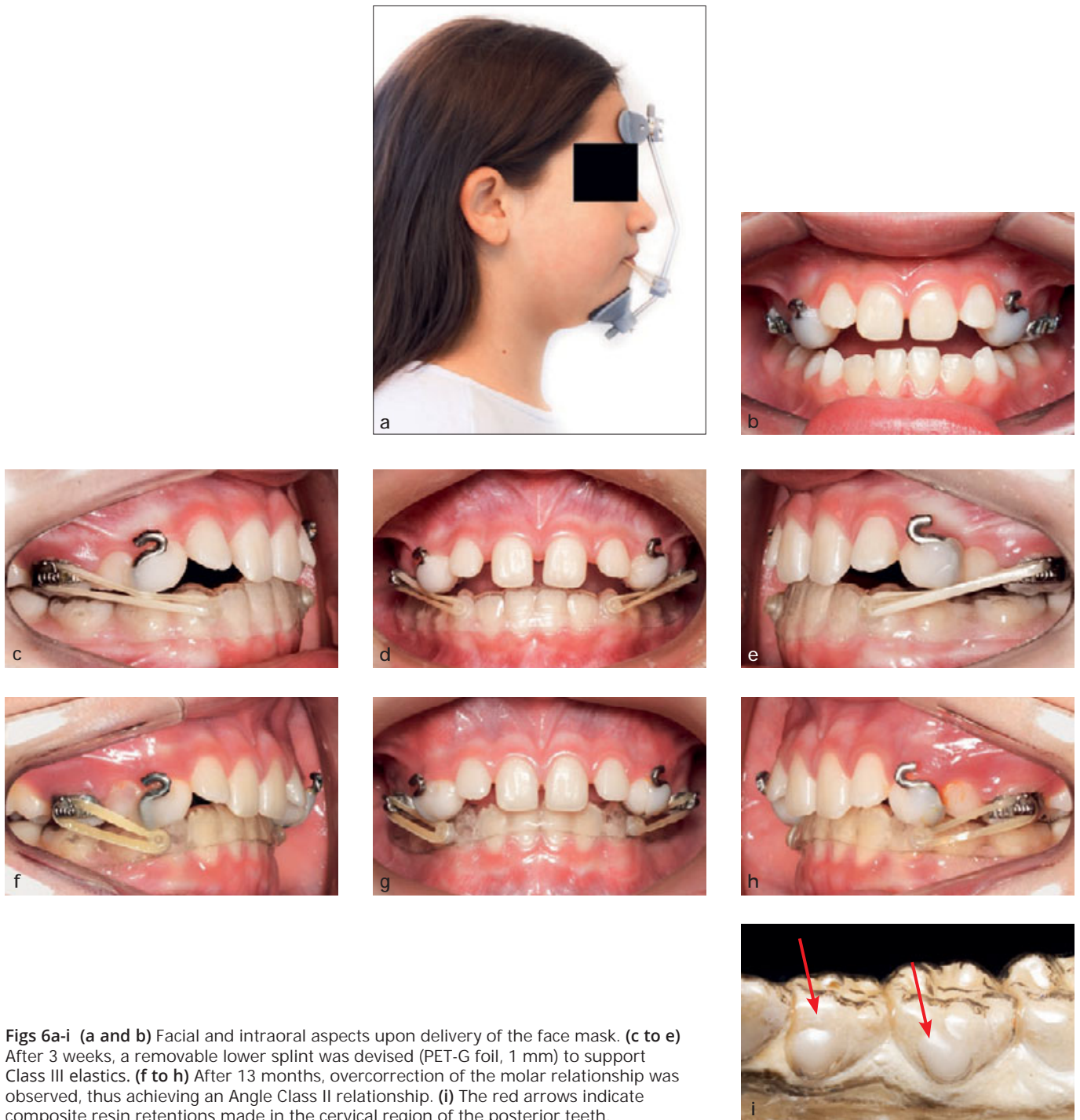
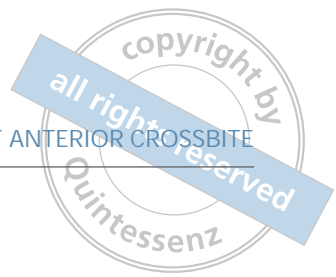

Figs 5a-c Facial and intraoral photographs taken with the mandible in centric occlusion 1 month after placement of the aesthetic removable bite plane.

these teeth buccally and correcting the functional ACB (Fig 4). The patient was instructed to wear the appliance on a full-time basis, removing it only during meals and oral hygiene procedures. After 1 month, the ACB was corrected (Fig 5), then the second phase of interceptive treatment began.

Aiming to increase the maxillary dimensions (transverse and sagittal), a modified Hygienic Rapid Palatal Expander¹³ was used to widen the maxilla (Fig 6) and the screw was activated twice a day, with one quarter turn made every 12 hours for 14 days¹⁴. Maxillary protraction was then carried out using a Petit face mask (Morelli, São Paulo, Brazil)¹⁵. The patient was instructed to wear the appliance for 14 hours each day (day and night) and the magnitude of the force was increased gradually, reaching 400 gf on each side after 1 month of appliance wear.

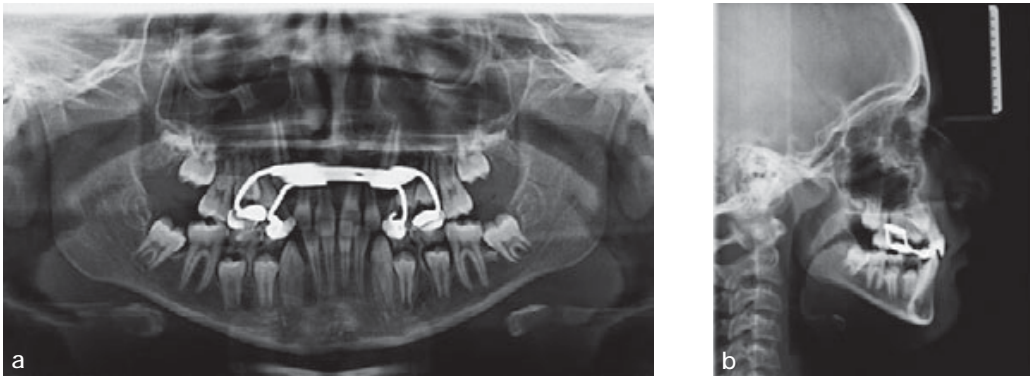To improve the horizontal overlap, mass retraction of the mandible was planned concomitant to maxillary protraction. A removable aesthetic appliance with ceramic buttons bonded in the canine region was devised to support the mechanics of Class III elastics. To avoid appliance instability when the patient was wearing elastics, physical retentions were made from composite resin and placed in the cervical region of the posterior teeth (Fig 6). The use of an aesthetic aligner in the mandible had a positive impact on patient compliance, because such appliances have better psychological effects when compared to buccal/lingual braces¹⁶. The patient was instructed to wear the appliance with bilateral Class III elastics (3/16-inch) daily and nightly during this phase, which lasted 13 months and resulted in the achievement of a Class II molar relationship (Fig 6).



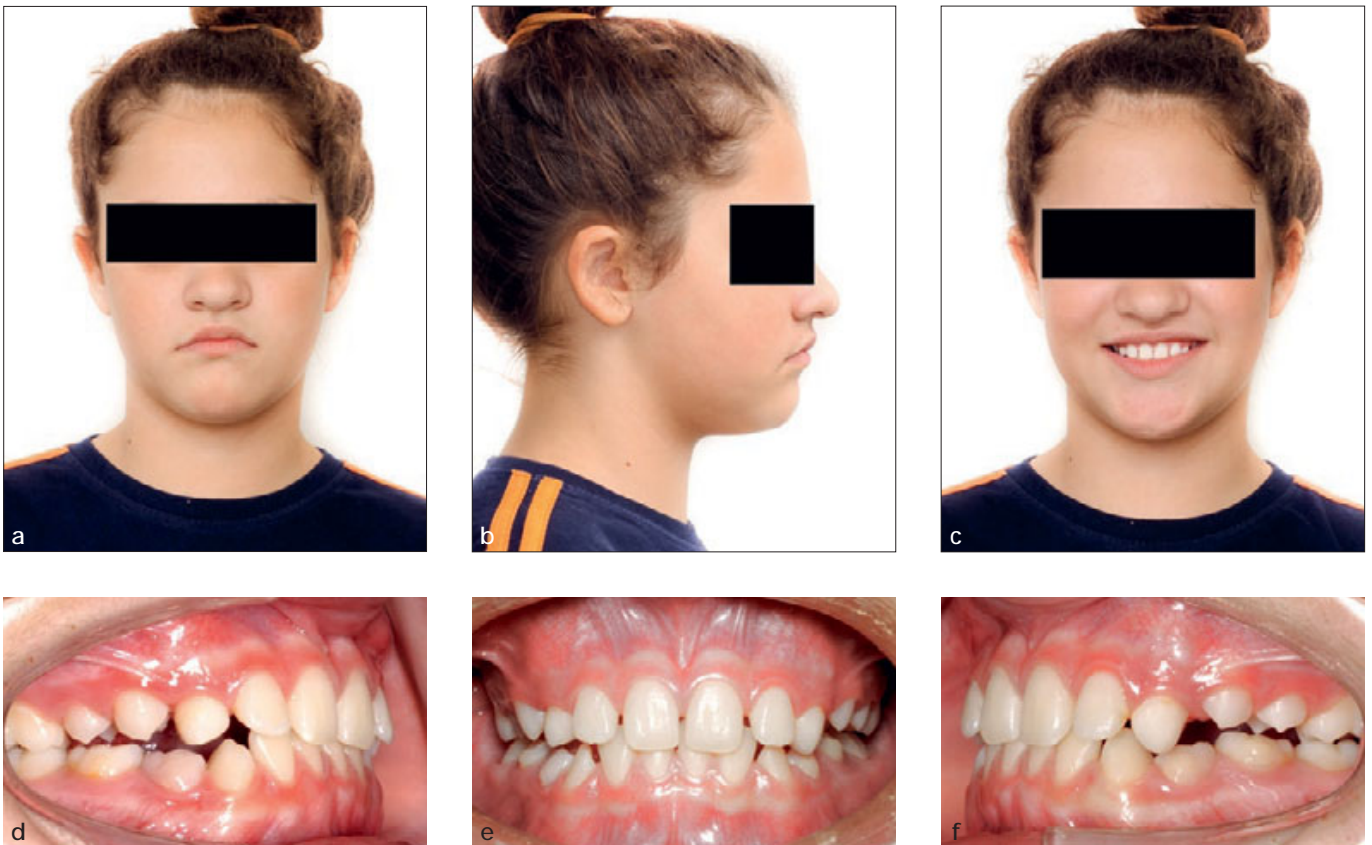
Figs 6a-i (a and b) Facial and intraoral aspects upon delivery of the face mask. (c to e) After 3 weeks, a removable lower splint was devised (PET-G foil, 1 mm) to support Class III elastics. (f to h) After 13 months, overcorrection of the molar relationship was observed, thus achieving an Angle Class II relationship. (i) The red arrows indicate composite resin retentions made in the cervical region of the posterior teeth.

The overall treatment time was 24 months. After this, no retainers were used in the maxilla or mandible (Figs 7 and 8). The development of the dentition was controlled

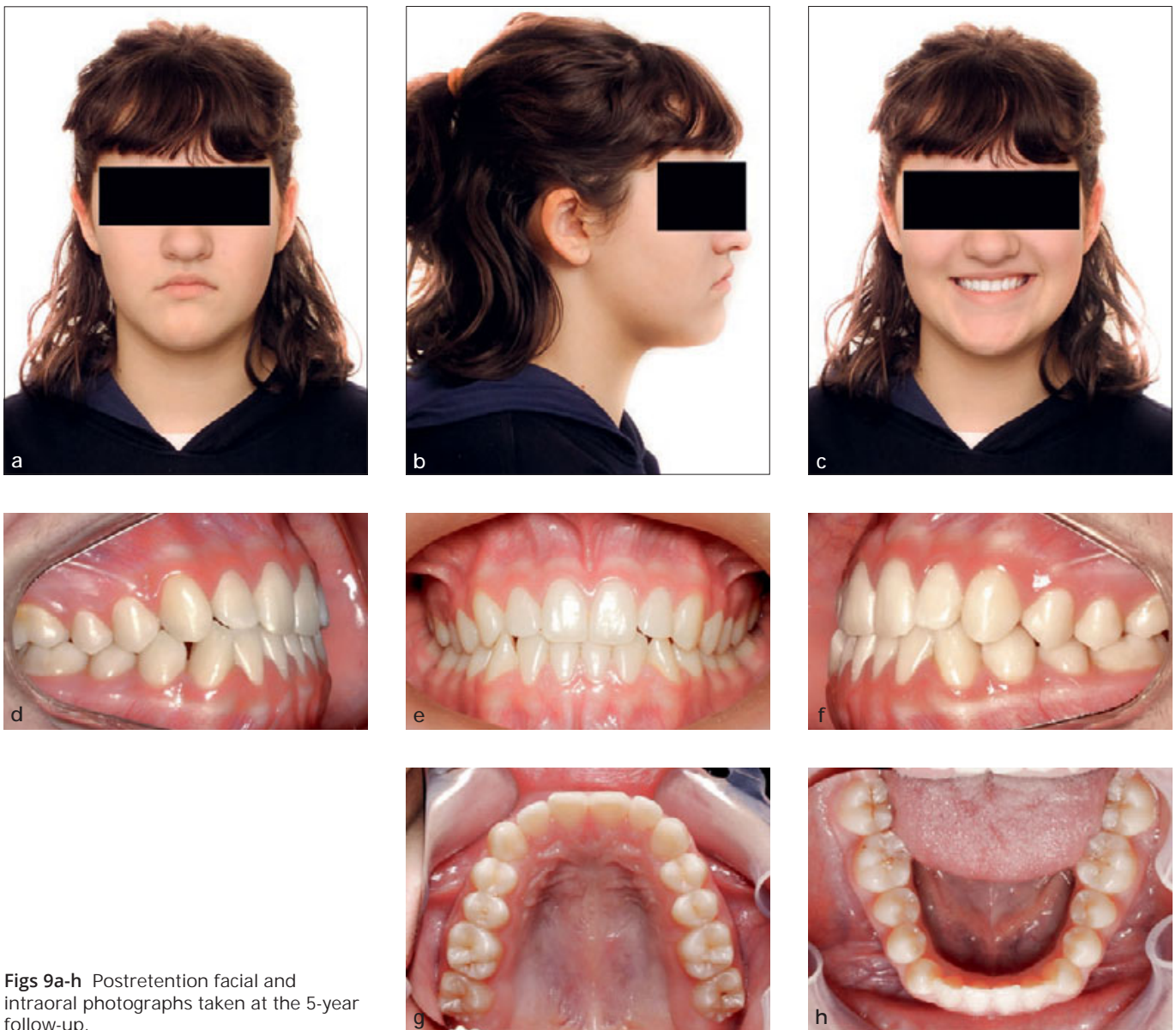periodically, twice a year, until the establishment of the permanent dentition, which occurred when the patient was 13 years old (Fig 9).



Figs 7a-b Posttreatment panoramic and lateral cephalometric radiographs.



Figs 8a-f Posttreatment facial and intraoral photographs.



Figs 9a-h Postretention facial and intraoral photographs taken at the 5-year follow-up.

Treatment results and follow-up

All the treatment goals were achieved during this early orthodontic intervention: the maxillary incisors were flared, the maxillary bone was widened and anteriorly displaced and the mandibular incisors were maintained retroclined. Major clearing of the upper airways and clockwise mandibular rotation also occurred, and the latter had direct repercussions on the lower facial height (Table 1 and Fig 7).

After treatment, a facial clinical examination demonstrated improved smile aesthetics. The buccal corridor and

profile were significantly modified, primarily as a result of maxillary expansion and protraction. The interarch relationship improved considerably, as shown by the bilateral Class I canine intercuspatation (Fig 8).

After 5 years of follow-up, all these outcomes appeared to be stable. Although the treatment presented some dental limitations (crowding, aligning and levelling, rotations, angulations and inclinations), as shown in Fig 9, the patient was pleased with the outcome and did not wish to undergo further corrective orthodontic treatment.

Discussion

One of the main steps in early Class III treatment is a precise diagnosis to define the aetiology and complexity of the malocclusion. After clinical examination and cephalometric analysis, two diagnostic points were fundamental to devising the treatment plan for the patient: there was a functional ACB in association with retroclined maxillary incisors and the patient presented with a skeletal Class III tendency with a sagittal and transverse maxillary deficiency. Although the literature has reported mandibular shift as a clinical characteristic of pseudo-Class III¹⁷, it should be underlined that even skeletal Class III can present this condition, especially if the maxillary incisors are retroclined, thus causing a premature contact during mandibular closure. For instance, even considering the skeletal Class III aetiology, an excellent prognosis for ACB was recognised when the patient presented an acceptable facial profile in centric relation, when the canines and molars were in or near a Class I relationship, and when the mandibular functional shift had been corrected⁷.

It is important to highlight the clear benefits of early correction of functional crossbite. According to Bock et al¹⁸, 50% of functional crossbite treatments that started in the late mixed dentition failed, compared to 15% in treatments started in the early mixed dentition. Thus, the first orthodontic strategy employed by the present authors was to use an aesthetic removable bite plane¹¹ that employs differential anchorage, promoting maxillary incisor proclination and distributing the reaction forces through the entire mandible (Fig 4). Furthermore, this appliance generates a premature contact in the incisor region, thus opening the bite and consequently facilitating ACB correction. As shown in Fig 5, the crossbite was corrected rapidly (1 month); however, the removable bite plane failed to establish an adequate horizontal and vertical overlap.

Sagittal and transverse maxillary deficiency were confirmed through cephalometric analysis⁹ and a facial clinical examination. According to McNamara Jr⁹, at 6 years of age, the mean midfacial (Co-A) and mandibular lengths (Co-Gn) should be 80 mm and 98 mm, respectively. As shown in Table 1, the patient seemed to present a real maxillary deficiency and mandibular prognathism. Thus, with the intention of intercepting skeletal Class III malocclusion, maxillary disjunction and protraction were planned. Studies have

suggested that early intervention for skeletal Class III is related to major orthopaedic effects and a reduced amount of dental compensation¹⁻³. In the same way, Mandall et al⁴ indicated that face mask use has the positive effect of reducing the requirement for future orthognathic surgery, finding that two-thirds of patients submitted to this treatment protocol did not need surgery and 68% presented positive horizontal overlap at 15 years of age. On the other hand, just one-third of control group patients (no treatment) did not need surgery⁴.

As can be seen in Fig 8, immediately after face mask removal, the patient presented a major midfacial improvement, especially with regard to the facial profile and buccal corridor. Although the treatment time of 24 months could be considered long, Class III overcorrection offers advantages in this first phase of orthodontic interception and seems to contribute towards long-term stability. Even after 5 years of follow-up, clinical examination noted the maintenance of a sagittal and transverse balance between the maxilla and mandible (Fig 9). Thus, the clinical and cephalometric observations described in Table 1 agree that Class III intervention in the early mixed dentition is apparently able to increase sagittal growth of the maxilla and therefore induce major favourable craniofacial changes, as previously described in the literature¹⁹.

Another interesting strategy used in the treatment of this patient was the employment of a removable mandibular splint with bonded buttons in the canine regions, devised to support Class III elastics. This device acted as an adjuvant to face mask use, encouraging excellent patient acceptance and compliance. In other words, a protocol involving concomitant use of a face mask and Class III elastics (daily and nightly) was established. The goals of these mechanics were to achieve overall mandibular retraction and assist maxillary protraction (Fig 6). Successful use of mandibular splints with Class III elastics has already been reported in early dentition (4 to 5 years of age) in patients with a normal or low-angle vertical relationship²⁰. The primary drawback of these mechanics was arguably the instability of the splint when using elastics. To overcome this issue, composite resin retentions were made in the cervical region of the posterior teeth to avoid displacement of the appliance (Fig 6).



Conclusions

The present study describes the early treatment of a functional ACB associated with skeletal Class III. The chosen clinical strategy involved use of an orthopaedic device associated with in-office aesthetic appliances. The treatment results highlighted the efficacy of these hybrid mechanics to compensate the mandible and protract the maxilla, and the 5-year follow-up seemed to demonstrate relative stability of the final outcome.

Declaration

The authors declare these are no conflicts of interest relating to this study.

References

1. Franchi L, Pavoni C, Cerroni S, Cozza P. Thin-plate spline analysis of mandibular morphological changes induced by early class III treatment: A long-term evaluation. *Eur J Orthod* 2014;36:425–430.
2. Nardoni DN, Siqueira DF, Cardoso MA, Capelozza Filho L. Cephalometric variables used to predict the success of interceptive treatment with rapid maxillary expansion and face mask. A longitudinal study. *Dental Press J Orthod* 2015;20:85–96.
3. Wendl B, Muchitsch AP, Winsauer H, et al. Retrospective 25-year follow-up of treatment outcomes in angle Class III patients: Early versus late treatment. *J Orofac Orthop* 2017;78:201–210.
4. Mandall N, Cousley R, DiBiase A, et al. Early class III protraction face-mask treatment reduces the need for orthognathic surgery: A multi-centre, two-arm parallel randomized, controlled trial. *J Orthod* 2016;43:164–175.
5. Baccetti T, Tollaro I. A retrospective comparison of functional appliance treatment of Class III malocclusions in the deciduous and mixed dentitions. *Eur J Orthod* 1998;20:309–317.
6. Vaid NR. Application of evidence in teaching and clinical protocols: Do we still nurture the “ostrich mindset”? [editorial]. *APOS Trends Orthod* 2014;4:1–2.
7. Zere E, Chaudhari PK, Sharan J, Dhingra K, Tiwari N. Developing Class III malocclusions: Challenges and solutions. *Clin Cosmet Investig Dent* 2018;10:99–116.
8. Lin JJ, White LW. Differential diagnosis and management of anterior crossbite (II) – Definitions. In: Lin JJ (ed). *Creative Orthodontics: Blending the Damon System & TADs to Manage Difficult Malocclusions*, ed 1. Taipei: Yong Chieh, 2007:17–26.
9. McNamara JA Jr. A method of cephalometric evaluation. *Am J Orthod* 1984;86:449–469.
10. Pereira CB, Mundstock CA, Berthold TB. *Introdução à Cefalometria Radiográfica*, ed 4. Porto Alegre: UFRGS Editora, 2010.
11. Dolci GS, Lopes JD, Ferreira AP, Cardon S. An aesthetic removable inclined plane. *J Clin Orthod* 2020;52:275–276.
12. Jirgensone I, Liepa A, Abeltins A. Anterior crossbite correction in primary and mixed dentition with removable inclined plane (Bruckl appliance). *Stomatologija* 2008;10:140–144.
13. Hamula W, Hamula DW, Hurt A. The hygienic rapid palatal expander. *J Clin Orthod* 1998;32:562–567.
14. Proffit WR, Fields HW, Sarver DM (eds). *Orthodontic treatment planning: Limitations, controversies and special problems*. In: *Contemporary Orthodontics*, ed 5. St Louis: Mosby, 2012:240–293.
15. Petit HP. The prognathic syndrome: A complete treatment plan around the facial mask [in French]. *Rev Orthop Dento Faciale* 1982;16:381–411.
16. AlSeraidi M, Hansa I, Dhaval F, Ferguson DJ, Vaid NR. The effect of vestibular, lingual, and aligner appliances on the quality of life of adult patients during the initial stages of orthodontic treatment. *Prog Orthod* 2021;22:3.
17. Kapur A, Chawla HS, Utreja A, Goyal A. Guiding the child's teeth with Class III dental malocclusion into correct occlusion: A clinician's parenting. *J Clin Pediatr Dent* 2018;42:72–78.
18. Bock NC, Klewitz H, Hudel H, Ruf S. Removable plate treatment of anterior forced crossbite. Effectiveness, efficiency, and potential outcome predictors. *J Orofac Orthop* 2015;76:283–293.
19. Baccetti T, Franchi L, McNamara JA Jr. Treatment and posttreatment craniofacial changes after rapid maxillary expansion and facemask therapy. *Am J Orthod Dentofacial Orthop* 2000;118:404–413.
20. Franchi L, Baccetti T. Splint therapy for skeletal Class III malocclusion in the primary dentition. *J Clin Pediatr Dent* 1998;22:93–98.