

## The effect of Le Fort I osteotomy on nasal form and function

**Language:** English

**Authors:** Dr.Dr. Sirichai Kiattavorncharoen<sup>1</sup>, Dr.Dr. Christian Kleier<sup>2</sup>, PD Dr.Dr. Richard Werkmeister<sup>2</sup>, Prof.Dr.Dr.Dr.h.c. Ulrich Joos<sup>2</sup>

<sup>1</sup>Department of Oral and Maxillofacial Surgery, Faculty of Dentistry, Mahidol University, Bangkok, Thailand

<sup>2</sup>Department of Cranio-Maxillofacial Surgery, Westphalian Wilhelms University of Muenster, Germany

**Date/Event/Venue:**

5-9 September 2000

XV<sup>th</sup> Congress of the European Association for Cranio-Maxillofacial Surgery

Edinburgh International Conference Centre, Edinburgh UK

### Introduction

The Le Fort I osteotomy is a versatile procedure used to correct a variety of dentofacial deformities of the maxilla. It was first described by von Langenbeck in 1859 (3). The most frequent complications include intraoperative hemorrhage, infection, nerve injury, oronasal fistula formation, relapse, dental injury, and rarely, avascular necrosis (4). The surgical goal in repositioning the maxilla is to establish a harmonious maxillomandibular dentoskeletal relationship and to achieve esthetic soft-tissue changes. It results also in alterations in the form and function of the nose (1,2).

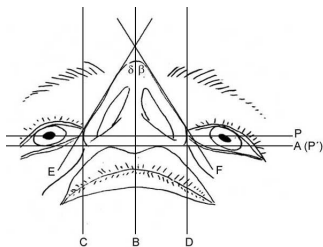
### Aim of the study

Aim of the present study was the prospective evaluation of the effect of Le Fort I osteotomy on nasal form and function.


### Materials and methods

Twenty-five patients who underwent Le Fort I osteotomy were included into the study over a 3-years period of time. Patients with cleft lip and/or cleft palate, rhinoplastic were excluded. Within the study group there were 13 females and 12 males with an age distribution between 16 and 38 years and a mean value of 26.7 years. Of these patients, 9 were treated for anterior, 8 for anterior/superior and 8 for anterior/inferior maxillary repositioning. 17 patients underwent bimaxillary osteotomy. The patients were examined pre-operatively (T0) and 6 month post-operatively (T1).

All of the patients underwent a clinical examination at T0 and T1 including the assessment of the nasal form and function. The nasal form was determined by measurement of the standardized raster photographs of the nose and lateral telerradiography. The distances and angles of the nasal base were determined (Fig. 1). The nasal profile was assessed by measurement of the nasofacial angle (NF), the nasolabial angle (NL), the angle between upper lip and Frankfort horizontal plane (L/FH), the angle between collumella and Frankfort horizontal plane (N/FH) and the nasocollumellar angle (NC) (Fig. 2). Nasal function was evaluated by anterior rhinomanometry with a rhinomanometer (Atmos Medizintechnik), whereby the overall flow and nasal resistance were determined (Fig. 3).



(a)



(b)

(c)

Fig.1 (a) The measurement of the standardized raster photograph of the nose.

- P: Bipupilar plane
- B: The middleline of the distance between internal canthus and perpendicular to P
- C: The line tangent to the right alar of the nose and perpendicular to P
- D: The line tangent to the left alar of the nose and perpendicular to P
- A: Nasal base plane
- P': The line parallel to P
- alpha: The angle between A and P'
- E: The line tangent to the right alar of nose and cross C
- F: The line tangent to the left alar of nose and cross D
- Beta: The angle between B and F
- delta: The angle between B and E
- CB + BD: The length of the nasal base
- B + delta: The angle of the nasal base

(b) Preoperative raster photograph of the nose (T0)

(c) Postoperative raster photograph of the nose (T1)

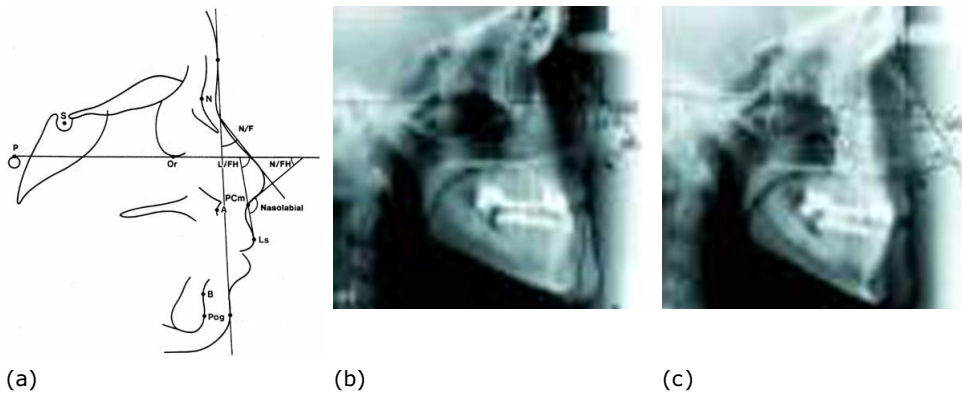


Fig. 2 (a) The nasal profile was assessed by measurement of the lateral teleradiography

The soft tissue angular measurements used in this study: the nasofacial angle (NF), the nasolabial angle (NL), the angle between upper lip and Frankfort horizontal plane (L/FH), the angle between collumella and Frankfort horizontal plane (N/FH) and the nasocollumellar angle (NC).

(b) Preoperative teleradiographic profile view (T0)

(c) Postoperative profile view of the same patient (T1)

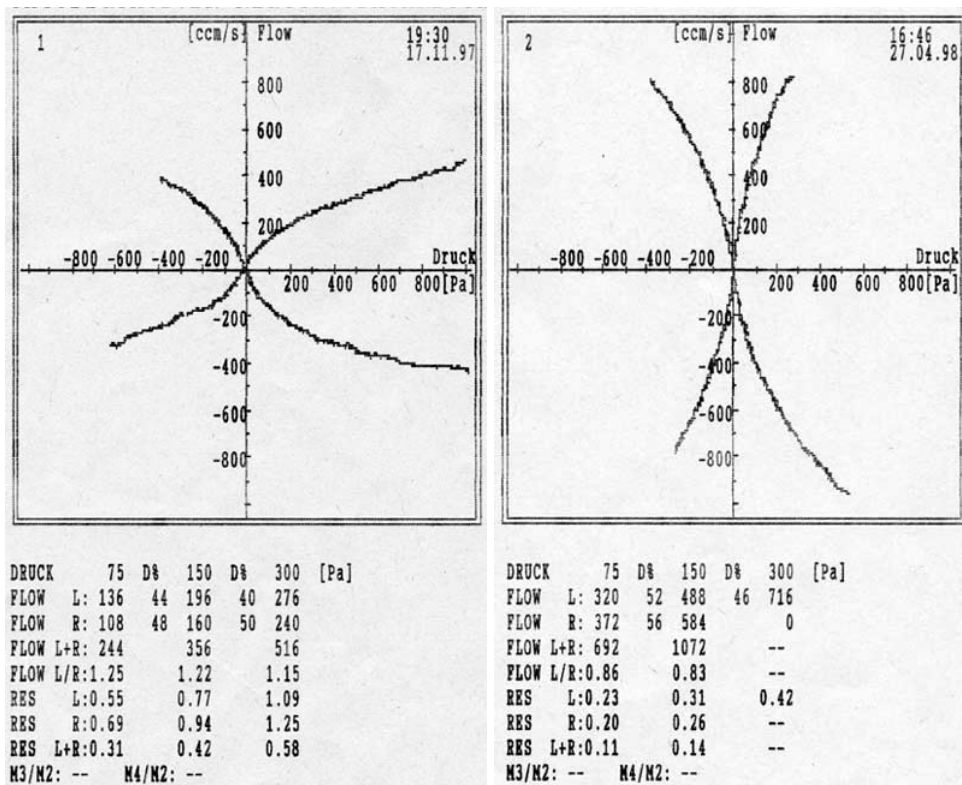


Fig. 3 (a) The preoperative anterior rhinomanometry shows pressure and overflow in the xy diagram.

(b) The postoperative rhinomanometry of the same patient

## Results

		T0	T1	p
Anterior maxillary repositioning	D (mm)	32.78	35.72	0.012
	A (Degree)	63.33	68.61	0.038
Anterior/superior maxillary repositioning	D (mm)	35.50	37.44	0.011
	A (Degree)	63.56	71.69	0.012
Anterior/inferior maxillary repositioning	D (mm)	33.56	35.38	0.021
	A (Degree)	53.56	62.00	0.012

Table 1. Finding of standardized raster photographs of the nose

D= The distance of the nasal base

A= The angle of the nasal base

		T0	T1	p
Anterior maxillary repositioning	NL (Degree)	100.67	105.56	0.341
	NF (Degree)	30.28	35.22	0.011
	N/FH (Degree)	15.56	17.67	0.122
	L/FH (Degree)	84.00	86.56	0.722
	NC (Degree)	67.17	67.33	0.944
	NL (Degree)	105.56	108.38	0.611
Anterior/superior maxillary repositioning	NF (Degree)	36.19	38.81	0.049
	N/FH (Degree)	19.38	19.69	0.865
	L/FH (Degree)	88.06	90.50	0.528
	NC (Degree)	69.50	68.75	0.671
Anterior/inferior maxillary repositioning	NL (Degree)	103.13	105.63	0.292
	NF (Degree)	31.31	32.50	0.326
	N/FH (Degree)	16.38	17.94	0.362
	L/FH (Degree)	87.00	88.56	0.673
	NC (Degree)	70.00	70.88	0.441

Table 2. Finding of the nasal profile from lateral telerradiography

		T0	T1	p
Anterior maxillary repositioning	nasal airflow (ccm/s)	411.56	637.33	0.038
	airway resistance	0.42	0.26	0.049
Anterior/superior maxillary repositioning	nasal airflow (ccm/s)	433.00	554.50	0.123
	airway resistance	0.40	0.37	0.233
Anterior/inferior maxillary repositioning	nasal airflow (ccm/s)	662.00	711.50	0.484
	airway resistance	0.31	0.25	0.440

Table 3. Rhinomanometric finding in patients with Le Fort I osteotomy

## Conclusion

Le Fort I osteotomy does not adversely affect nasal function (nasal breathing) but has an impact on nasal form (widening of the nasal base and increased angle of the nasal base), which however is not seen in the nasal profile.

## References

1. Götzfried HF, Masing H. On the improvement of the nasal breathing following mid-face osteotomies, and possible reasons for the phenomenon. *J max-fac Surg* 1984; 12: 29-32.
2. Götzfried HF, Paulus GW. Die Verbreiterung der Nasenbasis nach maxillären Dysgnathiekorrekturen. *Dtsch Z Mund Kiefer GesichtsChir* 1986; 10: 429-32.
3. Langenbeck BV. Beiträge zur Osteoplastik- Die osteoplastische Resektion des Oberkiefers. In: Göschen A. *Deutsch Klinik*. Reimer, Berlin 1859.
4. Sailer HF, Haers PE. Komplikationen bei bimaxillären chirurgischen Eingriffen. *Fortschr Kiefer GesichtsChir* 1995; 40: 41-9.

**Correspondence address:**

Dr. Dr. Sirichai Kiattavorncharoen

Department of Oral and Maxillofacial Surgery

Faculty of Dentistry

Mahidol University

Yothi Street

Bangkok 10400

Thailand

**Poster Faksimile:**



Department of  
Cranio-Maxillofacial Surgery  
Münster



Westphalian Wilhelms University  
Münster

**The effect of Le Fort I osteotomy on nasal form and function**

Kiattavorncharoen S, Kleier C, Werkmeister R, Joos U

Department of Cranio-Maxillofacial Surgery, Westphalian Wilhelms University of Münster, Germany

(Head: Prof. Dr. med. Dr. med. dent. Dr. h.c. U. Joos)

**Introduction**

The Le Fort I osteotomy is a versatile procedure used to correct a variety of dentofacial deformities of the maxilla. It was first described by von Langenbeck in 1859 (3). The most frequent complications include intraoperative hemorrhage, infection, nerve injury, oronasal fistula formation, relapse, dental injury, and rarely, avascular necrosis (4). The surgical goal in repositioning the maxilla is to establish a harmonious maxillomandibular dentoalveolar relationship and to achieve esthetic soft-tissue changes. It results also in alterations in the form and function of the nose (1,2).

**Aim of the study**

Aim of the present study was the prospective evaluation of the effect of Le Fort I osteotomy on nasal form and function.

**Materials and methods**

Twenty-five patients who underwent Le Fort I osteotomy were included into the study over a 3-years period of time. Patients with cleft lip and/or cleft palate, rhinoplastic were excluded. Within the study group there were 13 females and 12 males with an age distribution between 16 and 38 years and a mean value of 26.7 years. Of these patients, 9 were treated for anterior, 8 for anterior/superior and 8 for anterior/inferior maxillary repositioning. 17 patients underwent bimaxillary osteotomy. The patients were examined pre-operatively (T<sub>0</sub>) and 6 months post-operatively (T<sub>1</sub>).

All of the patients underwent a clinical examination at T<sub>0</sub> and T<sub>1</sub> including the assessment of the nasal form and function. The nasal form was determined by measurement of the standardized raster photographs of the nose and lateral telerradiography. The distances and angles of the nasal base were determined (Fig. 1). The nasal profile was assessed by measurement of the nasofacial angle (NF), the nasolabial angle (NL), the angle between upper lip and Frankfort horizontal plane (L/FH), the angle between columella and Frankfort horizontal plane (N/FH) and the nasocolumellar angle (NC) (Fig. 2). Nasal function was evaluated by anterior rhinomanometry with a rhinomanometer (Atmos Medizintechnik), whereby the overall flow and nasal resistance were determined (Fig. 3).

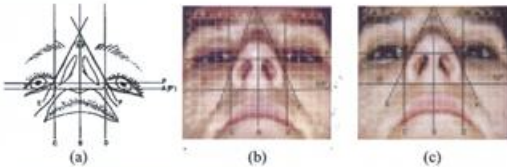


Fig. 1 (a) The measurement of the standardized raster photographs of the nose.

- P: Bipupillar plane
- B: The midline of the distance between internal canthos and perpendicular to P
- C: The line tangent to the right side of the nose and perpendicular to P
- D: The line tangent to the left side of the nose and perpendicular to P
- A: Nasal base plane
- F: The line parallel to P
- E: The angle between A and F
- E: The line tangent to the right side of nose and cross C
- F: The line tangent to the left side of nose and cross D
- B: The angle between B and P
- E: The angle between E and F
- CB + BD: The length of the nasal base
- β + δ: The angle of the nasal base

(b) Preoperative raster photograph of the nose (T<sub>0</sub>)

(c) Postoperative raster photograph of the nose (T<sub>1</sub>)

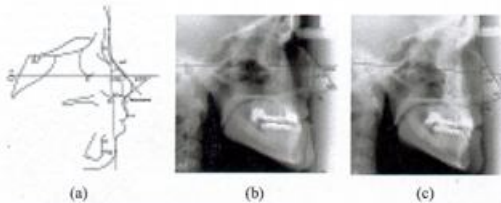


Fig. 2 (a) The nasal profile was assessed by measurement of the lateral telerradiography

The soft tissue angular measurements used in this study: the nasofacial angle (NF), the nasolabial angle (NL), the angle between upper lip and Frankfort horizontal plane (L/FH), the angle between columella and Frankfort horizontal plane (N/FH) and the nasocolumellar angle (NC).

(b) Preoperative telerradiographic profile view (T<sub>0</sub>)

(c) Postoperative profile view of the same patient (T<sub>1</sub>)

**References**

1. Götzfried HF, Masing H. On the improvement of the nasal breathing following mid-face osteotomies, and possible reasons for the phenomenon. *J max-fac Surg* 1984; 12: 29-32.
2. Götzfried HF, Paulus GW. Die Verbreiterung der Nasenbasis nach maxillären Dysgnathiekorrekturen. *Dtsch Z Mund Kiefer Gesichtschir* 1986; 10: 429-32.
3. Langenbeck BV. Beiträge zur Osteoplastik- Die osteoplastische Resektion des Oberkiefers. In: Göschen A. *Deutsch Klinik*. Reimer, Berlin 1859.
4. Sailer HF, Haers PE. Komplikationen bei bimaxillären chirurgischen Eingriffen. *Fortschr Kiefer Gesichtschir* 1995; 40: 41-9.

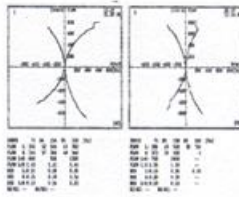


Fig. 3 (a) The preoperative anterior rhinomanometry shows pressure and overflow in the xy diagram.

(b) The postoperative rhinomanometry of the same patient

**Results**

		T0	T1	p
Anterior maxillary repositioning	D (mm)	32.78	35.72	0.012
	A (Degree)	63.33	68.61	0.038
Anterior/superior maxillary repositioning	D (mm)	35.50	37.44	0.011
	A (Degree)	63.56	71.69	0.012
Anterior/inferior maxillary repositioning	D (mm)	33.56	35.38	0.021
	A (Degree)	53.56	62.00	0.012

Table 1. Finding of standardized raster photographs of the nose  
D= The distance of the nasal base  
A= The angle of the nasal base

		T0	T1	p
Anterior maxillary repositioning	NL (Degree)	100.67	105.56	0.341
	NF (Degree)	30.28	35.22	0.011
	N/FH (Degree)	15.56	17.67	0.122
	L/FH (Degree)	84.00	86.56	0.722
Anterior/superior maxillary repositioning	NC (Degree)	67.17	67.33	0.944
	NL (Degree)	105.56	108.38	0.611
	NF (Degree)	36.19	38.81	0.049
	N/FH (Degree)	19.38	19.69	0.865
Anterior/inferior maxillary repositioning	L/FH (Degree)	88.06	90.50	0.528
	NC (Degree)	69.90	68.75	0.671
	NL (Degree)	103.13	105.63	0.292
	NF (Degree)	31.31	32.50	0.326
Anterior/superior maxillary repositioning	N/FH (Degree)	16.38	17.94	0.362
	L/FH (Degree)	87.00	88.56	0.673
	NC (Degree)	70.00	70.88	0.441

Table 2. Finding of the nasal profile from lateral telerradiography

		T0	T1	p
Anterior maxillary repositioning	nasal airflow (ccm/s)	411.56	637.33	0.038
	airway resistance	0.42	0.26	0.049
Anterior/superior maxillary repositioning	nasal airflow (ccm/s)	433.00	554.50	0.123
	airway resistance	0.40	0.37	0.233
Anterior/inferior maxillary repositioning	nasal airflow (ccm/s)	662.00	711.50	0.484
	airway resistance	0.31	0.25	0.440

Table 3. Rhinomanometric finding in patients with Le Fort I osteotomy

**Conclusion**

Le Fort I osteotomy does not adversely affect nasal function (nasal breathing) but has an impact on nasal form (widening of the nasal base and increased angle of the nasal base), which however is not seen in the nasal profile.