

# Endoscope-assisted Surgery in the Treatment of Dentigerous Cyst Involving the Maxillary Sinus – Report of Two Cases

Shi Hao LI<sup>1</sup>, Yan WANG<sup>1</sup>, Zi Xian HUANG<sup>1</sup>, Ting Ting JIN<sup>1</sup>, Zhi Quan HUANG<sup>1</sup>

*Endoscopic techniques have been applied to oral and maxillofacial surgeries. Previous studies have proved their practicability in the treatment of osteomyelitis of the mandible and displaced residual roots in the maxillary sinus. In this report, two patients with dentigerous cysts in the maxillary sinus underwent endoscope-assisted curettage. Both patients were successfully cured without recurrent lesions or any complications. The follow-up found that the bone cavities had shrunk. An endoscope-assisted Caldwell-Luc operation provided clear visibility of the surgical field and preserved the mucosa of the maxillary sinus.*

**Key words:** Caldwell-Luc operation, dentigerous cyst, endoscopic-assisted surgery, maxillary sinus

*Chin J Dent Res 2020;23(1):71–76; doi: 10.3290/j.cjdr.a44338*

Dentigerous cysts (DCs) account for about 24% of odontogenic cysts. They are thought to be related to impacted teeth such as the third molar of the mandible or maxilla, maxillary canines and premolars<sup>1</sup>. Early in 2005, Fang G<sup>2</sup> proposed that, according to the lesion location and the adjacent structures involved, treatment for dentigerous cysts in the maxillary sinus should be classified into four types: Class I, limited lesion, not involving the normal teeth or nerve; Class I subclass, involving the maxillary sinus; Class II, involving the maxillary sinus or nasal cavity, which may lead to oronasal fistula; Class III, involving normal teeth or nerve; Class IV, extensive lesion, not involving the normal teeth or nerve. Fenestration and elective curettage or enucleation were proposed to be suitable for Class I, II, and III among the four types, while enucleation and radical maxillary sinusotomy were suitable for Class IV. Currently, the extent of curettage or enucleation is primarily based on the surgeon's experience because the lesion cannot be observed directly.

With the development of endoscopic techniques, endoscopically assisted examinations and surgeries have recently become widely used and reported in the oral and maxillofacial field, including periodontal endoscopic examination and endoscope-assisted reconstruction of the mandibular condyle. Previously, we have reported<sup>3,4</sup> the possibility of applying endoscopy in the treatment of residual roots of the mandibular wisdom teeth located in the lingual space of the mandible, and for odontogenic peripheral osteomyelitis of the posterior mandible with residual roots displaced into the maxillary sinus. All cases mentioned above achieved good outcomes without recurrences.

In the present report, dentigerous cysts in the maxillary sinus were diagnosed by preoperative computed tomography (CT) scans and panoramic radiographs. After consultation with an experienced ear, nose and throat (ENT) surgeon, we chose the endoscopy-assisted Caldwell-Luc operation to approach the cysts. This method allowed us to gain excellent visibility in the surgical field for enucleation, avoiding large amounts of damage and preserving the alveolar bone for healing.

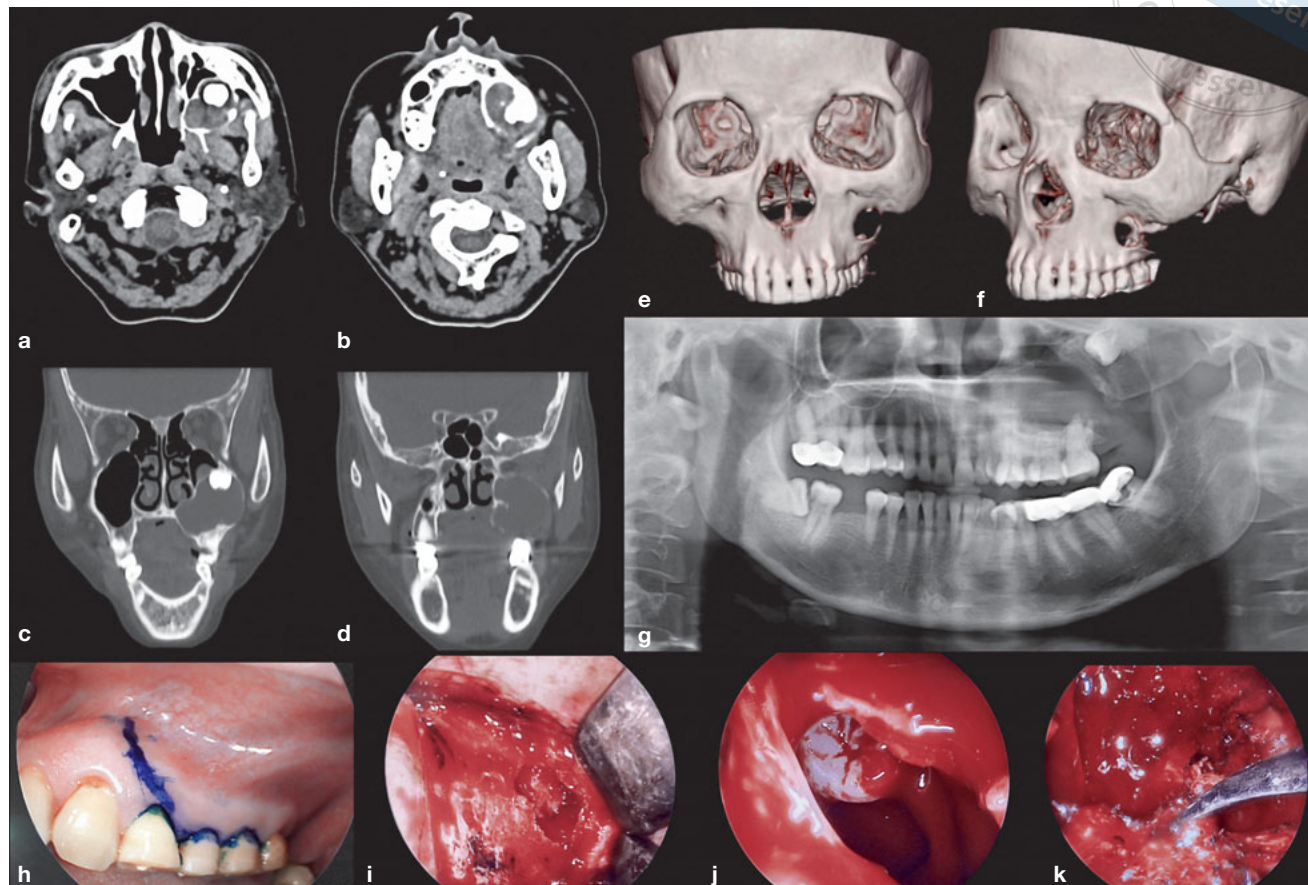
## Case reports

### *Endoscopic system*

A KARL STORZ endoscope system (cat. no: 22201020, Karl Storz, Tuttlingen, Germany) was used during the surgeries. A searching-unit medical endoscope with a

<sup>1</sup> Department of Oral and Maxillofacial Surgery, Sun Yat-sen Memorial Hospital of Sun Yat-sen University, Guangzhou, P.R. China.

**Corresponding author:** Dr Zhi Quan HUANG, Department of Oral and Maxillofacial Surgery, Sun Yat-sen Memorial Hospital of Sun Yat-sen University, 107 Yan-Jiang Road, Guangzhou 510120, P.R. China. Tel: 86-20-81332471. Email: Zhiquanhuang1978@126.com



**Fig 1** Case I: The computed tomography (CT) scan shows an ectopic tooth with soft mass in the left maxillary sinus: **(a)** and **(b)** for the transversal plane; **(c)** and **(d)** for the coronal plane. **(e)** and **(f)** 3D CT reconstruction. **(g)** Panoramic radiograph of the left maxillary sinus cyst. **(h)** Incision at the gingival sulcus down to the bone. **(i)** Bone window with a size of 2 cm × 1.5 cm. **(j)** Ectopic tooth. **(k)** Root curettage for the involved teeth.

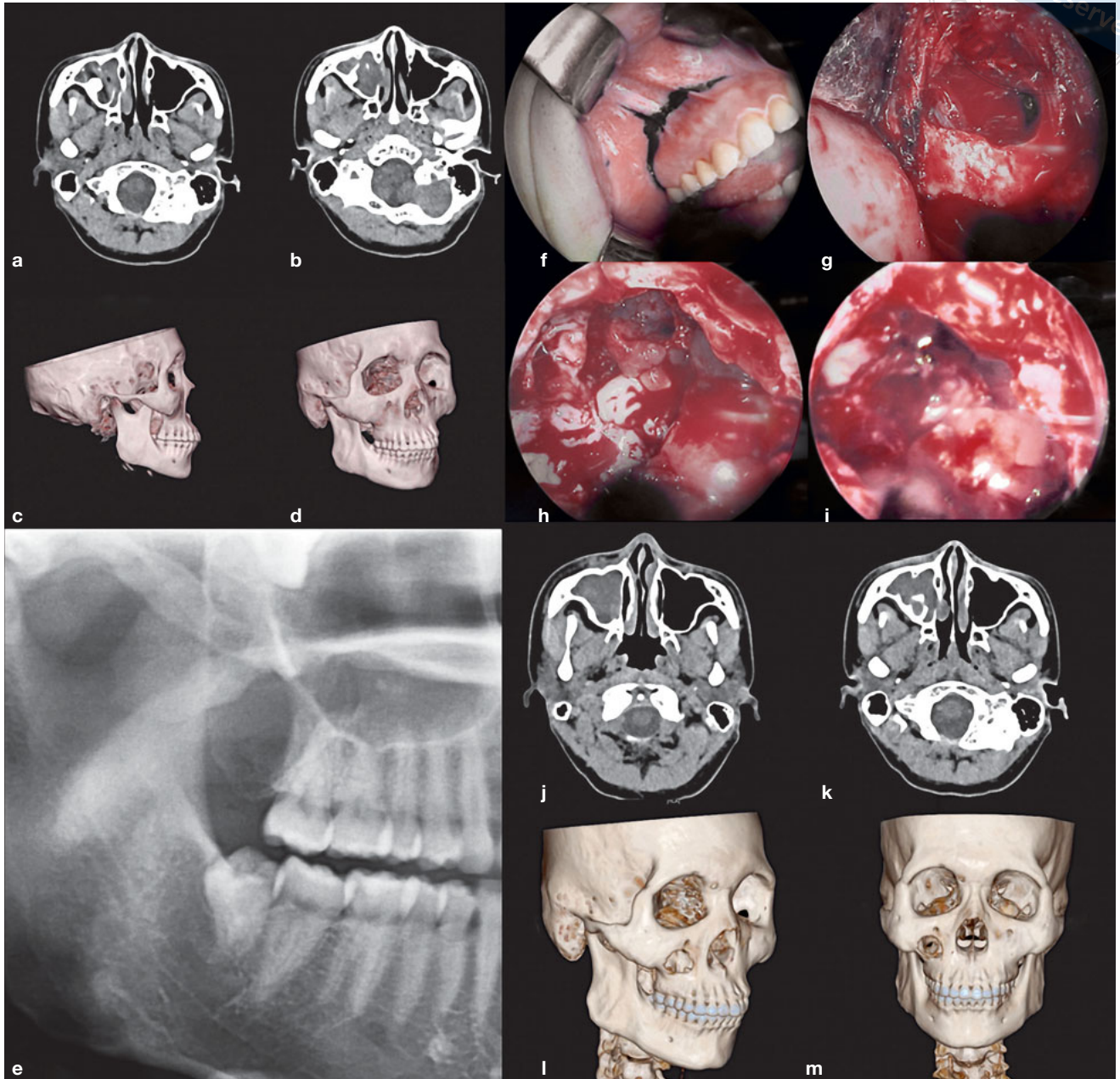
cold light-type Xenon Nova 300 (20134020) 3-Chip HD Camera (222220055-3, Karl Storz) was used to record the surgery.

*Patients*

Between March 2017 and March 2018, two patients diagnosed with dentigerous cysts who underwent endoscope-assisted curettage through the Caldwell-Luc technique were enrolled. All procedures were fully explained to the patients, who gave their signed informed consent. The Ethical Review Board of the Sun Yat-sen Memorial Hospital approved the study. The two patients had Class I, II or III dentigerous cysts; they underwent CT and panoramic radiographs that revealed the lesion with the postoperative pathological diagnoses being defined as dentigerous cyst.

*Case I*

A 56-year-old healthy female was referred to the Department of Oral and Maxillofacial Surgery, Sun Yat-sen Memorial Hospital at the Sun Yat-sen University with the chief complaint of recurrent distending pain of the left cheek that had been present for a month. This was associated with a yellow purulent discharge from the left maxillary posterior teeth for several days. A physical examination revealed a bony swelling of the left superior maxillary region and the hard palate area. No lesions of the teeth or oral mucosa were found. A panoramic radiograph revealed an ectopic tooth appearing to lie between the posterior walls of the left maxillary sinus. To precisely locate this tooth, three-dimensional (3D) CT scans of the paranasal sinuses were obtained, revealing the crown of an ectopic tooth located in the posteromedial wall of



**Fig 2** Case II: The computed tomography (CT) scan shows an ectopic tooth with a soft mass in the right maxillary sinus: **(a)** and **(b)** for the transversal plane. **(c)** and **(d)** Preoperative 3D CT reconstruction. **(e)** Panoramic radiograph of the right maxillary sinus cyst. **(f)** Incision at the gingival sulcus mucosa down to the bone. **(g)** Bone window. **(h)** Ectopic tooth. **(i)** Unharmed mucosa of the maxillary sinus. **(j)** and **(k)** Postoperative CT scan. **(l)** and **(m)** Postoperative 3D CT reconstruction.

the maxillary sinus. Its root entered the bony wall, and there was a large, well-circumscribed lesion surrounded by a soft mass measuring 4 × 4 cm. The diagnosis of an infected dentigerous cyst was made based on the CT scan (Fig 1a to g).

### Case II

A 21-year-old healthy male complained of pus in the maxillary molar teeth for 2 months. A panoramic radiograph revealed an ectopic tooth lying between the posterior walls of the right maxillary sinus with a 3 cm × 5 cm surrounding soft mass. The diagnosis of an infected dentigerous cyst was made based on the CT scan (Fig 2a to e).

### *Surgical technique*

General anaesthesia was obtained through nasal intubation. Anerdian III was used for oral sterilisation. To expose the maxillary anterolateral sinus wall, an incision was made at the gingival margin mucosa down to the bone and gingival flap (Figs 1h and 2f). A bone window of the maxillary anterolateral sinus wall was cut using a bone chisel above the root apices extending from the first premolar, or from the second premolar to the second molar, to make a bone lid of 2 cm × 1.5 cm (Figs 1i and 2g). The cyst wall was shown clearly by the endoscope. The surgeon placed a foreign body forceps into the maxillary sinus through the same bone window and removed the tooth after cyst curettage (Fig 1j and 2h). Curettage was performed for the involved tooth roots (Fig 1k). It should be noted that the mucosa of the maxillary sinus was preserved (Fig 2i). During the surgery, copious irrigation of the sinus with normal sterile saline was performed to maintain a clear visual field and to clear any remaining infectious material. The maxillary sinus was filled in with a piece of absorbable haemostatic cotton, and sutures were used to draw the mucosa to close the wound. A sample of thickened maxillary sinus mucosa was sent for routine pathological examination at the same hospital (Sun Yat-sen Memorial Hospital at the Sun Yat-sen University).

### *Follow-up*

Both patients were cured by the reported treatment approach. Previous symptoms disappeared. In both cases, complications of facial paraesthesia, nasal obstruction, infection and haemorrhage were not detected after surgery. No recurrence was found during the 6- to 12-month follow-up.

### **Discussion**

Dentigerous cyst (DC) is the second most common cyst of the dental arches, comprising 14% to 20% of all jaw cysts. DCs found in the third molars of the mandible account for 75% of all DCs<sup>5,6</sup>. Those in the maxillary sinus are extremely rare.

The traditional Caldwell-Luc approach is used to remove all lesions in the maxillary sinus. However, complications of the standard Caldwell-Luc operation include facial swelling, cheek discomfort, toothaches, facial asymmetry, facial paraesthesia after extensive sinus mucosa removal and loss of the partial bony wall of the canine fossa, which should not be neglected<sup>7,8</sup>. Although the traditional Caldwell-Luc approach can

provide clear vision and expose the surgical field, it can cause large surgical injuries and is associated with many serious postoperative complications. Functional endoscopic sinus surgery (FESS) and an improved Caldwell-Luc approach have been encouraged. Joe Jacob et al<sup>7</sup> performed a comparative study of FESS and the Caldwell-Luc operation, and proposed that each surgical technique had advantages and disadvantages. Patients might sustain cheek oedema, infraorbital numbness/neuralgia and polyps in the middle meatus more often after the Caldwell-Luc approach than the FESS, while patients might sustain crusts in the middle meatus and oedema of the middle meatus after the FESS. Xu et al<sup>8</sup> suggested that bony lids re-implanted by titanium plates could help reduce complications associated with the Caldwell-Luc approach. However, it is uncertain whether the lids were replaced effectively, and the implanted plates could cause infections.

Studies on DCs in the maxillary sinus are seldom discussed due to the low morbidity of this disease. Generally, most DCs are treated using the Caldwell-Luc surgical removal because of the good operating field<sup>9-11</sup>. Although the lesions can be completely removed, the surgical results are often associated with more trauma and complications.

To reduce complications, endoscopic surgery carried out via the inferior or middle nasal meatus for cystic enucleation is being applied, with the assistance of a cutting aspirator in some cases. The transnasal approach provides satisfactory exposure and can leave the sinus mucosa intact. Endoscopic surgery via the canine fossa and the anterior wall of the maxillary sinus has also been reported. Despite mucosal preservation and fewer complications, these approaches damage the anterior wall of the maxillary sinus, resulting in facial depression. In addition, endoscopic surgery needs to be performed in the nasal cavity and requires nasal packing postoperatively, causing suffering despite topical anaesthesia. Furthermore, elimination of the osteomeatal complex breaks the intact natural ostium, and the mucus produced in the maxillary sinus is transported by ciliary beating from the floor of the sinus in star-like routes along the walls of the sinus to the natural ostium. Sinusitis may occur as a result of the impairment of natural ostium because this is important for drainage and the surrounding cilia. Inferior meatal antrostomy has been criticised due to injuries to the nasolacrimal duct as well as to the narrow field of view, moderate learning curve, and difficulty in operations with dead angles. It is not adequate for removal through a small orifice of large lesions and cysts that lie medially, or that contain impacted teeth, DC and dental roots in the maxillary sinus.

A complete endoscopic medial maxillectomy does not need to be a default surgical approach for all maxillary odontogenic tumours. We approached these lesions by performing an initial maxillary antrostomy and then enlarging the opening to the size necessary to achieve the surgical objective. Since in most instances the size of an ectopic tooth is larger than the maxillary sinus ostium, it is not feasible to access the lesion by FESS. The surgical approach reported here provided a bone window on the anterolateral wall of the maxillary sinus, with less bone loss, clean cuts and easy bone lid replantation, maintaining the integrity of the maxillary sinus wall and avoiding facial depression. Only enucleating the cyst and tooth, and keeping the normal maxillary sinus mucosa, help the maxillary sinus return to normal and prevent the patients from feeling pressure, pain and other symptoms after the Caldwell-Luc operation. To prevent postoperative haemorrhage and infection, we used a gelatin sponge instead of iodoform gauze to pack defects, leaving the maxillary sinus mucosa in place without inferior meatal antrostomy to avoid a second operation window.

Oral endoscopy has been widely used and widely discussed in recent years. Endoscopy is a procedure in which the physician is able to look inside the patient's body; it is a technique that can be used to improve the visualisation of surgical sites, including those with difficult access. In the oral area, endoscopy is used in periodontal, implant and alveolus surgeries<sup>4,12</sup>. For maxillofacial surgery, some authors<sup>13-16</sup> have reported successful mandibular condylar reconstructions using a costochondral graft with endoscopic assistance through a modified preauricular approach, giving good aesthetic and functional results. In the past decade, authors have reported the successful removal of roots<sup>12</sup> and dental implants<sup>17</sup> displaced into the maxillary sinus via endoscopy. For tumours in the maxillary sinus, reports<sup>18,19</sup> have proposed that a combination of endoscopic sinus surgery and the Caldwell-Luc operation is effective.

Based on this evidence, we believe that the endoscope-assisted technique has at least four advantages: direct and clear vision during the operation; less bleeding and nerve injury; minimised and hidden incision that prevents obvious scarring to the face; and the fact that the technique can be applied conveniently and efficiently with good training.

### Conflicts of interest

The authors declare no conflicts of interest related to this study.

### Author contribution

Dr Shi Hao LI took part in the surgery, collected data, drafted and revised the manuscript; Dr Yan WANG designed the study, took part in the surgery and collected data; Dr Zi Xian HUANG analysed the data and revised the manuscript; Dr Ting Ting JIN collected and interpreted the clinical data; Dr Zhi Quan HUANG designed the study, took part in the surgery and approved the final manuscript.

(Received Mar 28, 2019; accepted Jul 2, 2019)

### References

1. Xu GZ, Jiang Q, Yang C, Yu CQ, Zhang ZY. Clinicopathologic features of dentigerous cysts in the maxillary sinus. *J Craniofac Surg* 2012;23:e226-e231.
2. Yang G, Su DH, Liu C, Wang N. Selection of treatment on dentigerous cysts. *Jun Yi Jin Xiu Xue Yuan Xue Bao (Academic Journal of PLA Postgraduate Medical School)* 2005; 26:214-215. [In Chinese]
3. Huang ZQ, Huang ZX, Wang YY, et al. Removal of the residual roots of mandibular wisdom teeth in the lingual space of the mandible via endoscopy. *Int J Oral Maxillofac Surg* 2015;44:400-403.
4. Huang Z, Huang Z, Zhang D, Hu H, Liang Q, Chen W. Endoscopically-assisted operations in the treatment of odontogenic peripheral osteomyelitis of the posterior mandible. *Br J Oral Maxillofac Surg* 2016;54:542-546.
5. Avelar RL, Antunes AA, Carvalho RW, Bezerra PG, Oliveira Neto PJ, Andrade ES. Odontogenic cysts: a clinicopathological study of 507 cases. *J Oral Sci* 2009;51:581-586.
6. Avitia S, Hamilton JS, Osborne RF. Dentigerous cyst presenting as orbital proptosis. *Ear Nose Throat J* 2007;86:23-24.
7. Joe Jacob K, George S, Preethi S, Arunraj VS. A comparative study between endoscopic middle meatal antrostomy and caldwell-luc surgery in the treatment of chronic maxillary sinusitis. *Indian J Otolaryngol Head Neck Surg* 2011;63:214-219.
8. Xu GZ, Yang C, Fan XD, Hu YK, Yu CQ. Functional surgery for the treatment of dentigerous cyst in the maxillary sinus. *J Craniofac Surg* 2015;26:e84-e86.
9. Matheny KE, Duncavage JA. Contemporary indications for the Caldwell-Luc procedure. *Curr Opin Otolaryngol Head Neck Surg* 2003;11:23-26.
10. Saito H, Takanami N, Saito T, Wakui S, Fujieda S. Studies on the Caldwell-Luc operation with or without counteropening at the inferior meatus. *ORL J Otorhinolaryngol Relat Spec* 1990;52:249-253.
11. Buyukkurt MC, Omezli MM, Miloglu O. Dentigerous cyst associated with an ectopic tooth in the maxillary sinus: a report of 3 cases and review of the literature. *Oral Surg Oral Med Oral Pathol Oral Radiol* 2010;109:67-71.
12. Wang X, Li S, Huang Z, Cai Q, Huang Z, Chen W. Removal of the residual roots displaced into the maxillary sinus via endoscopy. *J Craniofac Surg* 2018;29:1034-1036.
13. Troulis MJ, Kaban LB. Endoscopic approach to the ramus/condyle unit: clinical applications. *J Oral Maxillofac Surg* 2001;59:503-509.
14. Troulis MJ, Williams WB, Kaban LB. Endoscopic mandibular condylectomy and reconstruction: early clinical results. *J Oral Maxillofac Surg* 2004;62:460-465.
15. Wang YL, Yang C, Chen MJ, Qiu YT, Zhang SY. One-staged orthognathic surgery and arthroscope-assisted condylar reconstruction with costochondral graft. *Zhonghua Zheng Xing Wai Ke Za Zhi (Chinese Journal of Plastic Surgery)* 2009;25:17-20. [In Chinese]

16. Qiu YT, Yang C, Chen MJ. Endoscopically assisted reconstruction of the mandibular condyle with a costochondral graft through a modified preauricular approach. *Br J Oral Maxillofac Surg* 2010;48:443–447.
17. Jin T, Wang Y, Li S, Cai Q, Huang Z. Removal of the dental implant displaced into the maxillary sinus through the inferior nasal meatus via transnasal endoscopy. *J Craniofac Surg* 2019;30:1178–1179.
18. Chao C, You J, Qiu J. Endoscopic sinus surgery for the treatment of nasal inverted papilloma. *Lin Chuang Er Bi Yan Hou Tou Jing Wai Ke Za Zhi (Journal of Clinical Otorhinolaryngology Head and Neck Surgery)* 2007;21:789–790. [In Chinese]
19. Lian F, Juan H. Different endoscopic strategies in the management of recurrent sinonasal inverted papilloma. *J Craniofac Surg* 2012;23:e44–e48.

