

# Accuracy of Computer-Guided Implant Surgery by a CAD/CAM and Laser Scanning Technique

Xue Zhu ZHAO<sup>1</sup>, Wei Hua XU<sup>2</sup>, Zhi Hui TANG<sup>1</sup>, Min Jie WU<sup>1</sup>, Jie ZHU<sup>1</sup>, Si CHEN<sup>1</sup>

**Objectives:** *To explore the method of manufacturing an implant surgery template with a computer-aided design/computer-aided manufacturing (CAD/CAM) technique and evaluate its precision in clinical cases.*

**Methods:** *Patients referred to the 2nd Dental Center of Peking University who were partially edentulous, were enrolled and scanned with cone beam computed tomography (CBCT). Diagnostic casts were laser scanned to record the configuration of the patients' dentition and mucosae. CBCT and laser scanning data were subsequently loaded into Simplant software. Implant positions were planned in the software with a computer-aided design technique, and surgical templates were fabricated with a rapid prototyping technique. These templates were used to guide implant placement surgery.*

**Results:** *The mean value of linear deviation was 1.00 mm (range 0 to 2.16 mm) for implant shoulder and 1.26 mm (range 0.51 to 2.86 mm) for the implant apex. The mean angular deviation was 4.74 degree (0.37 to 10.28 degrees). Deviations were higher in the posterior region than anterior. The tooth-supported template provided higher precision than did the tooth/mucosa-supported template, but no statistically significant difference was found.*

**Conclusion:** *Computer-guided implant surgery with the CAD/CAM technique provides dentists with a good platform for preoperative planning, precise implant insertion, and ideal rehabilitation. The protocol of this three-dimensional laser scanning technique can provide precision comparable to that of double-scanning.*

**Key words:** *tooth implant, computer-aided design, rapid prototyping, implant surgical template, laser scanning*

Dental implant-supported rehabilitation presents stable fixation, ideal esthetic outcome, and better clinical predictability. It has thus become an important method in modern dentistry for restoring missing teeth. For some complicated cases with severe bone defect, abnormal jaw relation, or implantation sites adjacent to

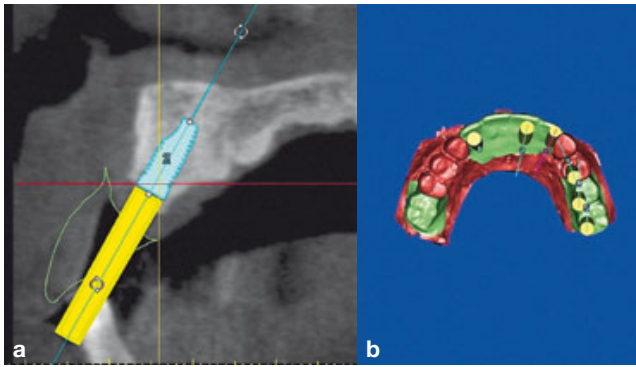
crucial anatomic structures, however, the conventional implantation technique based on dentists' experience usually results in compromised functional and esthetic outcome. Previously, two-dimensional radiography was used to observe patients' available bone quantity and anatomic structures, which cannot provide three-dimensional (3D) information<sup>1</sup>. In contrast to periapical films and panoramic images, computed tomography (CT) is able to show bone and soft tissue information in multiple cross-sectional views. CT data were once used to fabricate 3D jawbone models with a rapid prototyping technique, upon which dentists could make thermally pressed templates manually in the laboratory, but surgical precision was limited. Recently, CT-based 3D implant planning software has been developed and is increasingly being used. It can transfer CT data into a 3D digitised model. In the 3D virtual environment, den-

1 2nd Dental Center of Peking University, School and Hospital of Stomatology, Beijing, P.R. China.


2 3rd Dental Center of Peking University, School and Hospital of Stomatology, Beijing, P.R. China.

**Corresponding author:** Dr Wei Hua XU, 3rd Dental Center of Peking University School and Hospital Stomatology, 203 Golder Plaza, Huayuan east Road #10, Haidian District, Beijing100191 P.R. China. Tel: 86-10-82037073; E-mail: xwhmail@sohu.com

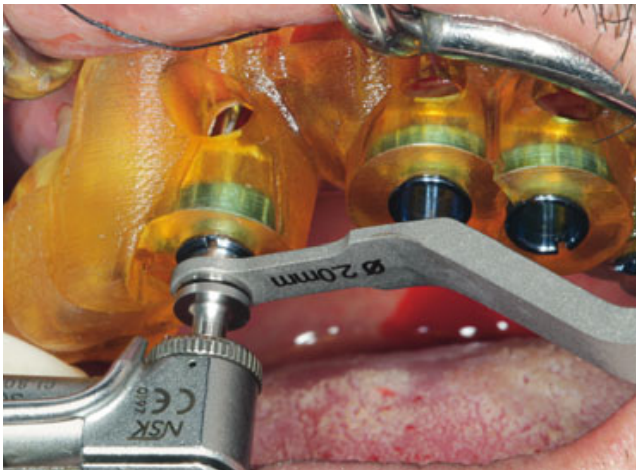The study was funded by the Chinese National Science and Technology Supporting Project (item no. 2012BAI07B06).



**Fig 1** Planned implant positions according to both proposed restoration and jawbone in Simplant. (a) Sagittal view. (b) Three-dimensional reconstructed view.



**Fig 3** Aligned image of preoperative planning (blue) and actual implant position (red).



**Fig 2** Implant placement was guided by the surgical template intraorally.

tists arrive at a diagnosis, plan implant positioning, and then fabricate computer-aided design/computer-aided manufacturing (CAD/CAM) templates directly by rapid prototyping<sup>2</sup>. Additionally, taking into account the prosthodontic-driven implant placement philosophy, “double scanning” for radiographic templates was always required preoperatively to help doctors predict the positions of the restorations. Nowadays, a 3D laser scanning technique is becoming an alternative method to double scanning. The objectives of this study were to use 3D implant planning software combined with a laser scanning technique to manufacture surgical templates and then to evaluate the clinical precision of this protocol.

### Materials and methods

A total of 11 partially edentulous patients with four men (35 to 72 years, mean 48 years) and seven women (31 to 62 years, mean 42.9 years), who went to the 2nd Dental Center of Peking University for implantation restoration, were included in this study. All patients satisfied the following conditions: no general disease, sufficient mouth opening to place both surgical templates and drills, enough bone quantity or fully healed bone grafts, full understanding of the study protocol, and signed informed consent. Cone beam computed tomography (CBCT) was applied to each patient using an E-WOO machine (DCTPRO-46; Vatech). The scanning conditions were 90 kV, 10 mA, and 24 S (metal artifacts reduction condition). The upper margin of the area to be scanned was the line connecting the bilateral tragus. The lower margin was the inferior margin of the mandibular bone. The Digital Imaging and Communications in Medicine (DICOM) format data from CBCT were then loaded into Simplant software (Materialise Dental) by which they were reconstructed into 3D digitized models. Intraoral impressions were taken and poured into diagnostic casts, upon which diagnostic wax was shaped to restore the missing teeth. 3D configurations of the restored diagnostic casts were subsequently recorded by a 3D laser scanner (3D Scanner Opticscan-DM; Shining 3D Tech), which then presented the information about each patient’s mucosa and dentition. 3D laser scanning data were also imported into Simplant software and were matched with the aforesaid CT data into a single coordinate system with the aid of an image spatial registration technique. In those fused views, all information about

the proposed position of the final prosthesis, available bone quantity of the patients, and vital anatomic structures (e.g. maxillary sinus, mandibular nerve, mental nerve, sublingual artery) could be observed and assessed by dentists simultaneously.

According to the edentulous space and bone condition, and under consideration of the prosthodontic-driven implant philosophy, the implantation planning was undertaken. During the planning the diameters, lengths, entry positions, and angles and depths of the implants needed for each patient were determined (Fig 1). The virtual planning was then transferred to create a surgical template by a rapid prototyping machine (Eden 260, Objet Geometries). Implant insertion surgeries were guided by the surgical templates (Fig 2).

Postoperatively, CBCT scans were obtained with the same settings as for the preoperative CT scanning, which were subsequently aligned with those derived from the preoperative planning in Simplant to estimate the difference between actual implant positions and initial virtual planning (Fig 3). Angular deviations and linear deviation for the implant apex and shoulder were measured, and mean values for each index were calculated.

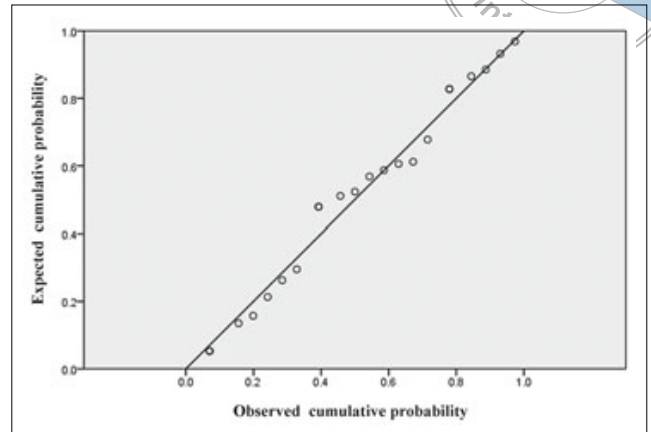
#### Statistical methods

SPSS software was used for the statistical analysis. Probability–probability (P-P) plots for deviation values were drawn, which demonstrated that all outcome values fit the normal distribution (Fig 4). The Levene test was used to show variance homogeneity. Analysis of variance (ANOVA) was consequently performed, in which the deviation values were analyzed as dependent variables, and the positions of implants (anterior region versus posterior region) and supporting pattern of templates (tooth-supported versus tooth/mucosa-supported) were the fixed factors. Significance level was defined as 0.05.

#### Results

All 11 patients underwent implant placement surgery under guidance of the CAD/CAM templates. A total of 31 implants were inserted. Tooth-supported templates were used in nine patients (13 implants) and tooth/mucosa-supported templates in two patients (18 implants). In all, 14 implants were inserted in the anterior region and 17 in the posterior region (Table 1).

Four patients (4/11) underwent simultaneous heterogeneous bone grafting during the implant insertion surgery because of bone perforations: two were intentionally based on the prosthodontic-driven planning, and two were performed because of the orientation



**Fig 4** Probability–probability (P–P) plot of deviation values at the implant shoulder, which demonstrated that all outcome values fit the normal distribution.

deviation found during bed preparation or implant insertion, which resulted in an implant position labial to the preplanning position. Two implants (2/31) were missed during the observation period. One occurred before loading (the patient underwent a maxillary sinus floor lift and had a poor oral hygiene condition and smoking habit). The other occurred after loading (patient had a history of bite reconstruction against a deep overbite, and immediate loading was adopted), so the survival rate was 93.5%. Eight patients had permanent rehabilitation, and all eight were satisfied with the functional and their esthetic outcome.

In all, 23 implants achieved image alignment of the actual positions and virtual planning (two implants missed, and three patients refused postoperative CT scanning in consideration of the extra radiation dose, which made the preoperative and postoperative image matching impossible). The mean linear deviation was 1.00 mm (range 0 to 2.16 mm) for the implant shoulder and 1.26 mm (range 0.51 to 2.86 mm) for the implant apex. The mean angular deviation was 4.74 degrees (range 0.37 to 10.28 degrees). Linear apex deviations at two implant sites (2/23) were > 2 mm, and angular deviation at one implant site (1/23) was > 10 degree degrees. All other implants (20/23) demonstrated linear deviations of < 2 mm and angular deviations < 10 degrees. The angular and linear deviation values in the posterior region and tooth/mucosa-supported templates were higher than in the anterior region and tooth-supported templates, respectively. The difference did not reach statistical significance (Table 2).



**Table 1** Number of implants and patients, by implantation sites and surgical templates

Implantation sites		Classification of surgical templates			
Anterior region	Posterior region	Tooth-supported		Tooth-mucosa-supported	
Number of implants	Number of implants	Number of patients	Number of implants	Number of patients	Number of implants
14	17	9	13	2	18

**Table 2** Linear and angular deviations of implants and their statistical results

Parameter	Linear deviations for implant shoulder (mm)			Linear deviations for implant apex (mm)			Angular deviation (degrees)		
	Mean	Range	<i>P</i>	Mean	Range	<i>P</i>	Mean	Range	<i>P</i>
Implantation site									
Anterior region	0.89	0–1.75	> 0.05	1.13	0.51–1.90	> 0.05	4.21	0.37–10.28	> 0.05
Posterior region	1.13	0–2.16		1.42	0.56–2.86		5.32	2.87–8.60	
Template type									
Tooth-supported	0.90	0–1.93	> 0.05	1.23	0.56–2.13	> 0.05	3.99	1.26–9.91	> 0.05
Tooth-mucosa-supported	1.06	0.32–2.16		1.29	0.51–2.86		5.14	0.37–10.28	

**Discussion**

As computer-aided implant placement with a surgical template has been developing gradually, we are paying close attention to its accuracy. CAD/CAM templates made by the Nobel Guide system were used in a study by Assche, with the results showing a mean deviation of  $1.1 \pm 0.7$  mm for the implant shoulder and  $2.0 \pm 0.7$  mm for its apex<sup>3</sup>. Petterson et al<sup>4</sup> performed implant insertion on cadavers using a CAD/CAM template and found linear deviations of 1.06 mm at the implant shoulder and 1.25 mm at the apex; the angular deviation was 2.64 degrees. Schneider et al demonstrated that using a computer-aid technique to manufacture surgical templates gave a deviation of 1.07 mm for the shoulder and 1.63 mm for apex<sup>5</sup>.

The differences between the positions derived from the planned and actual results may originate from each step, from CT data acquisition to implant insertion surgery. They might include a radiography error, solidification shrinkage of a stereolithographic template, intraoral malposition of the surgical templates, incorrect

operative practices of the implant surgeon, and so on. Such errors are cumulative and interactive.

In this study, although no statistically significant difference was found, implants in the posterior gap demonstrated greater deviation in both linear location and long-axes inclination. Vasak et al presented similar results<sup>6</sup>. This phenomenon may result from: (1) an error in CT imaging. Sforza et al reported that distortion of the CT image was significantly associated with the relation between tooth long axis and the rack of the CT scanner<sup>7</sup>. Accurate images require CT acquisitions perpendicular to the main axes of the teeth<sup>7</sup>. As the presence of the Curve of Spee and transverse curve of occlusion, the degree of inclination to the scanner rack is greater in the posterior region, which induces image distortion and unreliable evaluation of the bone contour. (2) There may be an error in bed preparation. Koop et al reported that this error can occur during the process of surgical drilling depending on the tolerance of the inserted drill and the guidance sleeve<sup>8</sup>. Such errors occur each time there is drilling with different diameters. The total drilling error is a cumulative result



of these errors. In the posterior gap, implants with wider diameters are usually inserted, which require more drilling episodes and consequently induce a larger deviation. (3) There may be an operative factor that is the responsibility of the surgeon. Vasak et al showed that the manual resistance of the surgeon's hand to a surgical template could induce iatrogenic error<sup>6</sup>. As the degree of opening of the mouth at the posterior teeth is less than in the front, it is possible that the drills in this area are forced to be deviating from the guidance orientation. In the current study, one implant in the front area demonstrated an angular deviation of > 10 degrees, which may have been due to the patient's heterogeneous bone density in the labial and palatal plate. In most anterior edentulous sites, bone absorption is more obvious in labial bone than in palatal bone, which tends to push the drill and implant to the side with less bone resistance. Another researcher thought that with a knife-shaped alveolar ridge or one with irregular depressions, drills are facilitated to have an eccentric shift<sup>9</sup>. Therefore, it is suggested that a ball drill be used to prepare the entry point before applying the pilot drill as it can guide subsequent drills in the correct direction.

In the current study, deviations were greater with the tooth/mucosa-supported template than with the tooth-supported template. Many dentists agree that in partially edentulous patients with a distal extension, mucosal resilience would decrease the intraoral stability of the template<sup>10</sup>. Ozan et al reported that there was a significant difference between the precision of the tooth-supported versus the mucosa-supported templates<sup>11</sup>. Widmann et al used three anchor pins to fix mucosa-supported templates to jaw bone and obtained a result similar to that achieved with tooth-supported templates<sup>12</sup>. Therefore, for patients with fully edentulous or partially edentulous with distal extension, one to three anchor pins and bite registrations are suggested to ensure the reposition and stability of surgical templates intraorally.

In 1995, Garber and Belser introduced a philosophy of "prosthodontic-driven implant placement", which means that the determination of implant position should not only take into consideration the presence of adequate bone but also the prosthetic outcome<sup>13</sup>. Conventionally, to obtain information about both the patient's jawbone and the proposed prosthesis, the "double-scan" procedure and radiographic templates are usually required, which prolongs the preoperative preparation time to some degree<sup>14</sup>. With the 3D laser scanning technique, introduced during the 1990s, a laser is shot onto the object's surface to scan and acquire 3D spatial cloud data of the sample, and then the data are converted into

a digital morphologic mold with high quality and high resolution<sup>15</sup>. In the present study, to acquire patients' surface morphology in regard to dentition, mucosa, and the proposed prosthesis, a 3D laser scanner was used to scan the surface of diagnostic casts, instead of using the double-scan technique, which can eliminate making a radiographic template and save some time. With the aid of the aforesaid protocol, this study presented precision comparable to that reported by other researchers<sup>10-12</sup>.

Computer-aided implantation is more expensive and time-consuming than the conventional technique. For example, in patients with a single tooth missing, the preoperative planning and manufacture of the surgical template would cost about \$320 US and prolonging the procedure to at least 4 days. In complicated cases, the expenditure further increases. Despite the cost, computer-aided implantation has superiority in protecting critical anatomic structures, reducing the risk of bone graft and postoperative complications. It can also provide better esthetic and functional outcome because of the "prosthodontic-driven implant placement" philosophy<sup>2</sup>. The accuracy-related results in this study were based on a relatively small sample. Hence, such further research with larger samples and additional clinical evaluation of long-term follow-up are desired to confirm the value and cost-benefit ratio of this strategy.

## Conclusion

Computer-guided implant surgery with a CAD/CAM technique provides dentists a good platform for preoperative planning, precise implant insertion, and ideal rehabilitation. Within the limitations of the current study, deviations in the posterior region and tooth/mucosa-supported template are higher. The protocol of the 3D laser scanning technique can provide a precision comparable to that achieved with double-scanning.

## Acknowledgments

The authors thank Yansheng LI, Jia CAO, and Haiquan ZHOU for their support. The authors declare no conflict of interest regarding the authorship and publication of this manuscript.

## References

1. BouSerhal C, Jacobs R, Quirynen M, et al. Imaging technique selection for the preoperative planning of oral implants: A review of the literature. *Clin Implant Dent Relat Res* 2002;4:156-172.
2. Widmann G, Bale RJ. Accuracy in computer-aided implant surgery - a review. *Int J Oral Maxillofac Implants* 2006;21:305-313.



3. Brief J, Edinger D, Hassfeld S, Eggers G. Accuracy of imaged-guided implantology. *Clin Oral Implants Res* 2005;16:495–501.
4. Pettersson A, Kero T, Gillot L, et al. Accuracy of CAD/CAM-guided surgical template implant surgery on human cadavers: Part I. *J Prosthet Dent* 2010;103:334–342.
5. Schneider D, Marquardt P, Zwahlen M, Jung RE. A systematic review on the accuracy and the clinical outcome of computer guided template-based implant dentistry. *Clin Oral Implants Res* 2009;20(Suppl 4):73–86.
6. Vasak C, Watzak G, Gahleitner A, et al. Computed tomography-based evaluation of template (Nobel Guide)-guided implant positions: a prospective radiological study. *Clin Oral Implants Res* 2011;22:1157–1163.
7. Sforza NM, Franchini F, Lamma A, et al. Accuracy of computerized tomography for the evaluation of mandibular sites prior to implant placement. *Int J Periodontics Restorative Dent* 2007;27:589–595.
8. Koop R, Vercruyssen M, Vermeulen K, et al. Tolerance within the sleeve inserts of different surgical guides for guided implant surgery. *Clin Oral Implants Res* 2013;24:630–634.
9. Wittwer G, Adeyemo WL, Schicho K, et al. Prospective randomized clinical comparison of 2 dental implant navigation systems. *Int J Oral Maxillofac Implants* 2007;22:785–790.
10. Di Giacomo GA, Cury PR, de Araujo NS, et al. Clinical application of stereolithographic surgical guides for implant placement: preliminary results. *J Periodontol* 2005;76:503–507.
11. Ozan O, Turkyilmaz I, Ersoy AE, et al. Clinical accuracy of 3 different types of computed tomography-derived stereolithographic surgical guides in implant placement. *J Oral Maxillofac Surg* 2009;67:394–401.
12. Widmann G, Zangerl A, Keiler M, et al. Flapless implant surgery in the edentulous jaw based on three fixed intraoral reference points and image-guided surgical templates: accuracy in human cadavers. *Clin Oral Implants Res* 2010;21:835–841.
13. Garber DA, Belser UC. Restoration-driven implant placement with restoration-generated site development. *Compend Contin Educ Dent* 1995;16:796, 798–802, 804.
14. Pesun IJ, Gardner FM. Fabrication of a guide for radiographic evaluation and surgical placement of implants. *J Prosthet Dent* 1995;73:548–552.
15. Ciocca L, Scotti R. CAD-CAM generated ear cast by means of a laser scanner and rapid prototyping machine. *J Prosthet Dent* 2004;92:591–595.