

Marie-Elise Jennes, Jürgen Mehrhof, Frank Peter Strietzel, Falk Schwendicke, Sascha Herbst, Benedikt Spies

Digital treatment planning and prosthetic rehabilitation of a patient suffering from generalized tooth wear

Introduction: Implant supported fixed reconstructions in patients with massive tooth wear often require an increase of the vertical dimension of occlusion (VDO) and can be considered complex in terms of material selection and the treatment procedures. In order to reduce clinical and laboratory efforts as well as the need of adjustments it is nowadays possible to implement several hard- and software tools to acquire and process three-dimensional data. Along with prosthetic backward planning, the final outcome might be improved with such technologies. However, according to the recent literature, there are no evidence-based treatment guidelines available for patients with massive tooth wear, impeding selection of long-term reliable materials and a specific treatment procedure.

Treatment Methods: A 68-year-old patient presented clinically insufficient prosthetic reconstructions in a partially edentulous arch in combination with massive tooth wear, that finally resulted in a deep bite. He aimed for aesthetically pleasing and functional reconstructions. Due to massive and generalized loss of dental hard tissues, adequate treatment was only possible by increasing the VDO, which included provisionalization for 6 months. Before bite registration, the position of the maxilla was three-dimensionally determined. Furthermore, a scan of the face as well as an intraoral scan were performed. Based on the acquired data, a prosthetic-backward planning was performed and the ascertained vertical height was transferred to a noninvasive splint in the upper jaw as well as to temporary eggshell restorations in the lower jaw. During 6 months of provisionalization, guided implant surgery in the region of former teeth 23 and 24 was performed. After the provisional phase, maxillary teeth were prepared and direct temporary restorations were inserted. Subsequently, impressions were taken using an intraoral scanner and a polyether material. Finally, monolithic ZrO₂ crowns and bridges were adhesively luted to the abutment teeth. After the treatment, a Michigan splint was designed and milled using CAD/CAM (computer aided design/ computer aided manufacturing).

Charité Center for Dental, Oral and Maxillary Medicine, Department of Prosthodontics, Geriatric Dentistry and Craniomandibular Disorders: Marie-Elise Jennes
Medical Center – University of Freiburg, Center for Dental Medicine, Department of Prosthetic Dentistry, Faculty of Medicine, University of Freiburg: Prof. Dr. Benedikt Spies
Zahntechnik Mehrhof GmbH, Reuchlinstr. 11, 10553 Berlin-Tiergarten: Jürgen Mehrhof, ZTM
Charité – Medical University Berlin, Department of Oral Medicine, Dental Radiology and Surgery: Dr. Dr. Frank Peter Strietzel
Charité – Medical University Berlin, Department of Dental Conservation and Preventive Dentistry: Prof. Dr. Falk Schwendicke; Dr. Sascha Herbst
Translation from German: Yasmin Schmidt-Park
Citation: Jennes ME, Mehrhof J, Strietzel FP, Schwendicke F, Herbst S, Spies B: Digital treatment planning and prosthetic rehabilitation of a patient suffering from generalized tooth wear. *Dtsch Zahnärztl Z Int* 2020; 2: 73–81
Peer-reviewed article: submitted: 19.09.2019, revised version accepted: 13.01.2020
DOI.org/10.3238/dzz-int.2020.0073-0081

Results: By increasing the VDO in the provisional phase, it was possible to achieve an adaptation of the stomatognathic system before incorporating the final reconstructions. The digital workflow contributed to increasing time efficacy.

Conclusion: The presented treatment describes a predictable and efficient method to rehabilitate patients with massive tooth wear.

Keywords: therapy planning; digital workflow; 1. backward planning; bite elevation; CAD/CAM

1. Introduction

Fixed, implant-prosthetic rehabilitation of patients with massive tooth wear require vertical readjustment in multiple cases and often go along with a non-invasive provisional testing phase as well as higher planning and time expense. In order to reduce the clinical and laboratory expense as well as the necessity of intraoral fittings to a minimum, a variety of hard- and software are available for data acquisition, processing and therapy planning. Examples of this are the intra- and extraoral surface scanners, digital volume tomographies as well as appropriate software-solutions to link the generated data and computer aided designs (Computer-aided design, CAD) of the dentures. By creating a three-dimensional face scan, the laboratory software can show the physiognomy of the face. This process enables a prosthetically oriented “backward planning” before implantation and allows an increased planning security in regards to functionality and aesthetic. Due to the lack of evidence-based treatment guidelines, the correct selection of the material as well as the planning of treatment processes is impeded [1, 17].

2. Case report

2.1 Initial diagnosis

A 68-year old patient presented himself in the Department of Prosthodontics, Geriatric Dentistry and Craniomandibular Disorders of the Charité Center for Dental, Oral and Maxillary Medicine with an insufficiently restored dentition, generalized tooth wear, a resulting deep bite in the anterior region and the desire for aesthetically and functionally

pleasing restorations. The general medical history did not show pathological findings. After extensive clinical examination several edentulous spaces and insufficient prosthetic reconstructions in combination with a multifactorial (bruxism, attrition, erosions) loss of vertical dimension that resulted in a deep bite, could be reported. The teeth 18, 15, 22, 23, 24, 26, 28, 38, 36, 46 and 48 were missing. A slight generalized bone loss of $< \frac{1}{3}$ of the root length in the region of the upper posterior teeth and of $\frac{1}{3}$ to $\frac{2}{3}$ in the upper front could be determined periodontally (Fig. 1). The removable partial denture that replaced the teeth 22, 23, 24 and 26 has been worn in the upper jaw since 2007 and didn't show retention due to the generalized tooth wear. The gaps in region 36 and 46 were not restored prosthetically. Abrasion facets were diagnosed on all teeth (Fig. 2a, 2b, 3). Especially the teeth 25 and 47 showed a high degree of attrition due to extensive tooth wear. A downsized lower third of the face was shown from an extraoral perspective. A functional screening on painful CMD was performed based on the groundwork of CMD summary report after Jakstat and Ahlers [2]. The probability for the development of a CMD was categorized as unlikely in this context. The derived diagnoses from the mentioned findings are listed in Table 1. The categorization of tooth wear was based on the modified tooth wear index after Donachie and Walls [9]. Because adequate prosthetic rehabilitation only seemed reasonable in combination with a bite elevation, a provisional phase of 6 months was implemented to test out the aspired bite elevation.

2.2 Integration of bite registration and maxillo-mandibular relationship in digital workflow

The necessary bite elevation was determined with regard to the planned prosthetics in the lab and the speaking distance was clinically checked. Prior to the bite registration the patient was asked to wear a hydrostatic relaxation splint for 30 minutes (Aqualizer, Dentatrade International, Cologne, Germany) (Fig. 4). This supposedly reduced the risk of occupying a potentially neuromuscular forced bite. After removing the relaxation splint, a laboratory-fabricated registration aid composed of light-curing plastic sheets (C-Plast, Candulor, Rielasingen-Worblingen, Germany) was used to register the prospectively aspired occlusion position (Fig. 5). First, a relining of the base with Bis-GMA (Luxatemp, DMG chemical pharmaceutical plant, Hamburg, Germany) occurred in the lower jaw. The impressions of the teeth were shortened in the plastic state of the relining material down to the impressions of the cusp tip and incisal edges. After fixing the lower jaw, the step-by-step relining of the upper jaw took place: First, the incisal edges of the middle upper incisors were relined and the impressions were shortened to a minimum. This registration was tested multiple times on reproducibility of the bite in the following. Afterwards, the posterior upper teeth were relined and the definitive bite was fixed.

The PlaneSystem (Zirkonzahn GmbH, Pustertal, Italy) was used to gather the position of the upper jaw in relation to the so-called natural head position (NHP). It consists of the PlaneFinder, the virtual and real

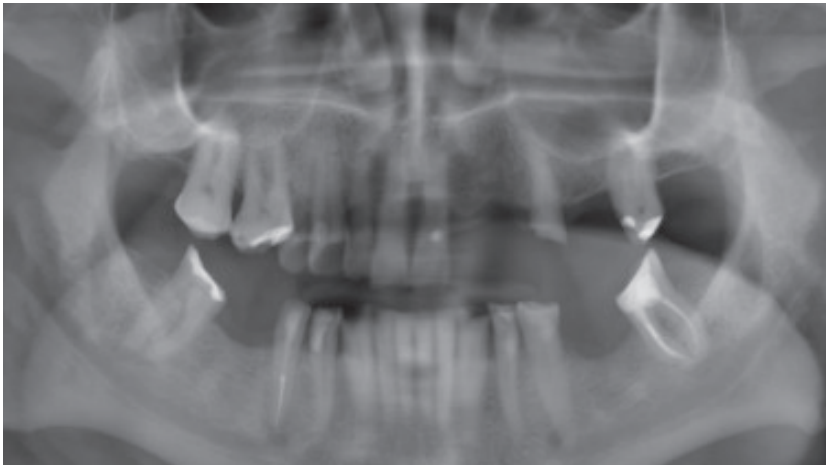


Figure 1 Panoramic tomographic image of the initial situation. Radiologically, an apical radiolucency is visible on tooth 47.

articulator PS1, the PlanePositioner as well as the PlaneSystem software. This allows the acquisition of individual patient differences of the natural head position as well as the angle of inclination of the occlusal level of

the registered position (Fig. 6). The models can be positioned above the PlanePositioner in the articulator PS1 using the determined angle, which simulates the individual patient's rotation-, sliding- and closing move-

ments of the jaw. In order to enable the allocation of the acquired data and coordination in three-dimensional space, the position of the articulated models was gathered in a PS1 articulator using the stripe-light scanner S600 ARTI and was integrated using the PlaneSystem software (Zirkonzahn.Modellier, Zirkonzahn GmbH, Pustertal, Italy) and transferred into a virtual integrated articulator in the software. Collecting the physiognomy of the face took place using an extraoral scanner (Face Hunter, Zirkonzahn), which enabled the axis-related positioning of the face in a virtual articulator by gathering a 3D face scan (Fig. 7).

2.3 Creation of a digital wax-up and intraoral fitting in form of a mock-up

After acquiring the three-dimensional relation of both jaws and an axis-related positioning of the face scan, a set-up of both jaws was created in a

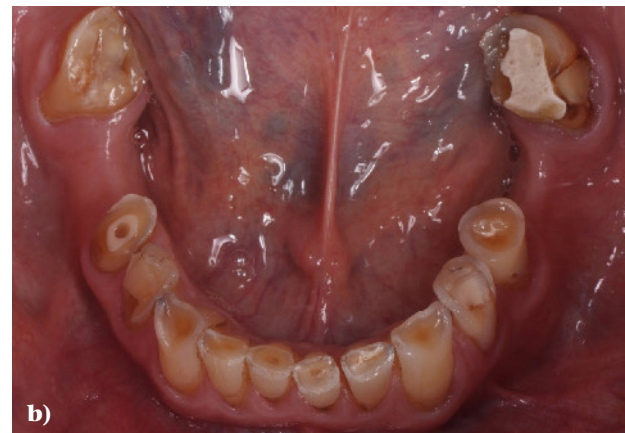
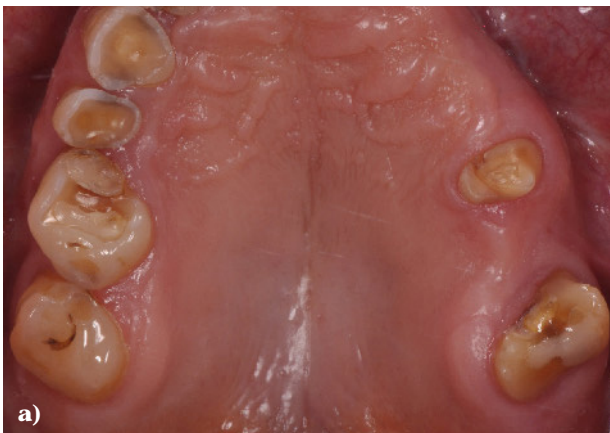
Figure 2a and 2b The intraoral findings resulted in partially edentulous adult arches with insufficient prosthetic and preservative restorations. The massive tooth wear can especially be seen on the occlusal surfaces of the molars, as well as the palatal surfaces of the upper incisors and the incisal edges of the lower incisors.

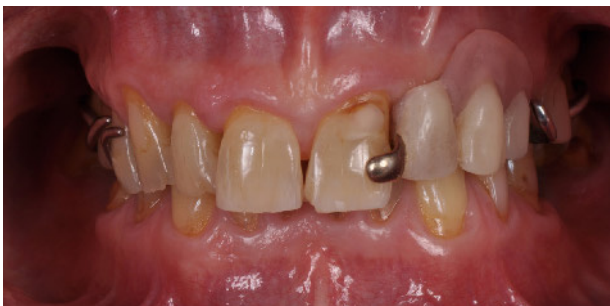

Figure 3 Due to tooth wear, a significant reduction of vertical dimension occurred, which clinically resulted in the form of a deep bite.

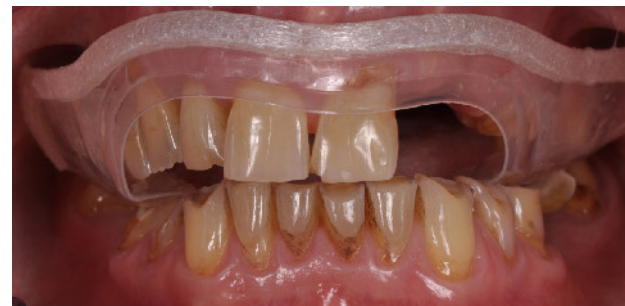

Figure 4 Prior to the bite registration the patient was asked to wear a hydrostatic relaxation splint for 30 minutes in order to reduce the risk of occupying a potentially neuromuscular forced bite.

computer-aided design (CAD) (Zirkonzahn.Modellier, Zirkonzahn) and printed (Form 2, Formlabs, Somerville, USA) (Fig. 8). The printed models enabled the creation of a transfer key made out of transparent silicone (Hardglass, Ichem, Palosco, Italy), and evaluated the created set-up in form of a mock up regarding phonetics and aesthetics (Fig. 9). After testing the mock up, the definitive prosthetic restoration was planned as follows:

- monolithic ZrO₂ crowns in region 17, 16, 15, 13, 12, 11
- monolithic ZrO₂ bridges in region 24–26, 34–37, 44–47
- screwed, implant-supported monolithic ZrO₂ extension in region 22–24

2.4 Testing of the aspired occlusion position and bite elevation

As things developed, the digital set-up served as a template to produce a polycarbonate splint (Multistratum, Zirkonzahn) according to Edelhoff et al. [10] in the upper jaw as well as a template for temporary eggshell restorations made out of polymethylmethacrylate (Premiotemp Multi PMMA, primotec, Bad Homburg, Germany) in the lower jaw (Fig. 10a, 10b). After selective preparation of the teeth 37, 35, 34, 44, 45 and 47, the insertion of temporary eggshell restorations, as well as the dental colored polycarbonate splints, the new bite elevation was tested for 6 months prior to definitive restoration. During this, the bite in the anterior region was elevated by a total of 5 mm.

2.5 Preservative pretreatment

During the temporary phase of the bite elevation the lower incisors were reshaped based on the digital wax-up using Ceram X Duo (Dentsply Sirona, York, USA) (Fig. 11). The teeth 25 and 47 were treated with root canal procedures for prosthetic reasons and fiberglass pins during the course of treatment.

2.6 Digital implantation design

Before implantation, a three-dimensional planning of the aspired implant position was completed and for

| Diagnosis | tooth/region/value |
|--|-----------------------------------|
| modified tooth wear index (TWI) category 1 | 17 |
| modified tooth wear index (TWI) category 2 | 16, 11, 21, 34–43 |
| modified tooth wear index (TWI) category 3 | 14–12, 25, 27, 37, 35, 44, 45, 47 |
| insufficient fillings | 16, 27, 37, 34, 44, 45 |
| insufficient prosthetic treatment | 22, 23, 24, 26 |
| periodontal screening index (PSI) | 1, 1, 1, 1, 1, 1 |
| apical periodontitis | 47 |
| deep bite | 11, 21, 31, 32, 41, 42 |

Table 1 Listing of the diagnoses derived from the above findings.

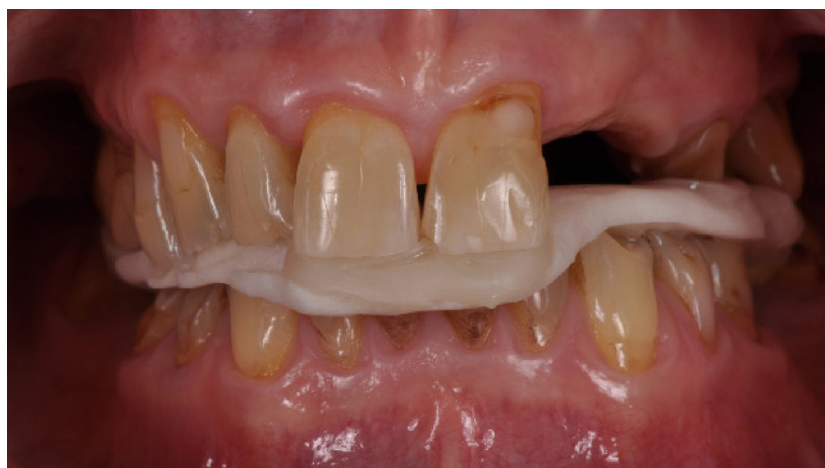

Figure 5 The fixation of the bite occurred through relining of a laboratory registration aid.

this a DVT was necessary (Veraviewepocs 3D, J. Morita, Tokyo, Japan). In terms of a prosthetic oriented backward planning the DICOM data set of the DVT was overlapped with the STL data set of the upper jaw diagnostic model with the help of a planning software (SMOP, Swissmeda, Baar, Switzerland). Afterwards, the STL data set of the antagonistic jaw and the created set-up were read in. Because these data sets were exported in the same coordinate systems, no new alignment was necessary. In the end the optimal implant positions in region 23 and 24 were determined (Fig. 12ac). Based on the SMOP-plan-

ning, a dentally-supported implantation splint was printed and guiding sleeves were attached. These were tested on the patient to ensure a wobble-free fit before implantation.

2.7 Implantation

The implantation was performed with local anesthesia and mid-crestal incision from region 21 to region 25 as well as the preparation of a muco-periosteal flap. There was no vertical relieving incision. After inserting 2 implants (Camlog Screw Line, Camlog, Wimsheim, Germany) with a diameter of 3,8 mm and 11 mm in length, a saliva-proof wound closure

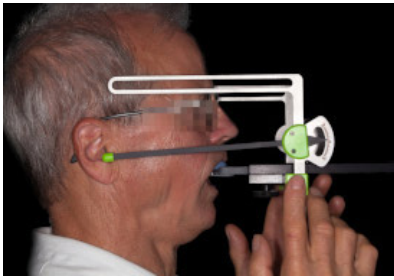


Figure 6 Acquisition of the position of the upper jaw in relation to the Natural Head Position (NHP) occurred with the PlaneSystem.



Figure 7 An extraoral scan was performed in order to determine the face physiognomy.

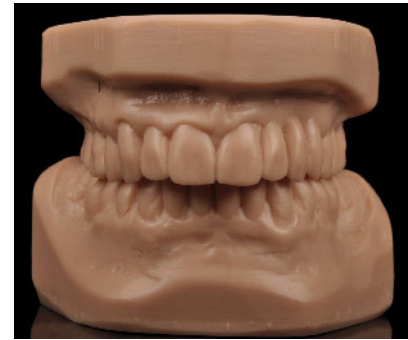

Figure 8 After determining the three-dimensional relation of both jaws as well as the axis-related positioning of the face scan, a set-up of both jaws were digitally designed and printed.

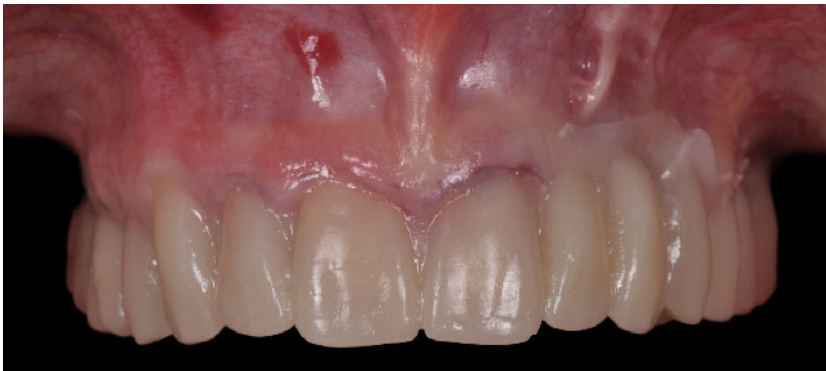

Figure 9 After production of a transfer key, the digitally created set-up was transferred intraorally as a mock up.

with a horizontal mattress suture as well as lateral sutures were performed (Fig. 13). After a healing period of 3 months the implants were exposed surgically. For this, another mid-crest incision was chosen and a mucoperiosteal flap was prepared. The cover screws were replaced by 2 gingiva formers (height 4 mm) and the mucosa was adapted to the gingiva formers using single button sutures.

2.8 Preparation, direct temporary restorations of the upper jaw and impressions

The preparation occurred selectively based on the overlapping data of wax-up and initial model. With digital measurement it was possible to determine the difference between wax-up and diagnostic casts. Many teeth already showed a difference of 0,8 mm due to loss of hard tooth structure compared to the wax-up, causing that the minimum layer

thickness of zirconium dioxide could be kept without any or only minimal preparation (Fig. 14, 15a, 15b). It should be noted that a preparation reserve for the restorations should be taken into account at all times. The impressions of the preparation were done digitally and conventionally using individual, open impression trays and a polyether (3M Impregum Penta, 3M-Germany, Neuss, Germany). In conventional impressions, the double cord technique was used. In order to analyze the deviations between digital data of the intraoral scan and the conventional model, the conventional model was additionally scanned (Scanner S600 ARTI, Zirkonzahn) and overlapped with the digital set of data in the CAD/CAM software Zirkonzahn.Modellier. After preparation and taking impressions direct temporary restorations were manufactured (Fig. 16). The bite registration was performed in 2 steps to

maintain the vertical alignment. For this, the provisions of the 1. and 4. quadrant were removed and the bite was scanned in centric occlusion contralaterally, or rather, fixed with silicone (Futar D, Kettenbach, Eschenburg, Germany). The same procedure occurred in the 2. and 3. quadrant.

2.9 Bite registration control

Based on the bite registration, a precise registration was manufactured in the laboratory, which was used in a follow-up appointment for bite check occlusion control analogue to the bite registration in section 2.2. In order to correct the imprecisions while taking impression of the implant positions, the impression posts were interlocked with Pattern Resin LS (GC, Tokyo, Japan) after model creation. The interlocking was separated with a thin saw cut, which was sealed intraorally with Pattern Resin LS after screwing the impression posts.

2.10 Completing and production of a Michigan splint

The CAD/CAM manufactured crowns and bridges were milled from monolithic zirconium dioxide (Katana Zirconia STML, Kuraray, Chiyoda, Japan) and sintered in the lab. Before integration, the restorations were sandblasted with aluminium oxide powder (1 bar, 50 µm grain size) and the teeth were cleaned with rotating brushes and polishing paste [12]. The implant bridge in region 22–24 was screwed intraorally with 20 Ncm and

the screw canal was sealed with teflon tape and a low viscosity composite. The crown and bridge constructions were bonded adhesively with Panavia F2.0 (Kuraray, Chiyoda, Japan) (Fig. 17a–e). In order to obtain a permanently stable prosthetic result as well as the modified functional model, the upper and lower arch were scanned (Trios, 3Shape, Copenhagen, Denmark) again after integration and a Michigan splint for nightly use was designed digitally and then milled (Fig. 18a, 18b).

3. Discussion

In general, 3 reasons can be listed for a non-carious loss in tooth substance. These include erosions due to extrinsic (e.g. with increased consumption of acidic drinks or foods) and intrinsic processes (e.g. bulimia or reflux). Another cause of pathological loss of teeth substance is abrasions and attritions. Contrary to abrasions, where tooth wear occurs based on external factors, attritions where loss occurs by parafunctions in the stomatognathic system and tooth wear patterns result on teeth due to increased antagonistic tooth-to-tooth contact [8]. In that, bruxism is a frequent cause of attrition. Bruxism is defined as the parafunctional abrasion of antagonistic teeth in the form of an “oral habit” by unwilling rhythmic or spastic non-functional abrasion or pressing, whereas these movements are not in connection with the comminution of food [11]. The loss of vertical dimension can therefore lead to a compensatory growth of the alveolar process or to an increased interocclusal distance, which can then have a

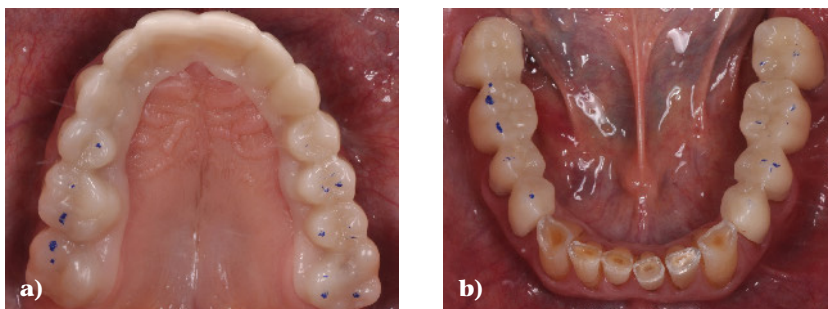


Figure 10a and 10b The bite elevation occurred in the temporary phase using a non-invasive splint in the upper arch and temporary eggshell restorations in the lower jaw.

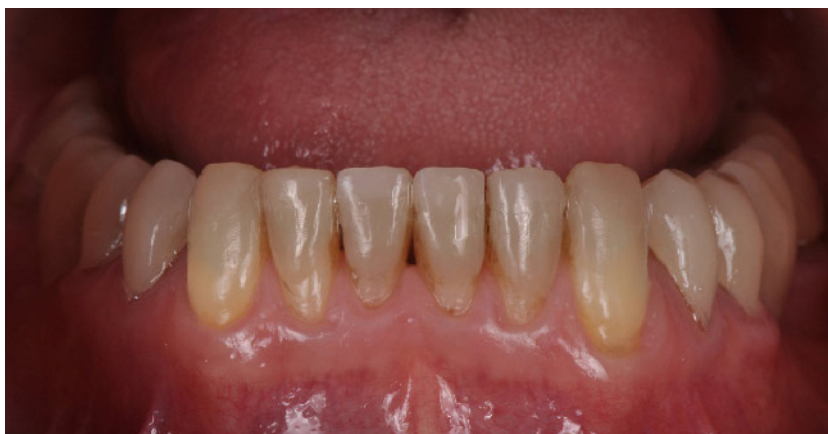

Figure 11 During the temporary phase of bite elevation the tooth wear in the lower arch incisor region was built up directly using composite and made possible by the vertical space gained.

massive impact on the masticatory function, aesthetics and the occlusal levels [16]. According to the S3-guidelines on bruxism, definitive occlusal measures can be considered for functional-aesthetic or prosthetic reasons so that the consequences of such tooth wear can be compensated. The use of implants in patients with bruxism for prosthetic rehabilitation is

controversially discussed in literature. Even though latest meta analyses [6, 7, 13, 20] showed an increased risk of implant loss, bruxism is not seen as a contraindication for implantation to date. The increased vertical burden of implants in this case is seen as cause for peri-implant bone loss and implant fractures, which is why bruxism is nonetheless a contraindication for

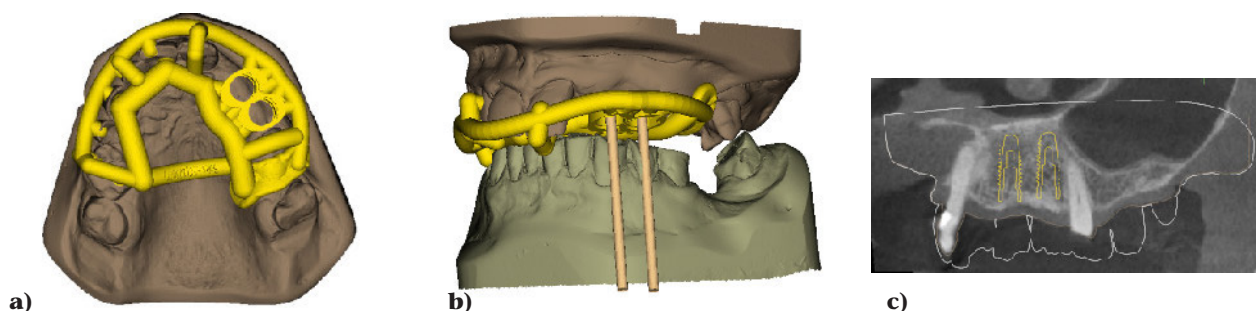


Figure 12a–c The planning of the ideal implant positions occurred by prosthetically oriented backward planning. With the software SMOP the scanned diagnostic model, the wax-up, as well as the DVT were overlapped to determine an ideal implant position. Based on the plan, the implantation splint, portrayed yellow in the software, was printed and guides were stuck in.

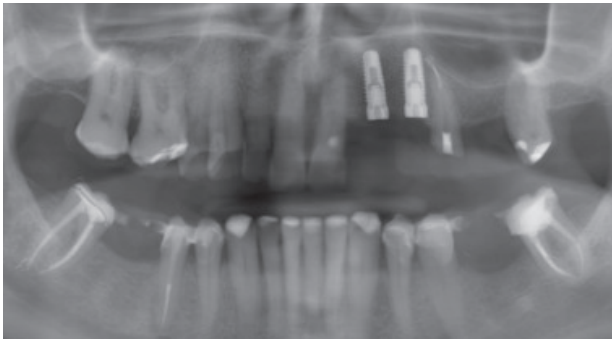


Figure 13 The postoperative radiological control of the implant position occurred with a panoramic tomographic image.

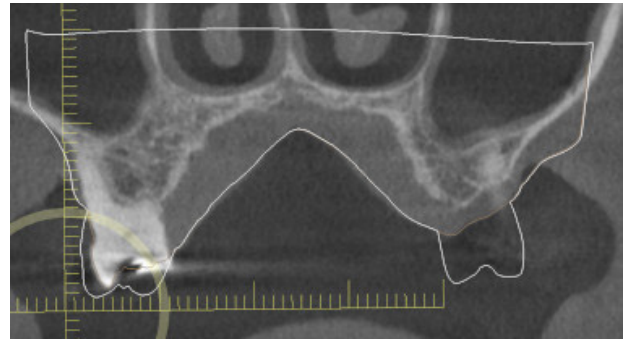


Figure 14 An additional control on the necessary reduction of tooth structure during preparation was done by the digital measurement of the wax-up and diagnostic casts in the DVT and the determination of the difference.

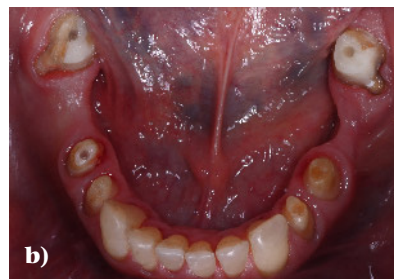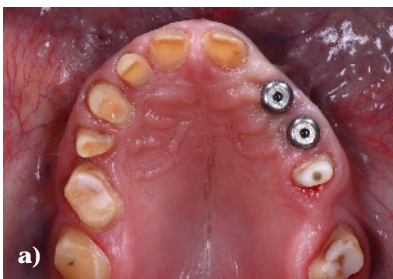


Figure 15a and 15b A chamfer preparation with a minimum reduction of 0.8 mm took place for the restorations with monolithic zirconium dioxide crowns and bridges.

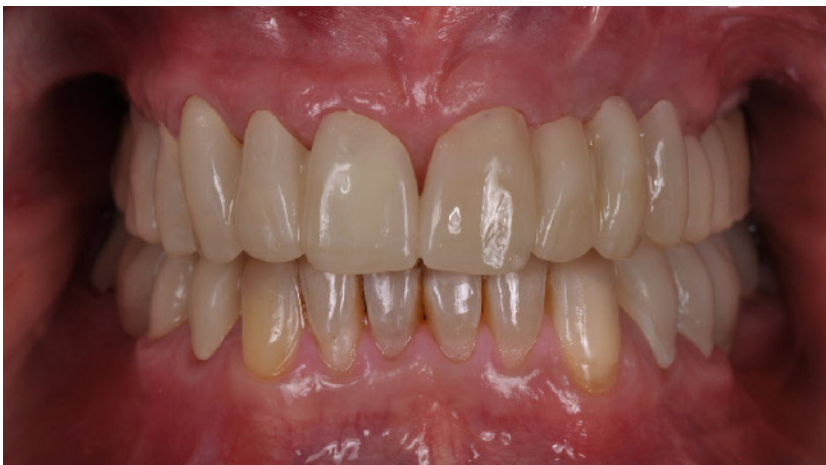

Figure 16 The direct temporaries were created based on the digitally created wax-ups and transferred intraorally with a laboratory-fabricated molded part.

implants for many dentists [14]. A correlation between an increased implant loss and bruxism could not be found in other systematic reviews to date [5, 14, 15].

A digital planning of the implant positions was made for the implantation mentioned above in region 23 and 24. The base of digital implant

planning was formed with the possibility of overlap of three-dimensional data from radiological imaging examination (DICOM data), the surface data of diagnostic casts and the data of the digital set-ups (STL format) [18]. Within the implantation planning the overlap of the individual data sets occurred using the software

SMOP (Swissmeda, Baar, Switzerland). The digital set-up created a first orientation of optimal anatomic and aesthetic positioning of implants. Afterwards, the definitive determination of the implants' positions were transferred in vivo using implantation splints. Regarding the precision of the navigated implantations, Vermeulen [19] could determine statistical significant differences compared to precision of free-hand implantations.

The material selection of the planned prosthetics presents the treating dentist with a challenge. In literature, the question on the lasting probability of e.g. all-ceramic restorations in patients with bruxism could not be cleared up conclusively, because patients with bruxism are excluded in a multitude of studies. The question if monolithic zirconium oxide is an appropriate alternative in patients with bruxism cannot be answered at this point in time. According to the patient in the case report, the direct provisions made out of Bis-GMA already led to a significant reduction of the muscular activity due to a new adjustment of the bite elevation. This only resulted in 2 fractured provisions during the provisional phase of the bite elevation. A significant reduction of muscular activity by elevating the vertical dimension was also found electromyographically by Carlsson et al. [4].

Other than the careful selection of the materials, the treatment process should also be planned systematically. However, even though extensive prosthetic cases in com-

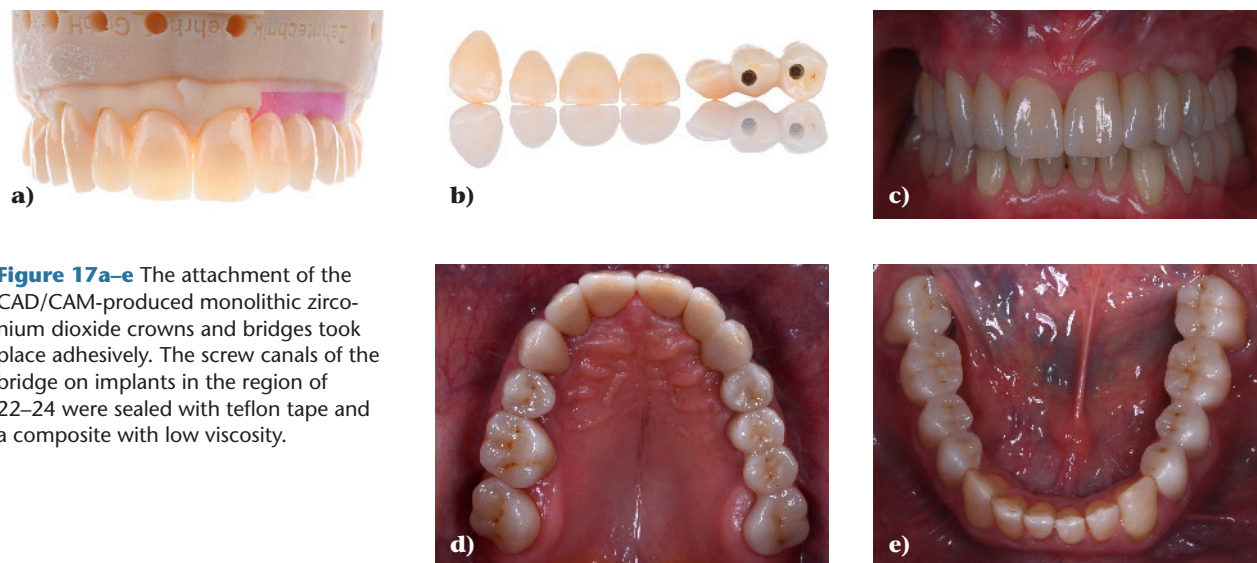


Figure 17a–e The attachment of the CAD/CAM-produced monolithic zirconium dioxide crowns and bridges took place adhesively. The screw canals of the bridge on implants in the region of 22–24 were sealed with teflon tape and a composite with low viscosity.

combination with a bite elevation are subject of a complex treatment plan, there are no existing evidence-based guidelines which are helpful in choosing the right treatment approach. In the S3-guidelines “diagnosis and treatment of bruxism”, recommendations in “management of bruxism through definitive dental treatments” are expressed [17]. Abduo [1] was able to formulate some treatment recommendations and specifies in this context, that for adaptation to the new vertical dimension before integration of the definitive prosthetic restorations, a provisional phase of at least 1 month should be adhered to. The bite elevation was supposed to occur on all remaining teeth in the upper and lower jaw. Fixed temporary dental restorations led to a more rapid adaptation and was experienced as a more pleasant wearing comfort in comparison to removable splints.

Upon completion of the outlined therapy, a digital Michigan splint was designed and then milled. The field of indication of a Michigan splint is not only to protect teeth from further attrition, but also in the modification of a functional model of the masticatory system as well as stabilization of the mandibular joints. In preparation of the Michigan splint the concept of “freedom in centric” was used, where a freedom of mandibular joint movement of 0.5–1.0 mm was aspired before the posterior teeth discluded [3].

4. Conclusion

The lack of evidence-based guidelines makes the choosing of the appropriate restoration materials and the therapy approach rather difficult, which shows the necessity for further studies in connection to bruxism and material behavior in crowns, bridges and implant materials. A significant simplification of the complex treatment de-

mand can be achieved by using digital technologies. A three-dimensional acquisition of intra- and extraoral surfaces enables a precise, functional and aesthetic wax-up in the present treatment, which was maintained in the sense of a “backward planning” until integration of the final restorations and therefore made repeated fittings obsolete. Because prosthetic planning as well as treatment process in patients with generalized tooth wear and a resulting loss in vertical dimension is based only on expert opinion to date, an extensive after-care program should be ensured that sustainably guarantees the adaptation of the stomatognathic system to the new bite elevation.

Conflicts of interest:

The co-author (PD Dr. F. P. Strietzel) received third-party funding and

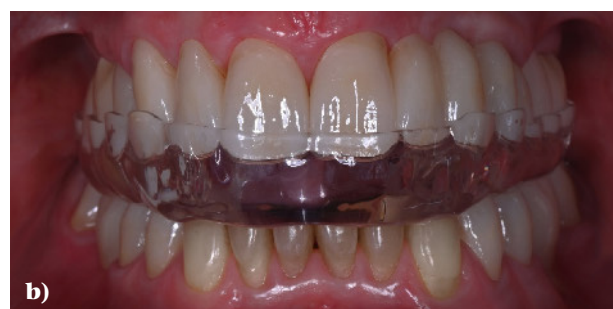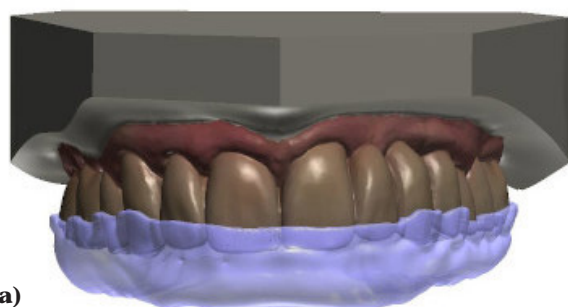


Figure 18a and 18b A Michigan splint was digitally designed and milled after integrating the restoration.

travel expenses from the Camlog Foundation (now Oral Reconstruction Foundation) in the context of research projects. In the context of student education, third-party funds for hands-on courses were raised by Camlog.

The other authors declare that there is no conflict of interest as defined by the guidelines of the International Committee of Medical Journal Editors.

References

1. Abduo J, Lyons K: Clinical considerations for increasing occlusal vertical dimension: a review. *Aust Dent J* 2012; 57: 2–10
2. Ahlers MO, Jakstat HA: Identifikationsfunktion gestörter Patienten. *Thieme Up2date* 2008; 2: 143–155
3. Badel T, Simonić-Kocijan S, Lajnert V, Dulčić N, Zadavec D: Michigan splint and treatment of temporomandibular joint. *Medicina fluminesis* 2013; 49: 112–120
4. Carlsson GE, Ingervall B, Kocak G: Effect of increasing vertical dimension on the masticatory system in subjects with natural teeth. *J Prosthet Dent* 1979; 41: 284–289
5. Chrcanovic BR, Albrektsson T, Wennerberg A: Bruxism and dental implants: a meta-analysis. *Implant Dent* 2015; 24: 505–516
6. Chrcanovic BR, Kisch J, Albrektsson T, Wennerberg A: Bruxism and dental implant failures: a multilevel mixed effects parametric survival analysis approach. *J Oral Rehabil* 2016; 43: 813–823
7. Chrcanovic BR, Kisch J, Albrektsson T, Wennerberg A: Bruxism and dental implant treatment complications: a retrospective comparative study of 98 bruxer patients and a matched group. *Clin Oral Implants Res* 2017; 28: e1–e9
8. Davies SJ, Gray RJM, Qualtrough AJE: Management of tooth surface loss. *Br Dent J* 2002; 192: 11–6, 19–23
9. Donachie MA, Walls AWG: Assessment of tooth wear in an ageing population. *Journal of Dentistry* 1995; 23: 157–164
10. Edelhoff D, Schweiger J, Prandtner O, Trimpl J, Stimmelmayer M, Güth J-F: CAD/CAM splints for the functional and esthetic evaluation of newly defined occlusal dimensions. *Quintessence Int* 2017; 48: 181–191
11. Ferro KJ, Morgano SM, Driscoll CF: The glossary of prosthodontic terms. Ninth edition. *J Prosthet Dent* 2017; 117: e1–e105
12. Kern M, Beuer F, Frankenberger R et al: Vollkeramik auf einen Blick. Leitfaden zur Indikation, Werkstoffauswahl, Vorbereitung und Eingliederung von vollkeramischen Restaurationen. *AG Keramik, Ettlingen* 2015
13. Kullar AS, Miller CS: Are there contraindications for placing dental implants? *Dent Clin North Am* 2019; 63: 345–362
14. Lobbezoo F, Brouwers, J E I G, Cune MS, Naeije M: Dental implants in patients with bruxing habits. *J Oral Rehabil* 2006; 33: 152–159
15. Manfredini D, Poggio CE, Lobbezoo F: Is bruxism a risk factor for dental implants? A systematic review of the literature. *Clin Implant Dent Relat Res* 2014; 16: 460–469
16. Muts E-J, van Pelt H, Edelhoff D, Krejci I, Cune M: Tooth wear: a systematic review of treatment options. *J Prosthet Dent* 2014; 112: 752–759
17. Peroz I, Bernhardt O, Kares H et al.: S3-Leitlinie „Diagnostik und Behandlung von Bruxismus“, 2019
18. Schubert O: Digitale Implantationsplanung und navigierte Implantation. Hype oder sinnvolle Zukunftstechnologie? *Der Freie Zahnarzt* 2018; 62: 76–84
19. Vermeulen J: The accuracy of implant placement by experienced surgeons: guided vs freehand approach in a simulated plastic model. *Int J Oral Maxillofac Implants* 2017; 32: 617–624
20. Zhou Y, Gao J, Le Luo, Wang Y: Does bruxism contribute to dental implant failure? A systematic review and meta-analysis. *Clin Implant Dent Relat Res* 2016; 18: 410–420



(Photo: M.-E. Jennes)

MARIE-ELISE JENNES
Charité Center for Dental, Oral and Maxillary Medicine, Department of Prosthodontics, Geriatric Dentistry and Craniomandibular Disorders
Campus Benjamin Franklin – CC3
Assmannshausen Str. 4–6
14197 Berlin
marie-elise.jennes@charite.de



(Photo: B. Spies)

PROF. DR. BENEDIKT SPIES
Medical Center – University of Freiburg, Center for Dental Medicine, Department of Prosthetic Dentistry, Faculty of Medicine, University of Freiburg,
Hugstetter Str. 55,
79106 Freiburg, Germany
benedikt.spies@uniklinik-freiburg.de