

Orthodontic and Orthognathic Treatment Combined with Surgically Assisted Rapid Maxillary Expansion in an Adult Patient with a Hyperdivergent Skeletal Pattern

Yi Neng HAN^{1,2}, Hao LIU^{1,2}, Zi Li LI^{2,3}, Yi Ping HUANG^{1,2}, Wei Ran LI^{1,2}

In this case study, we report the successful treatment of a 35-year-old woman with a hyperdivergent skeletal pattern, open bite and severe transverse deficiency, exhibiting a skeletal Class III malocclusion. The treatment plan included 3D correction of these issues with surgically assisted rapid maxillary expansion (SARME) to solve the transverse deficiency, presurgical orthodontic treatment including aligning and levelling of the teeth in both arches, LeFort I osteotomy and bilateral sagittal split ramus osteotomy, and postsurgical correction of malocclusion. Orthodontic treatment was performed with labial brackets, and the patient achieved satisfactory occlusion and a significantly improved facial profile. Retention at the 1-year follow-up showed stable occlusion and arch forms with a harmonious facial profile.

Key words: hyperdivergent skeletal pattern, open bite, orthodontic-surgical treatment, surgically assisted rapid maxillary expansion, transverse deficiency

Chin J Dent Res 2022;25(4):301–310; doi: 10.3290/j.cjdr.b3628219

Hyperdivergent skeletal patterns are often accompanied by anterior open bite, which is considered one of the most difficult orthodontic problems to correct¹. Patients with hyperdivergent growth patterns may also have severe maxillary transverse and sagittal deficiencies. Lateral cephalometric radiographs of such patients often show a steep mandibular plane, obtuse gonial angle and increased height of the lower third of the face². To cor-

rect severe skeletal deformities and establish a stable occlusion in adults, orthognathic surgery combined with orthodontic treatment is often needed to achieve an acceptable functional and aesthetic outcome.

In this case report, we describe a patient with a hyperdivergent skeletal pattern and open bite who underwent orthodontic treatment, orthognathic surgery and surgically assisted rapid maxillary expansion (SARME), which greatly improved her occlusion and facial profile.

Case report

Diagnosis and aetiology

A 35-year-old Chinese woman presented with the chief complaint of a “long face” and an anterior open bite. She stated that she did not have any bad oral habits and had no contraindications to orthodontic treatment. The patient was diagnosed with degree II hypertrophy of the palatine tonsils. She had a convex profile, a hyperdivergent vertical skeletal pattern and lip incompetence at rest (Fig 1). The upper lip–tooth display was balanced and the mandibular midline was skewed by 1.0 mm to the patient’s right. She also had marked mandibular asym-

1 Department of Orthodontics, Peking University School and Hospital of Stomatology, Beijing, P.R. China.

2 National Centre of Stomatology; National Clinical Research Centre for Oral Diseases; National Engineering Laboratory for Digital and Material Technology of Stomatology, Beijing, P.R. China.

3 Department of Oral and Maxillofacial Surgery, Peking University School and Hospital of Stomatology, Beijing, P.R. China.

Corresponding authors: Dr Wei Ran LI, Department of Orthodontics, Peking University School and Hospital of Stomatology, #22 Zhongguancun Avenue South, Haidian District, Beijing 100081, P.R. China. Tel: 86-10-82195332; Fax: 86-10-62173402. Email: weiranli@bjmu.edu.cn

Dr Yi Ping HUANG, Department of Orthodontics, Peking University School and Hospital of Stomatology, #22 Zhongguancun Avenue South, Haidian District, Beijing 100081, P.R. China. Tel: 86-10-82195332; Fax: 86-10-62173402. Email: yipinghuang@bjmu.edu.cn

This study was financially supported by grants from the National Natural Science Foundation of China (no. 82071119).

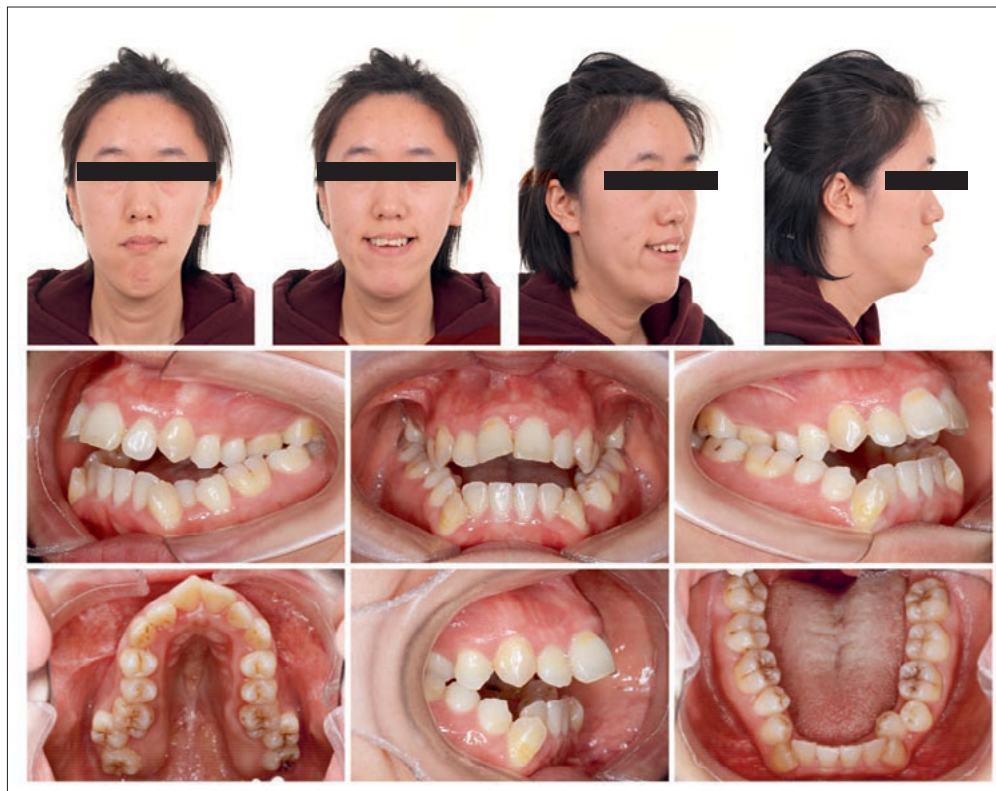

Fig 1 Pretreatment facial and intraoral photographs.

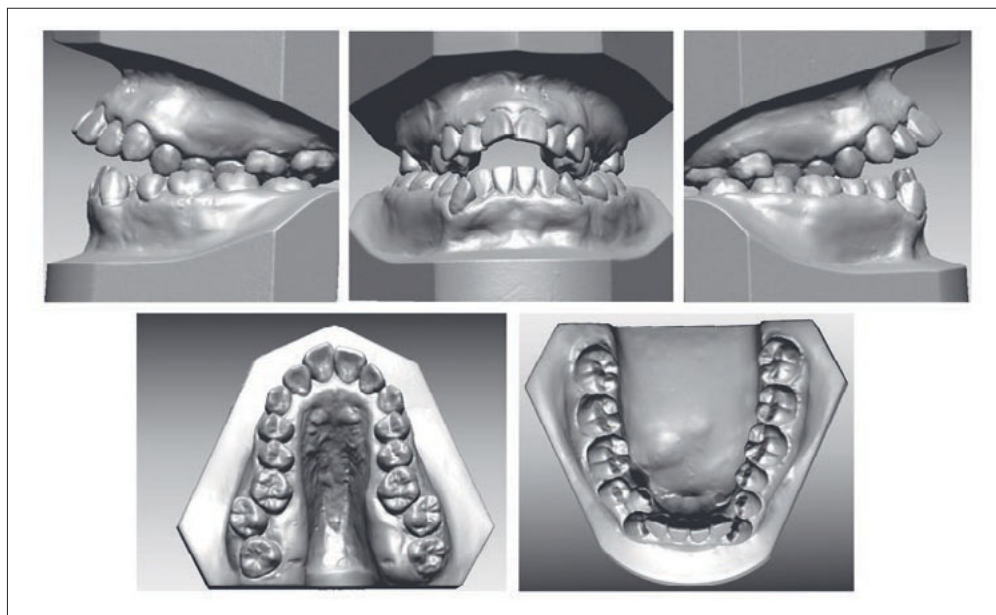


Fig 2 Pretreatment dental casts.

metry, with the chin point shifted 4.0 mm to the right. Intraoral photographs (Fig 1) revealed an Angle Class III molar relationship with a 7.0-mm open bite and a 7.5-mm horizontal overlap. The dental cast analysis showed a severe transverse discrepancy, with a maxillary intercanine width of 31.7 mm and an intermolar width of 35.8 mm. A bilateral reverse articulation of the

first molars was also observed. Moderate crowding of the maxillary teeth (5.0 mm) and severe crowding of the mandibular teeth (10.0 mm) were present (Fig 2). There was no tooth size discrepancy, and there was a moderate curve of Spee. Although temporomandibular joint asymmetry was observed, the patient said she displayed no signs or symptoms of temporomandibular disorders.

Table 1 Cephalometric measurements.

Measurement	Norm* (mean ± SD)	Pre-treatment	Post-treatment	Difference	
Sagittal skeletal components	SNA(degrees)	82.8 ± 4.0	82.1	81.8	1.9
	SNB(degrees)	80.1 ± 3.9	77.6	80.5	2.8
	ANB(degrees)	2.7 ± 2.0	4.5	1.3	-0.8
Vertical skeletal components	MP/SN(degrees)	32.5 ± 5.2	51.9	44.5	-7.4
	PFH(mm)	82.5 ± 5.0	76.7	75.4	-1.3
	AFH(mm)	128.5 ± 5.0	134.5	124.0	-10.5
	S-Go/N-Me (PFH/AFH)(%)	65.0 ± 4.0	57.0	60.9	3.9
Dental components	U1/NA(degrees)	22.8 ± 5.7	37.2	16.0	-21.2
	L1/NB(degrees)	30.5 ± 5.8	18.9	18.3	-0.6
	U1/L1(degrees)	125.4 ± 7.9	121.7	144.4	22.7
	U1/SN(degrees)	105.7 ± 6.3	117.1	97.8	-19.3
	L1/MP(degrees)	92.6 ± 7.0	69.3	73.3	4.0

*Reference norms for Chinese adults.

AFH, anterior facial height; ANB, A point-nasion-B point; L1/MP, mandibular incisor to mandibular plane; L1/NB, mandibular incisor to nasion-B point line; MP/SN, mandibular plane to sella-nasion plane; PFH, posterior facial height; PFH/AFH, ratio of PFH to AFH; SD, standard deviation; SNA, sella-nasion-A point; SNB, sella-nasion-B point; U1/L1, interincisal angle; U1/NA, maxillary incisor to nasion-A point line; U1/SN, maxillary incisor to sella-nasion plane.

Lateral cephalometric analysis revealed a high mandibular plane angle (MP/SN 51.9 degrees) (Table 1). There was disproportionality between the anterior lower facial height and the posterior facial height (76.7 mm and 135.5 mm, respectively), which was consistent with the patient's facial appearance. The maxillary incisors were proclined (U1/SN 117.1 degrees), whereas the mandibular incisors were lingually inclined (L1/MP 69.3 degrees). Panoramic radiographs showed complete permanent dentition with asymmetric condylar contours (Fig 3). Computed tomography (CT) showed that the labial alveolar bone was relatively thin, indicating that the inclination of the maxillary anterior teeth should be adjusted carefully to avoid periodontal damage (Fig 3). The oropharyngeal airway displayed an extremely limited volume (21882 mm³) and minimum axial area (111.7 mm²). CT revealed a constricted maxillary arch (J-J') of 61.7 mm, which should be about 68.0 mm normally. Although palatine tonsillar hypertrophy may have contributed to this malocclusion, the aetiology was unclear.

In summary, the patient was diagnosed with Angle Class III malocclusion with a hyperdivergent skeletal Class II relationship, a severe open bite and transverse deficiency.

Treatment objectives

The treatment objectives for the patient were maxillary expansion and correction of the transverse deficiency; correction of crowding in the maxilla and mandible and modification of the tapered arch forms; maxillary incisor retraction to reduce the horizontal overlap and open bite

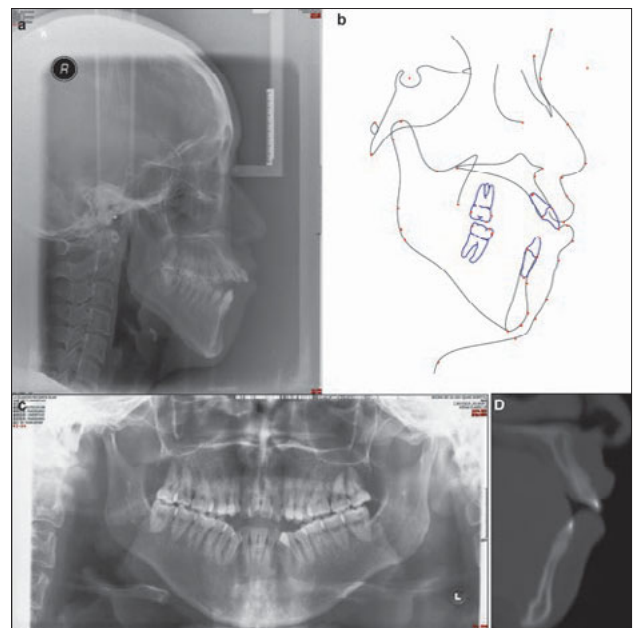


Fig 3 Pretreatment radiographs. (a) Pretreatment cephalometric radiograph. (b) Cephalometric tracing. (c) Panoramic radiograph. (d) Sagittal images from the CT.

and correct the Class III molar occlusion; and correction of the mandibular asymmetry and improvement of the elongated facial profile.

Treatment plan

The severe transverse discrepancy needed to be addressed first. Conventional orthodontic expansion was ruled out because it is difficult to expand the maxilla by approximately 7 mm in an adult patient. Although max-

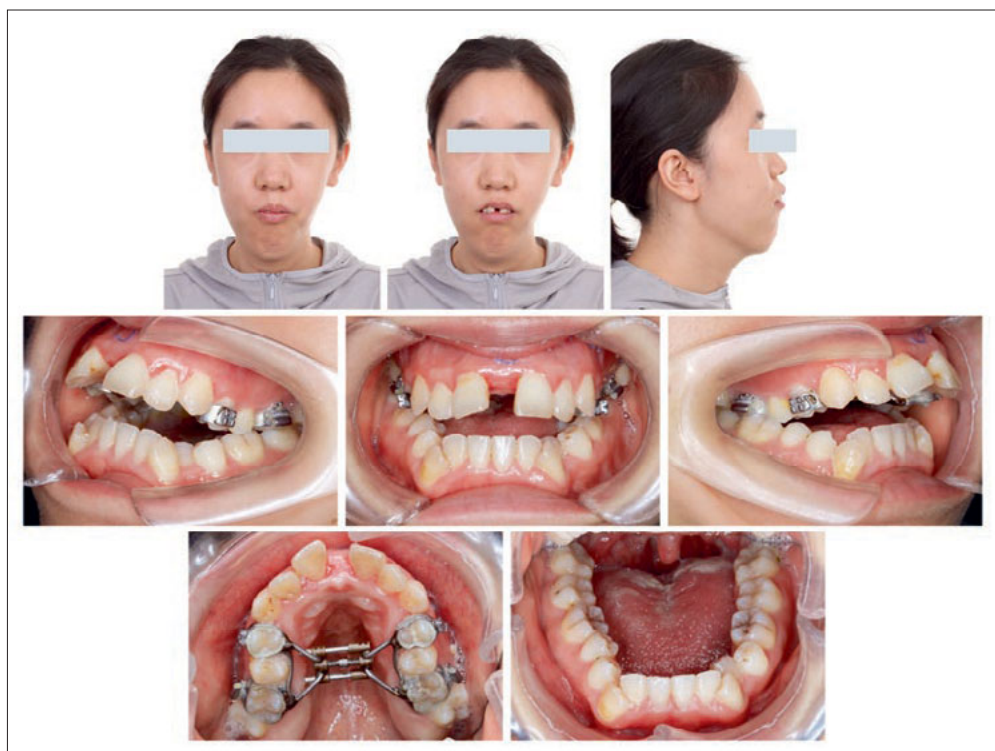

Fig 4 Patient after surgically assisted rapid maxillary expansion.

illary expansion during orthognathic surgery solves all skeletal problems in one surgical procedure, it increases the risks of the surgery greatly and reduces the stability of the final outcome. Thus, SARME using a hyrax appliance before presurgical orthodontic treatment was recommended. Subsequently, orthodontic treatment in combination with orthognathic surgery was performed with extraction of the maxillary premolars to reduce the proclination of the maxillary incisors and mandibular premolars and to correct the molar relationship prior to surgery. Orthognathic surgery involved LeFort I osteotomy for maxillary impaction and bilateral sagittal split ramus osteotomy (BSSRO) for mandibular rotation. The aim of treatment was to achieve an acceptable functional and aesthetic outcome. The treatment plan was fully explained to the patient, and she was aware of the risks.

Treatment progress

Two weeks before surgery, the maxillary first premolars and molars were separated using elastics. A conventional hyrax expander (9-mm expansion screw) was manufactured at Peking University, Beijing, China and bonded before surgery. Surgery was initiated using the established SARME methodology³. The hyrax expander was activated twice a day, creating 0.5-mm maxillary expansion daily. The amount of expansion was then evaluated clinically every other day. Two weeks days after

SARME, the patient presented with 4 mm expansion of the palatine suture and a diastema between the maxillary central incisors (Fig 4). The hyrax was kept in situ for 6 months for retention based on a previous study⁴.

Two mandibular second premolars were extracted and 0.022- × 0.028-inch straight wire preadjusted appliances (Shinya, Hangzhou, China) were placed in the maxilla, while segmental arches were used to distalise the first premolars to relieve the crowding of the mandibular incisors (Fig 5). Once sufficient space was obtained for the mandibular incisors, the two maxillary first premolars were extracted, the hyrax expander was removed and all the mandibular teeth were bonded with brackets for levelling and alignment. Placement of sequential nickel titanium archwires was initiated, starting with a 0.012-inch wire and ending with a 0.018- × 0.025-inch wire. To close the tooth extraction spaces, a 0.019- × 0.025-inch stainless-steel archwire was placed in the mandible using the classic sliding mechanism. Because of the thin labial and lingual upper alveolar bone, the maxillary extraction space was only used to reduce the labial inclination of the maxillary incisors without retraction of the anterior teeth, which may have led to bone fenestration or dehiscence. After achieving proper inclination of the maxillary incisors for surgery, the spaces remained, and were closed during orthognathic surgery. The patient was ready for surgery after 20 months of presurgical orthodontic treatment (Fig 6).

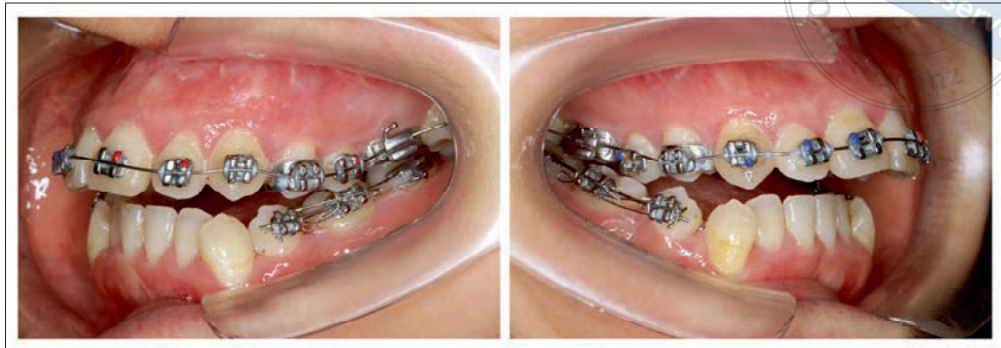


Fig 5 Brackets were bonded and segmental arches were used in the mandible to distalise the first premolars to relieve the crowding of the mandibular incisors.

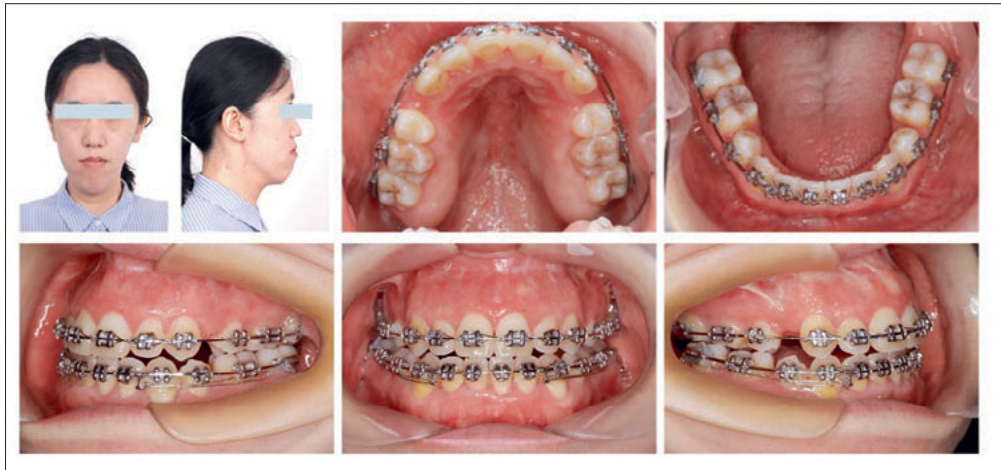

Fig 6 Preoperative facial and intraoral photographs.

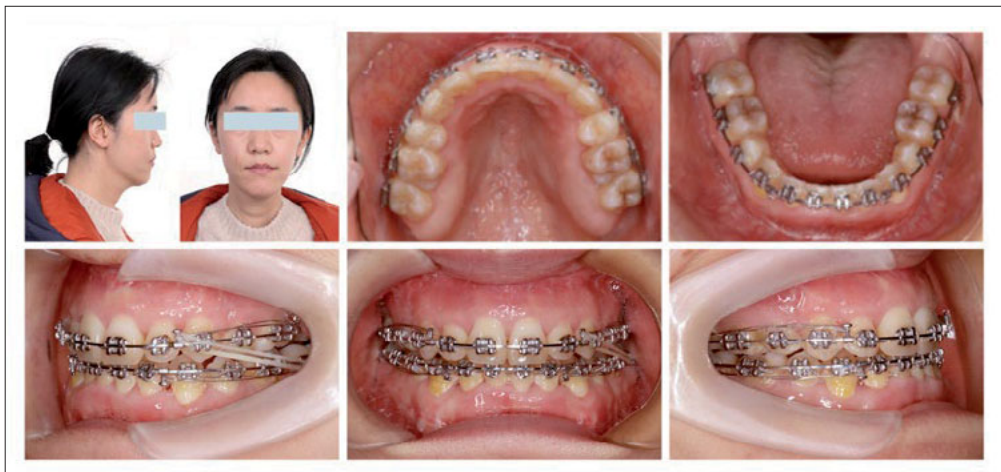

Fig 7 Postoperative facial and intraoral photographs.

A presurgical visual treatment objective (VTO) was used to guide the surgery (Fig S1, provided on request). According to the intermediate splint, the maxilla was split into four pieces: bilaterally at the tooth extraction spaces and mesial to the two central incisors. The posterior segments were raised by 5 mm and the anterior segments by 4 mm. The paranasal area was moved forwards by 2 mm, while the incisor edges remained unchanged. The intermediate splint was then replaced with the final splint. Anticlockwise mandibular rotation

with BSSRO followed by rigid internal fixation was performed. One month after surgery, Class II elastics were used on the left side to treat the unilateral Class II malocclusion (Fig 7). The total treatment duration was 40 months. The severe transverse discrepancy, vertical overgrowth and sagittal protrusion were resolved. A normal horizontal and vertical overlap were achieved in both the anterior and posterior arches. The orthodontic appliances were removed after treatment completion, and invisible retainers were used for retention.

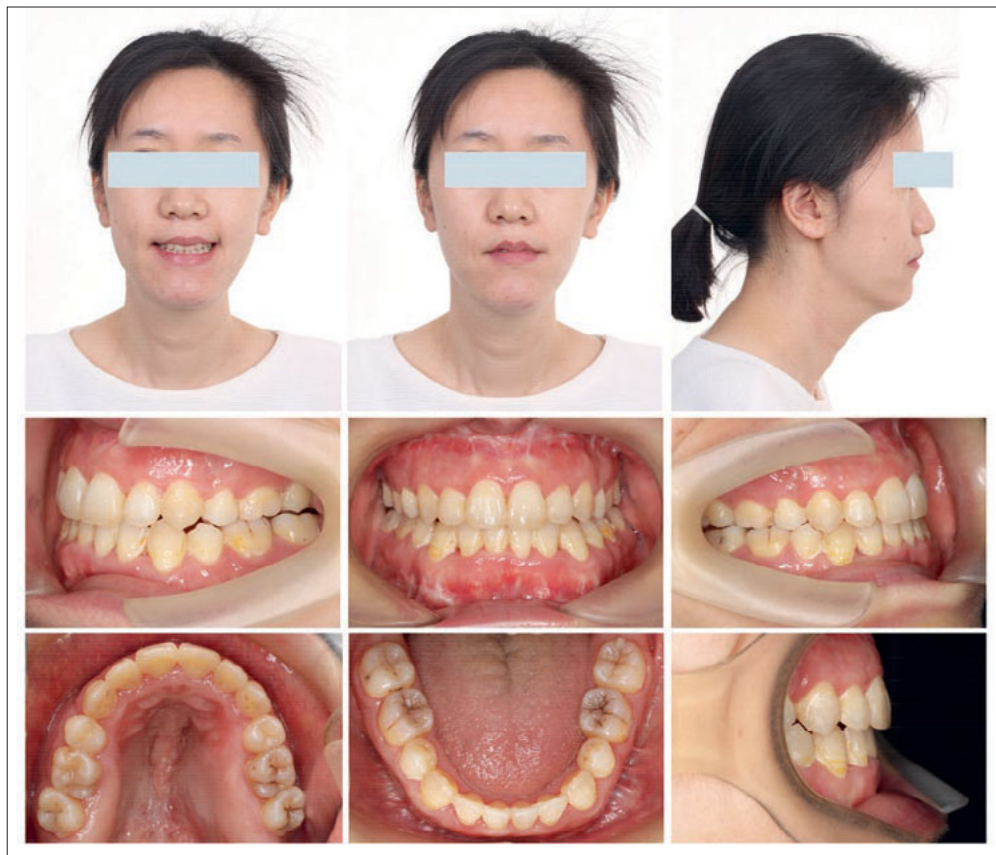

Fig 8 Posttreatment facial and intraoral photographs.

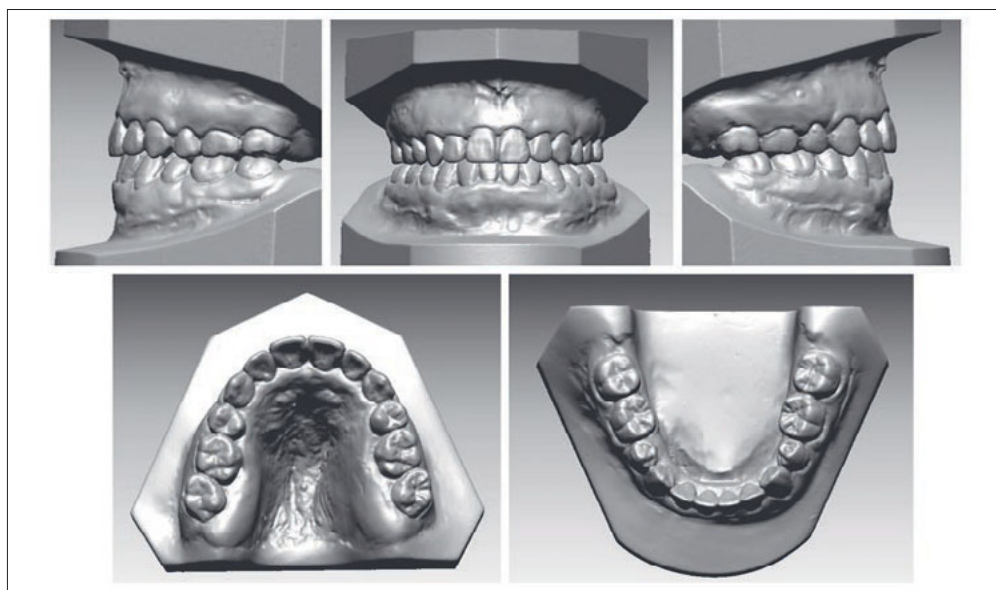


Fig 9 Posttreatment dental casts.

Treatment results

After treatment, extraoral photographs demonstrated that the hyperdivergent skeletal pattern had improved significantly, with a reduction in lip incompetence noted at rest (Fig 8). The decrease in facial height led to an

improved facial profile. The anticlockwise rotation of the mandible decreased the angle of the mandibular plane. The maxillary incisor protrusion was corrected. Intraoral photographs showed significant correction of the arch shapes and well-aligned dentition (Figs 8 and 9). The open bite and horizontal overlap were corrected,

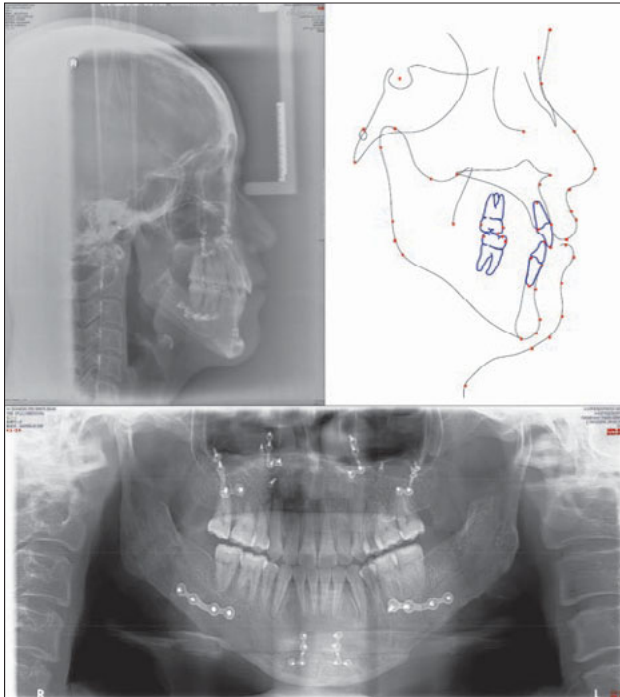


Fig 10 Posttreatment radiographs. (a) Posttreatment cephalometric radiograph. (b) Cephalometric tracing. (c) Panoramic radiograph.

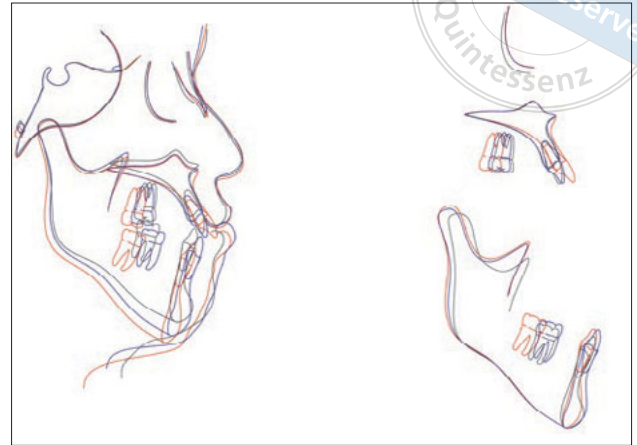


Fig 11 Pretreatment (red), preoperative (blue) and posttreatment (black) cephalometric superimpositions.

Table 2 Comparison of the means of maxillary dimensions before and after treatment.

Measurement	Pre-treatment (T0)	Post-treatment (T1)	1-year follow-up (T2)	T1-T0	T2-T0
Inter canine width (mm)	31.7	34.3	34.6	2.6	2.9
Inter-first molar width (mm)	35.8	46.2	46.1	10.4	10.4

Table 3 Comparison of maxillary width before and after treatment.

Measurement	Pre-expansion (T0)	Post-expansion (T1)	T1-T0
Maxillary width J-J' (mm)	61.7	67.1	6.3

and Class I molar and canine relationships were established. After treatment, the patient presented with a harmonious facial profile with decreased facial convexity.

The posttreatment panoramic radiographs demonstrated root parallelism in all the teeth, and there was no obvious root or alveolar bone resorption (Fig 10). Cephalometric analysis showed a significant decrease in MP/SN by 7.4 degrees and in U1/SN by 19.3 degrees (Table 1). The superimposition of the lateral cephalograms on the anterior cranial base from the pretreatment, preoperative (after presurgical orthodontics) and posttreatment phases demonstrated anticlockwise mandibular rotation with a decreased anterior facial height, although the patient still had a hyperdivergent vertical skeletal pattern. The superimposition on the palatal plane displayed molar mesialisation and incisor retrocli-

nation compared to pretreatment tracing (Fig 11). The patient showed less lip incompetence, and the soft tissue profile was markedly improved due to the decrease in vertical facial height and maxillary incisor retraction.

The intermolar width increased by 10.4 mm and the intercanine width increased by 2.6 mm (Table 2). In addition, CT showed that the maxillary skeletal base width had increased by 6.3 mm (Table 3).

Quantitative measurement of the oropharyngeal airway volumes was performed according to the following defined borders: anterior border, the vertical plane passing through the posterior nasal spine (PNS); superior border, the horizontal plane passing from the PNS; posterior border, the posterior pharyngeal wall; and inferior border, the horizontal plane passing from the most anterior and inferior point of the third vertebra. The minimum

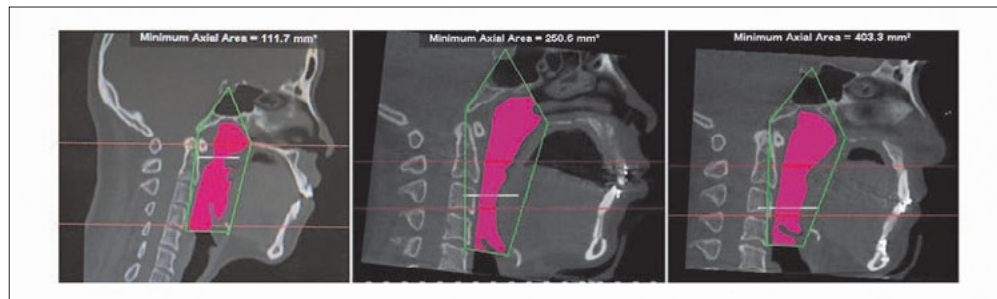


Fig 12 Pretreatment, post-SARME and postoperation oropharyngeal airway changes.

Table 4 Airway changes.

Measurement	Pre-treatment	Post-SARME	Post-treatment
Minimum axial area (mm ²)	111.7	258.6	403.3
Oropharyngeal airway volume (mm ³)	21882.0	23614.0	27283.9

axial areas increased by 146.9 mm² after SARME and by 296.1 mm² after mandibular advancement surgery. The volume of the oropharyngeal airway increased by 1732.0 mm³ after SARME and 5401.9 mm³ after mandibular surgery (Fig 12 and Table 4).

One year after completion of orthodontic treatment, the occlusion and arch forms were stable with a harmonious facial profile (Fig 13 and Table 2).

Discussion

The patient presented with a hyperdivergent skeletal pattern combined with an anterior open bite and transverse discrepancy. Orthodontic treatment was combined with a properly designed and executed surgical intervention to achieve this goal. Treatment of such patients requires 3D consideration due to their complexity.

In such cases, transverse discrepancies must be solved first. Rapid maxillary expansion (RME) is an effective clinical procedure for correcting transverse maxillary deficiency and increasing the arch length in adolescents. However, adult patients present with ossification of the midpalatal suture due to completed skeletal growth, and conventional RME has limited effects and can even cause periodontal defects and gingival recession⁵. SARME was first used in orthodontic treatment in 1938 to solve transverse discrepancies. Its advantages of SARME are improved nasal airflow, reduced buccal corridor when smiling and created space. In addition, SARME shows long-term stability of alveolar, intercanine, and intermolar widths according to a meta-analysis³. In the present patient, SARME successfully expanded the maxilla without obvious maxillary molar elongation, which may have led to clockwise rotation of the mandible and a worse facial profile. Considering the relapse of SARME over time, the hyrax

expanders were removed after 6 months of use.

The effects of SARME on pharyngeal enlargement, which further improved nasal respiratory function, have been reported widely^{6,7}. Some studies have reported that after SARME, respiratory parameters improved slightly during sleep, and the mandibular advancement procedure enlarged the airway significantly⁸. In the present patient, CT results showed that SARME enlarged the minimum axial area of the airway significantly, from 111.7 to 258.6 mm² (Table 4). The SARME procedure had a positive impact on the airway volume, provided the tongue with available space, improved the patient’s respiratory function significantly and reduced lip incompetence.

A skeletal open bite is one of the most challenging malocclusions to treat because of the high frequency of relapse⁹. Conventional orthodontic treatment with molar intrusion using temporary anchorage devices (TADs) to achieve a compromised result without skeletal correction has been reported to result in relapse in approximately 10% to 30% of cases¹⁰. Orthognathic surgery is used widely to treat severe skeletal open bite; however, a meta-analysis showed that vertical relapses, including a decrease in vertical overlap and an increase in the intermaxillary angles and mandibular plane, were characteristics of numerous patients who received combined orthodontic surgical therapy regardless of surgery type¹¹. Proffit et al¹² found that patients who underwent maxillary surgery only were less prone to relapse (7% decrease in vertical overlap) than those who received maxillomandibular surgery (12% decrease in vertical overlap). However, a recent meta-analysis reported that maxillomandibular surgery produced the most beneficial postoperative increase in vertical overlap and was more stable than maxillary or mandibular surgery¹³. Moreover, overcorrection of vertical overlap

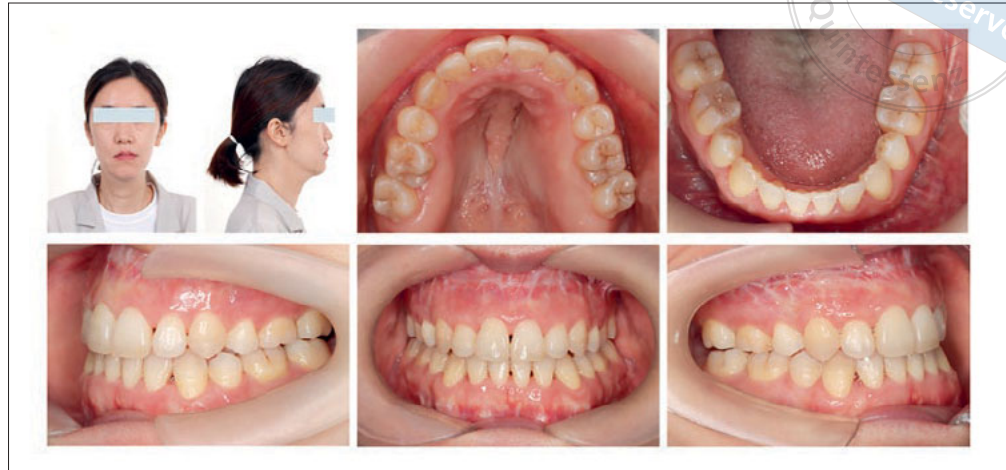

Fig 13 Postretention facial and intraoral photographs (1-year follow-up).

is often needed to reduce the risk of relapse. In this patient, maxillomandibular surgery was performed and a slightly deeper vertical overlap was achieved, which remained favourable at the 1-year follow-up.

To address the sagittal problems, the periodontal risks of alveolar bone fenestration and dehiscence should be considered. Thus, in this case, segmental arches were first used to reduce the proclination of the mandibular incisors and avoid periodontal issues. Moreover, the mandibular incisors were not retracted to close the extraction space before surgery; instead, we kept the space and closed it during orthognathic surgery, which posed little risk to periodontal health. Finally, BSSRO significantly alleviated the patient's obstructive sleep apnoea (OSA). OSA usually affects quality of life and can even increase the risk of death¹⁴. Previous studies have shown that maxillomandibular advancement surgery is helpful in patients with OSA. Mandibular advancement of more than 10 mm effectively enlarges the pharyngeal spaces, especially the oropharynx and hypopharynx, and has a positive effect on OSA patients¹⁵. In the present patient, enlargement of the oropharyngeal airway volume was significant, especially in the minimal axis area, which may significantly improve the patient's sleep quality.

Recently, 3D virtual planning has been used increasingly in orthognathic surgery, allowing to the clinician to simulate surgery and visualise the postoperative outcomes in the soft and hard tissues. Such technology was not used in the treatment planning for this patient, which can be considered a limitation of this study.

Conclusion

Orthodontic treatment combined with SARME and orthognathic surgery should be considered in patients

with a hyperdivergent skeletal pattern and skeletal anterior open bite. 3D problems should be considered to achieve this goal. SARME can produce fewer negative effects on the teeth and is suitable for adults who have already completed their skeletal growth. BSSRO combined with Lefort I needs to be performed to reduce the high mandibular plane angle open bite in adult patients. The surgery can lead to a favourable anticlockwise mandibular rotation and optimal horizontal and vertical overlap. One year after surgery, no relapse was observed; however, to assess the long-term stability of this treatment modality, a longer follow-up period is needed in the future. Moreover, this case report demonstrated the harmonious cooperation between an orthodontist and oral and maxillofacial surgeons to achieve a successful functional and aesthetic outcome.


Conflicts of interest

The authors declare no conflicts of interest related to this study.

Author contribution

Dr Yi Neng HAN took part in the orthodontic treatment and drafted the manuscript; Dr Hao LIU took part in the orthodontic treatment; Dr Zi Li LI and his team performed the surgical treatment; Dr Yi Ping HUANG took part in the orthodontic treatment and revised the manuscript; Dr Wei Ran Li performed the orthodontic treatment and approved the final manuscript.

(Received Apr17, 2022; accepted Jun19, 2022)



References

1. Kim YH, Han UK, Lim DD, Serrao ML. Stability of anterior openbite correction with multiloop edgewise archwire therapy: A cephalometric follow-up study. *Am J Orthod Dentofacial Orthop* 2000;118:43–54.
2. Nahoum HI, Horowitz SL, Benedicto EA. Varieties of anterior openbite. *Am J Orthod* 1972;61:486–492.
3. Loriato L, Ferreira CE. Surgically-assisted rapid maxillary expansion (SARME): Indications, planning and treatment of severe maxillary deficiency in an adult patient. *Dental Press J Orthod* 2020;25:73–84.
4. Karabiber G, Yılmaz HN, Nevzatoğlu Ş, Uğurlu F, Akdoğan T. Three-dimensional evaluation of surgically assisted asymmetric rapid maxillary expansion. *Am J Orthod Dentofacial Orthop* 2019;155:620–631.
5. Bell RA. A review of maxillary expansion in relation to rate of expansion and patient's age. *Am J Orthod* 1982;81:32–37.
6. Zambon CE, Cecchetti MM, Utumi ER, et al. Orthodontic measurements and nasal respiratory function after surgically assisted rapid maxillary expansion: An acoustic rhinometry and rhinomanometry study. *Int J Oral Maxillofac Surg* 2012;41:1120–1126.
7. Vinha PP, Faria AC, Xavier SP, Christino M, de Mello-Filho FV. Enlargement of the pharynx resulting from surgically assisted rapid maxillary expansion. *J Oral Maxillofac Surg* 2016;74:369–379.
8. Foltán R, Hoffmannová J, Pavlíková G, et al. The influence of orthognathic surgery on ventilation during sleep. *Int J Oral Maxillofac Surg* 2011;40:146–149.
9. Greenlee GM, Huang GJ, Chen SS, Chen J, Koepsell T, Hujuel P. Stability of treatment for anterior open-bite malocclusion: A meta-analysis. *Am J Orthod Dentofacial Orthop* 2011;139:154–169.
10. González Espinosa D, de Oliveira Moreira PE, da Sousa AS, Flores-Mir C, Normando D. Stability of anterior open bite treatment with molar intrusion using skeletal anchorage: a systematic review and meta-analysis. *Prog Orthod* 2020;21:35.
11. Solano-Hernández B, Antonarakis GS, Scolozzi P, Kiliaridis S. Combined orthodontic and orthognathic surgical treatment for the correction of skeletal anterior open-bite malocclusion: A systematic review on vertical stability. *J Oral Maxillofac Surg* 2013;71:98–109.
12. Proffit WR, Bailey LJ, Phillips C, Turvey TA. Long-term stability of surgical open-bite correction by Le Fort I osteotomy. *Angle Orthod* 2000;70:112–117.
13. Wang M, Zhang B, Li L, Zhai M, Wang Z, Wei F. Vertical stability of different orthognathic treatments for correcting skeletal anterior open bite: A systematic review and meta-analysis. *Eur J Orthod* 2022;44:1–10.
14. Martelli-Junior H, Coletta RD, Miranda RT, Barros LM, Swerts MS, Bonan PR. Orofacial features of Treacher Collins syndrome. *Med Oral Patol Oral Cir Bucal* 2009;14:E344–E348.
15. Goncalves JR, Buschang PH, Goncalves DG, Wolford LM. Postsurgical stability of oropharyngeal airway changes following counterclockwise maxillo-mandibular advancement surgery. *J Oral Maxillofac Surg* 2006;64:755–762.