

Clinical Features and Treatment of Mandibular Canines with Two Root Canals: Two Case Reports

Li WANG¹, Rui ZHANG¹, Bin PENG¹

Two clinical case reports are presented to illustrate the anatomical variation found in the human mandibular canine. In the first case, the mandibular canine has one root and two root canals. In the second case, the mandibular canine has two distinct roots. Both were treated with conventional endodontic treatment.

Key words: canal anatomy, endodontic treatment, mandibular canine

Thorough knowledge of the external and internal anatomy of teeth is essential in root canal treatment and crucial for success. Endodontic treatment failure can be attributed to lack of knowledge of the wide morphological divergence of the root canal system. Mandibular canines are recognised as having one root and one root canal in the majority of cases. Regarding anatomical variations associated with mandibular canines, approximately 15% contain two canals with one or two foramina¹⁻³. A study of the internal anatomy, direction, number of roots and size of 830 extracted human mandibular canines showed that 98.3% of these teeth contain a single root, 92.2% consist of one canal and one foramen, 4.9% have two canals and one foramen, and 1.2% contain two canals and two foramina⁴. The incidence of two-rooted canines was as low as 1.7%. Clinicians should be aware of anatomical variations, and should never assume that canal systems are simple. Two cases of a mandibular canine with two root canals are reported, both treated with root canal therapy.

Case Reports

Case 1

A 46-year-old Chinese female complained of severe pain in the right mandible. Clinical examination revealed that

tooth 43 had deep occlusal caries. A thermal test with ethyl chloride along with a percussion test produced severe, long-lasting pain. A diagnostic radiograph did not reveal periapical pathology but did indicate two root canals (Fig 1A). The patient was then diagnosed with irreversible pulpitis. Local anaesthesia was administered and a rubber dam was placed. The opening of the pulp chamber was prepared using a round diamond bur (Dentsply Maillefer, York, PA, USA). The pulp chamber was opened extensively and both the buccal and lingual canal were located. The working length for both canals was established with the use of radiography. The root canal configuration consisted of two canals leaving the floor of the pulp chamber, converging into one canal and exiting at a single apical foramen. The canals were instrumented with Flexofiles and Gates Glidden burs (Dentsply Maillefer) using a step-down instrumentation technique. The root canals were irrigated with 1% NaClO during the preparation procedure and 17% EDTA was used as a final irrigation to remove the smear layer after the preparation procedure. The canals were filled by lateral condensation technique (Fig 1B). After obturation, the access cavity was sealed with resin.

Case 2

A 40-year-old female complained of occasional discomfort from her right mandible. Clinical examination revealed that tooth 43 had deep cervical caries, and the tooth gave slight tenderness to percussion and palpation and was not sensitive to a thermal test. The diagnostic radiograph showed a periapical lesion associated with tooth 43 as well as the presence of two roots (Fig 2A). The patient was diagnosed with

1 Department of Endodontics, School and Hospital of Stomatology, Wuhan University, Wuhan, P.R. China.

Dr Li WANG and Dr Rui ZHANG contributed equally to this article.

Corresponding author: Dr Bin PENG, School and Hospital of Stomatology, Wuhan University, 65 Luoyu Road, Wuhan 430079, P.R. China. Fax: 86-27-87873260; Tel: 86-27-87161981; Email: pbs301@vip.163.com

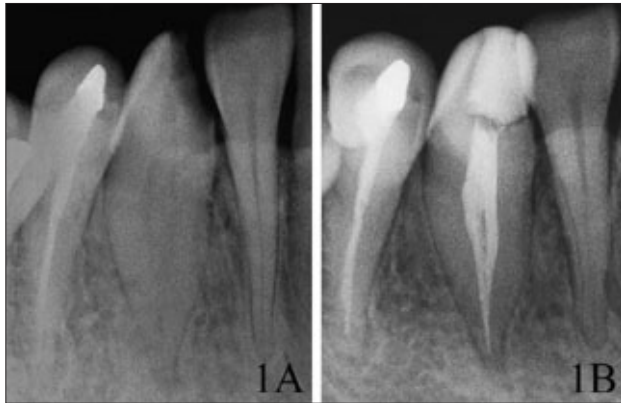


Fig 1 Case 1: (A) preoperative radiograph of tooth 43 shows two root canals; (B) final obturation of the root canals using cold lateral condensation.

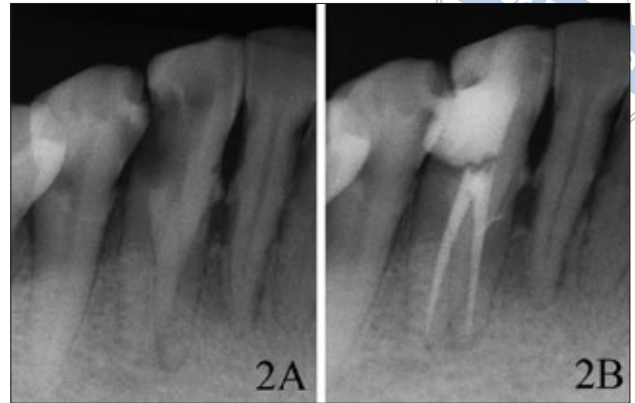


Fig 2 Case 2: (A) preoperative radiograph of tooth 43, indicating two roots; (B) final obturation of the root canals using vertical condensation of warm gutta-percha.

chronic periapical periodontitis. Access was achieved using a round diamond bur and a rubber dam was placed. The pulp chamber was opened extensively to facilitate the location of the buccal and lingual canals. Working length was established for both canals by use of radiography. The canals were instrumented with ProTaper[®] (Dentsply Maillefer) files using a crown-down instrumentation technique. The root canals were irrigated with 1% NaClO during the preparation procedure and 17% EDTA was used as a final irrigation to remove the smear layer. The canals were filled by vertical condensation of warm gutta-percha (Fig 2B). After obturation, the access cavity was sealed with resin.

Discussion

It is important to recognise the possible permutations of canal morphology in endodontic therapy. Failure to locate and treat an extra canal is one of the most common causes of root canal treatment failure. Some root canals are often left untreated because the clinicians fail to identify additional root canals or anatomical variations. If the clinician is alert to the clues that suggest the extra canal's presence, most of them can be found.

It is essential that clinicians know the clinical and radiographic signs that suggest the presence of extra canals. Endodontic exploration and a thorough and careful radiographic evaluation could lead to identification or suspicion of additional canals.

Radiographs taken from different angles, along with a file in place, might be helpful in finding and locating extra canals. The relationship of the two canal orifices is also significant, as the closer the orifices are to each other, the greater the chance that the two canals join at some point within the body of the root^{1,3,5}.

In the majority of cases, the mandibular canines are recognised as usually having one root and one root canal. Green⁶ and Vertucci³ reported that 15% of mandibular canines possess two canals with one or two foramina. Mandibular canines with two roots and two canals were also described⁷, as well as three canals and two foramina in a mandibular canine⁸. All of these cases suggest abnormal development of the tooth and root.

Thorough knowledge of anatomical variations in the root canal is essential, and it is imperative that clinicians do not assume that root canal systems are simple. These case reports highlight the importance of having detailed knowledge of all possible root canal irregularity: practitioners should look for extra canals in all root canal cases.

References

1. Pineda F, Kuttler Y. Mesiodistal and buccolingual roentgenographic investigation of 7,275 root canals. *Oral Surg Oral Med Oral Pathol* 1972;33:101-110.
2. Vertucci FJ. Root canal anatomy of the mandibular anterior teeth. *J Am Dent Assoc* 1974;89:369-371.
3. Vertucci FJ. Root canal anatomy of the human permanent teeth. *Oral Surg Oral Med Oral Pathol* 1984;58:589-599.
4. Pecora JD, Sousa Neto MD, Saquy PC. Internal anatomy, direction and number of roots and size of human mandibular canines. *Braz Dent J* 1993;4:53-57.
5. Çaliskan MK, Pehilvan Y, Sepetçioğlu F, Türkün M, Tuncer S. Root canal morphology of human permanent teeth in a Turkish population. *J Endod* 1995;21:200-204.
6. Green D. Double canal in single roots. *Oral Surg Oral Med Oral Pathol* 1973;35:689-696.
7. D'Arcangelo C, Varvara G, De Fazio P. Root canal treatment in mandibular canines with two roots: a report of two cases. *Int Endod J* 2001;34:331-334.
8. Orgunseser A, Kartal N. Three canals and two foramina in a mandibular canine. *J Endod* 1998;24:444-445.