

# DZZ

3 | 2022  
4. VOLUME

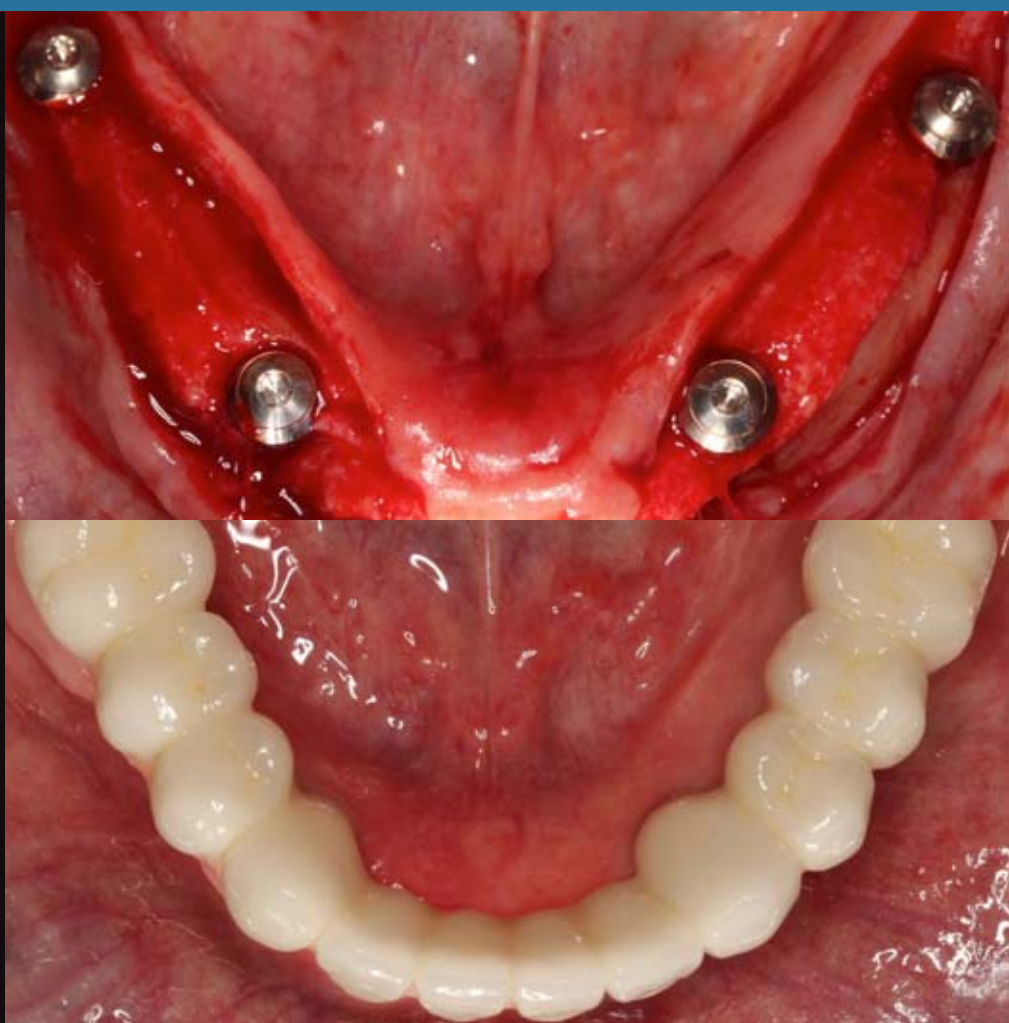
## INTERNATIONAL

German Dental Journal International – [www.online-dzz.com](http://www.online-dzz.com)  
International Journal of the German Society of Dentistry and Oral Medicine

Psoriatic arthritis and the  
temporomandibular joint

Treatment of the edentulous  
mandible with a fixed bridge  
supported by 4 mm short  
implants in the molar  
region – a case report

Popular and loyal to the  
regime: The life and work of  
CVDZ President Wilhelm  
Herrenknecht



This journal is regularly listed  
in CCMED / LIVIVO and in ICMJE.

 Deutscher  
Ärzteverlag

**PRACTICE****MINIREVIEW**

Michael Behr, Jochen Fanghänel, Bärbel Miehe, Stephan Schreml

- 89 Psoriatic arthritis and the temporomandibular joint**

**CASE REPORT**

Christine Mirzakhanian, Joachim Esken, Magdalena Schlegel, Guido Heydecke

- 94 Treatment of the edentulous mandible with a fixed bridge supported by 4 mm short implants in the molar region – a case report**

**RESEARCH****ORIGINAL ARTICLE**

Dominik Groß

- 100 Popular and loyal to the regime: The life and work of CVDZ President Wilhelm Herrenknecht**

- 108 LEGAL DISCLOSURE**

**Title picture:** From original article by Mirzakhanian, Esken, Schlegel, Heydecke: Treatment of the edentulous mandible with a fixed bridge ... p. 94–99. Fig. 3 and 7 (Photos: C. Mirzakhanian/UKE)

**Online-Version of DZZ International:** [www.online-dzz.com](http://www.online-dzz.com)

# Psoriatic arthritis and the temporomandibular joint



## Question:

What are the implications of psoriatic disease in dentistry?

## Background:

Psoriasis has a complex clinical profile with many different forms (Fig. 1); these may be associated with inflammatory altered joints, enthesitis, spondyloarthropathies of the spine, dactylitis, characteristic scaly skin changes as well as tongue and nail changes [7, 9, 24]. We distinguish an early form (onset at the age of 10–25 years) in the case of corresponding genetic disposition and a later form (onset at the age of 35–60 years), which generally shows no familial clustering. The special form of psoriatic arthritis has only been classified as an independent clinical picture since the 1960s and has been distinguished from rheumatoid arthritis with parallel skin changes. Psoriatic arthritis may have regionally variable incidences (0.05–0.24%) [11]. Its prevalence among patients with psoriasis has been reported to be around 6–41% [17]. The disease has relevance in dentistry because the temporomandibular joint and the mucosa of the oral cavity, including the tongue, may be affected.

**Comorbidities.** Patients with psoriasis require special attention due to their multiple comorbidities [24, 25]; the goal is to minimize the

risks associated with comorbidities during dental procedures [5]. The list of possible comorbidities is extensive [21]; it includes cardiovascular disease with an increased risk of myocardial infarction, structural coronary artery disease, and a predisposition to hypertension [28]. In patients with psoriasis, there is an increased risk of stroke [10] and of developing dementia as well as Parkinson's disease [26]. Furthermore, there is an increased incidence of liver and kidney dysfunction associated with psoriasis [24]. In addition, there is an increased risk of diabetes mellitus, Crohn's disease, pulmonary diseases such as bronchial asthma [24], endocrine diseases, as well as ophthalmologic complications such as conjunctivitis, cataract, or uveitis [5, 16].

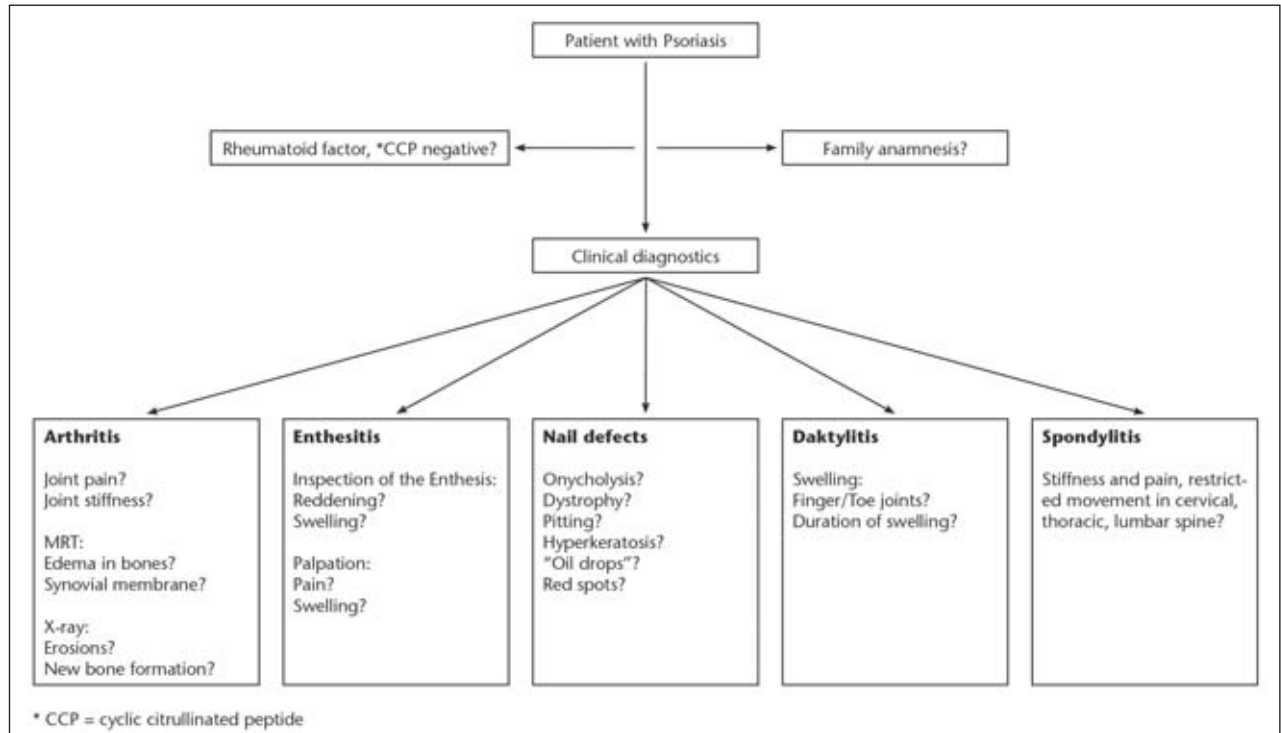
**Clinic.** Psoriatic arthritis mostly manifests between the 30th and 55th year of life. As a rule, disorders in the temporomandibular joint only appear years (~10 years) [5] after the onset of the skin and nail changes (Fig. 2), the characteristic swelling of the finger joints, or after the onset of disorders in other joints. In some cases, arthritis of the temporomandibular joint may occur as the initial manifestation of psoriatic disease. Dental practitioners then have the responsibility of establishing the course of treatment and referring patients to the appropriate specialists. At pres-

ent, if psoriatic arthritis is recognized and treated in time, damage to the joints can be avoided or significantly reduced [27].

**Classification and forms of psoriatic arthritis.** Based on topography and structural differences, four forms can be distinguished [19]. Along with them all the above-mentioned pathological patterns can occur. The four forms are:

- Axial type. It occurs along the axial skeleton. Disease patterns include mainly sacroilitis and ankylosing spondylitis. In most cases, it is associated with the peripheral type.
- Peripheral type. This is the most common type. It is characterized by destructive arthritis/polyarthritides of the small joints of the hand and foot, but also to some extent of the large joints (knee joint). Periosteal changes and acroosteolysis are often present.
- Monoarthritis type. It mostly affects the large joints such as the knee and hip as well as the upper and lower ankle joints. Manifestation together with the axial and peripheral types is possible.
- Arthritis mutilans. Besides the above-mentioned arthritides, bone resorptions are possible.

In addition to complaints in the joints, changes in the skin, skin appendages and soft tissues are also relevant for the diagnosis and therapy of patients.



**Figure 1** Multidimensional nature of the possible clinical symptoms of psoriatic disease

Fig. 1, 5, 6: M. Behr

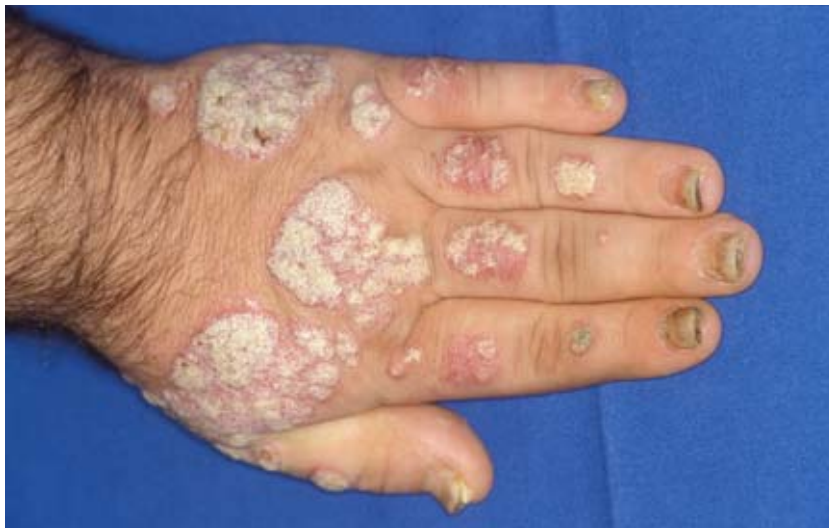

Fig. 2: S. Schreml

**Figure 2** Typical skin and nail changes associated with psoriasis. In addition to the flaky, silvery patches of efflorescent cutis, the figure shows signs of dactylitis and, on the nails, signs of onycholysis and psoriatic onychodystrophy.

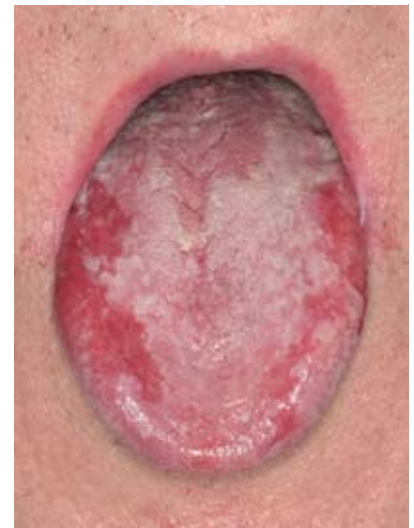

Fig. 3: T. E. Reichert, Clinic and Polyclinic for Oral and Maxillofacial Surgery, Regensburg University Hospital

**Figure 3** Lingua geographica. View from above

**Skin/mucous membrane changes.** Skin lesions appear in 80% of cases as raised, sharply and irregularly delimited, reddish plaques (plaque vulgaris) with silvery scaling (Fig. 2), which may bleed under light mechanical stress. In approximately 5% of cases, psoriasis appears as pustular, purulent efflorescence (pustular psoriasis, Barber type) [5].

In the oral cavity, psoriasis rarely occurs on the lips, and to a reduced

extent, on the oral mucosa. According to Hornstein [14], this is explained by the fact that there is a 5 to 7 times higher proliferation rate of the oral mucosa compared to the epidermis of the outer skin. Thus, the proliferation rate of the outer epidermis in psoriasis is approximately the same as that of the oral mucosa. Therefore, the effects of psoriatic disease virtually do not appear on the oral mucosa. On the dorsum of the

tongue, however, the conditions of keratinization are different. As a result, an erythematous tongue with pronounced exfoliation and pustule formation may occur in the marginal zones (geographic tongue) [18] (Fig. 3). The lingual papillae may be flattened and therefore distinguishable from the healthy papillae (Fig. 4).

**Nail changes.** About 80% of all patients with psoriatic arthritis devel-

	Psoriatic arthritis	Rheumatoid arthritis	Gout	SAPHO Syndrome	Crohn's disease/ Ulcerative colitis
<b>Number of affected joints</b>	Oligoarthritis	Polyarthritis	Monoarthritis	Oligoarthritis	Oligoarthritis
<b>Typically affected joints</b>	All joints, including the distal interphalangeal joints	Distal interphalangeal joints	Small joints of the lower extremity, metatarsophalangeal joint (podagra) or forefoot (tarsitis)	Sternoclavicular joints, sternocostal joints, temporomandibular joint	All joints, rarely the temporomandibular joint
<b>Enthesitis</b>	In 60–80% of cases	Not typical	Not typical	Not typical	Not typical
<b>Daktylitis</b>	In 30% of cases	Not typical	Tophi	Not typical	Not typical
<b>Involvement of the spine</b>	Axial spondyloarthritis	Erosive cervical findings	Not typical	Thoracic spine areas	Not typical
<b>Skin/nails</b>	In 80% of cases plaque vulgaris, pustular psoriasis, in 60% of cases onycholysis, psoriatic onychodystrophy	Not typical	Skin erythema, soft tissue swelling, gout, tophi, rarely gout, tophi in the ear helix ("gouty pearl").	Acne, pustular palma-plantar efflorescences, also pustular psoriasis	Cheilitis, aphthous, rarely fissural ulcerative changes of the oral mucosa
<b>Serology</b>	CCP (cyclic citrullinated peptide) and rheumatoid factor are negative	CCP and rheumatoid factor are positive	CCP and rheumatoid factor are negative, uric acid serum level elevated (> 360 mmol/l, microscopic uric acid crystals)	CCP and rheumatoid factor are negative, inflammatory parameters are elevated in hemogram	CCP and rheumatoid factor are negative, inflammatory parameters are elevated in hemogram
<b>Radiological findings</b>	Periosteal bone neoplasm (occurs only in the late stage)	Erosion and osteopenia (reduction of bone density)	Erosions and discontinuities of the joint surface	Osteosclerosis, hyperostosis, MRI: bone marrow edema	Scleroses

**Table 1** Possible differential diagnoses of psoriatic arthritis [4, 7, 8, 23]

op changes in the nails (spotted nails), which are referred to as onycholysis and psoriatic onychodystrophy (Fig. 2). The changes affect the nail matrix as well as the nail bed [3]. The functional connection of the nails with the distal interphalangeal joints of the fingers, especially the extensor tendons (M. extensor digitorum communis and possibly M. extensor digitalis minimus, among others), may explain the frequent combined occurrence (80%) of joint and nail changes in psoriatic arthritis [2]. Affected nails show red spots, pitting, and scarring, as well as a friable structure of the nail surface. Toenails mostly show a yellowish-orange discoloration of the nail which is called the "oil drop" phenomenon [3]. The cause of these morphological changes is a disturbed keratinization of the nail. Character-

istic of nail psoriasis is subungual (located under the nail) hyperkeratosis, which distinguishes it from onychomycosis [1].

**Enthesitis/daktylitis.** The term "enthesitis" refers to the connective tissue which connects tendons, ligaments, capsules and fascia to bone or muscle tissue. This area is subject to intense mechanical stress. Enthesitis is closely connected with the synovial tissue of the joints. The two form the synovial-enthesal complex ("enthesitis organ") [15]. In case of increased mechanical stress, genetic predisposition and possible bacterial infections, genes are activated that encode proteins responsible for the immune response or tissue compatibility (histocompatibility, HLA-B27). Animal studies suggest that in psoriasis/psoriatic arthritis there is an auto-

immune reaction against proteoglycans and proteins of cartilage fibroblasts as well as against BMP (bone morphogenetic protein). As a result, interleukin-23 (IL-23) is released, which activates immune defense T-cells. These in turn release IL-17, IL-22 and TNF- $\alpha$  (tumor necrosis factor) [15]. Subsequently, an inflammation of the joint structures occurs.

In the case of daktylitis, tendosynovitis, edema of the peritendinous soft tissue („sausage finger“), enthesitis, and less frequently synovitis is present [20]. The pathogenesis of daktylitis is not clearly understood. However, animal studies suggest that IL-17, IL-22, and TNF- $\alpha$  as well as IL-6 and the Dickkopf-related protein 1 may play a role, [2].

**Differential diagnoses.** The differentiation of psoriatic arthritis

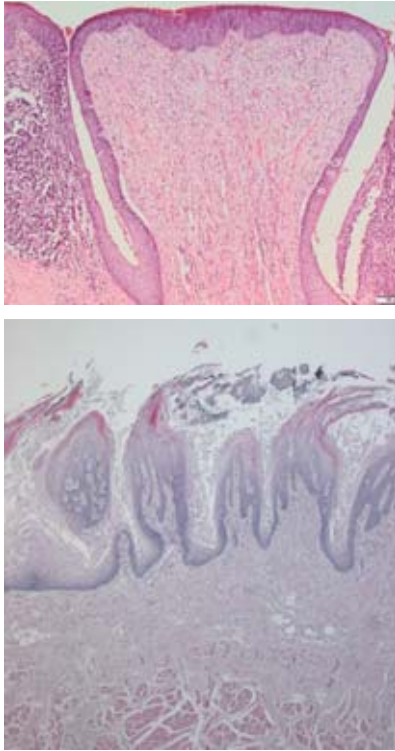
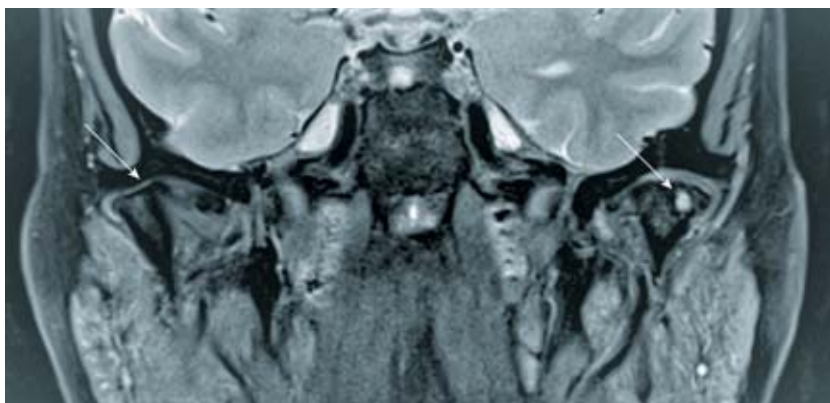


Fig. 4 (a/b): J. Fanghänel, B. Mielhe

**Figure 4** Normal human lingual papillae, HE stain. 4a: Papilla vallata, magnification 100x. 4b: Papillae filiformes, magnification 25x.

of the temporomandibular joint from rheumatoid arthritis with skin lesions [7], temporomandibular joint arthritis associated with SAPHO syndrome [4], gout [8, 22], and arthritides associated with inflammatory bowel diseases such as Crohn's disease [6] is not always straightforward. An overview is provided in Table 1 (Tab. 1).



**Figure 5** Magnetic resonance imaging of a patient with psoriatic arthritis in the axial view. The temporomandibular joint on the left shows new bone formation (arrow); the condyle of the right temporomandibular joint shows bone cysts (arrow). The signal-intensive areas (white) indicate inflammatory zones.

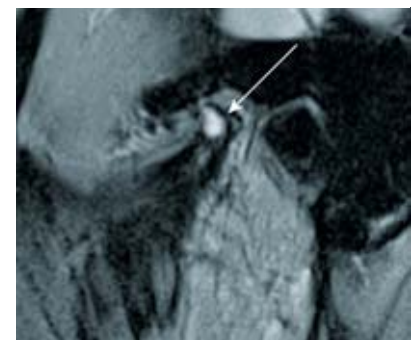
**Imaging.** X-ray imaging shows erosions and irregular bone contours as well as new bone formation. Radiopaque calcifications are found in soft tissues. However, conventional x-rays are not considered the optimal imaging modality for psoriasis. The characteristic soft tissue changes with enthesitis, changes in the joint capsule, focal soft tissue thickening as well as soft tissue and bone edema can be visualized better using magnetic resonance imaging. In cases of dactylitis and enthesitis, ultrasound examinations are also recommended, but these are usually not relevant for dental diagnosis.

Orthopantomograms and magnetic resonance imaging are particularly useful for diagnosing psoriatic arthritis of the temporomandibular joint in dentistry. Erosions, irregular bone contours as well as new bone formation are usually well represented on X-rays. Magnetic resonance imaging also shows active inflammatory processes in the soft tissues as well as cystic changes in the region of the mandibular condyle (Fig. 5, Fig. 6).

**Treatment.** Therapy is primarily administered by rheumatologists and dermatologists. Non-steroidal anti-inflammatory drugs and corticosteroids remain in use as initial treatment for acute symptoms. Since psoriatic arthritis is not a benign disease but is associated with increasing irreparable joint destruction, the early use of immunomodulators is indicated. These include TNF- $\alpha$  inhibitors (e.g., adalimumab,

infliximab, golimumab) and substances that affect interleukins such as IL-12/23 (e.g., guselkumab, tildrakizumab, risankizumab, ustekinumab) or IL-17 (e.g., ixekizumab, bosalumab, secukinumab). Other available therapies are Janus kinase inhibitors (tofacitinib) and PDE4 inhibitors (apremilast). These therapeutic concepts are individually adapted to each patient's case. Corresponding therapy guidelines have been published by professional societies such as the *European League Against Rheumatism* (EULAR) and the *Group for Research and Assessment of Psoriasis and Psoriatic Arthritis* (GRAPPA) [12, 22].

The main objective of the dentist is to check the occlusion and to rebuild it at least provisionally in case of a loss of supporting zones. Adjustable bite splints such as the Michigan splint, in combination with physiotherapy, can help to relax the muscles and to prevent possible loadings of the joints. Splints with an anterior jig are contraindicated. Furthermore, a key responsibility of the dentist is to inquire whether or not patients have already presented themselves to a rheumatologist, so that an immunomodulatory therapy can be initiated promptly. Numerous patients with psoriasis, who have not commenced treatment, or have not been treated adequately, continue to be identified. Since psoriatic arthritis is a progressive destructive joint disease, the timely initiation of immunomodulatory therapy can largely prevent or at least limit joint destruc-



**Figure 6** Magnetic resonance imaging of a patient with psoriatic arthritis in the sagittal view. The signal-intensive areas (white) indicate inflammatory zones in the area of the enthesion organ.

tion. This improves the quality of life of patients considerably [7, 13].

### Statement:

Knowledge of psoriasis/psoriatic arthritis disease is important for the dentist due to the following reasons:

- Patients with psoriasis have multiple comorbidities; these can include cardiovascular disease, hypertension, pulmonary disease, renal and liver disease, diabetes, higher risk of stroke, and eye disease. Such comorbidities can result in complications during routine dental treatment [5].
- Patients with psoriasis/psoriatic arthritis who are undergoing therapy at a rheumatologist or dermatologist usually take immunomodulatory drugs. This may decrease the patient's immune response.
- In nearly half of patients with psoriasis, the temporomandibular joint and the tongue are also affected [7].
- Psoriatic arthritis is a disease which destroys the joint progressively; its early diagnosis and treatment may significantly improve the patient's quality of life [13]. Thus, the dentist has the responsibility of referring patients, who have not been treated previously or who have been inadequately treated, to appropriate specialists such as rheumatologists or dermatologists.

### Conflict of interest

The authors declare that there are no conflicts of interest as defined by the guidelines of the International Committee of Medical Journal Editors.

### References

- Alves NC, Moreira T, Malvino LD et al.: Onychomycosis in psoriatic patients with nail disorders. Aetiological agents and immunosuppressive therapy. *Dermatol Res Pract* 2020; 7209518
- Bagel J, Schwartzman S: Enthesitis and dactylitis in psoriatic disease. A guide for dermatologists. *Am J Clin Dermatol* 2018; 19: 839–852
- Bardazzi F, Starace M, Bruni F et al.: Nail Psoriasis. An updated review and expert opinion on available treatments, including biologics. *Acta Derm Venereol* 2019; 99: 516–523
- Behr M, Fanghänel J, Proff P, Reichert TE (Hrsg): Chronisch nichtbakterielle Osteomyelitis (CNO) des Kieferknochens im Rahmen des übergeordneten SAPHO-Syndroms. Dt. Ärzteverlag, Köln 2020, 39–42
- Brooks JK: Psoriasis. A review of systemic comorbidities and dental management considerations. *Quintessence Int* 2018; 49: 209–217
- Büttner R, Meier J: Chronisch entzündliche Darmerkrankungen, Colitis ulcerosa, Morbus Crohn. In: Behr M, Fanghänel J, Hautmann M, Proff P, Reichert TE (Hrsg): *Medizin für Zahnmediziner*. Dt. Ärzteverlag, Köln 2020, 269–272
- Coates LC, Helliwell PS: Psoriatic arthritis. State of the art review. *Clin Med (Lond)* 2017; 17: 65–70
- Ehrenstein B: Gicht, Urikopathie, Arthritis urica. In: Behr M, Fanghänel J, Hautmann M, Proff P, Reichert TE (Hrsg): *Medizin für Zahnmediziner*. Dt. Ärzteverlag, Köln 2020, 439–442
- Espinoza LR: The history of psoriatic arthritis (PsA). From Moll and Wright to pathway-specific therapy. *Curr Rheumatol Rep* 2018; 20: 58
- Gelfand JM, Dommasch ED, Shin DB et al.: The risk of stroke in patients with psoriasis. *J Invest Dermatol* 2009; 129: 2411–2418
- Gogălniceanu D, Trandafir V, Chiriac R et al.: Temporomandibular joint ankylosis. A possible complication in juvenile psoriatic rheumatism. *Rev Med Chir Soc Med Nat Iasi* 2005; 109: 652–659
- Gossec L, Coates LC, Wit M de et al.: Management of psoriatic arthritis in 2016. A comparison of EULAR and GRAPPA recommendations. *Nat Rev Rheumatol* 2016; 12: 743–750
- Haroon M, Gallagher P, Fitz Gerald O: Diagnostic delay of more than 6 months contributes to poor radiographic and functional outcome in psoriatic arthritis. *Ann Rheum Dis* 2015; 74: 1045–1050
- Hornstein OP (Hrsg): *Erkrankungen des Mundes. Ein interdisziplinäres Handbuch und Atlas*. Kohlhammer, Stuttgart, Berlin, Köln 1996
- Kehl AS, Corr M, Weisman MH: Review. Enthesitis: new insights into pathogenesis, diagnostic modalities, and treatment. *Arthritis Rheumatol* 2016; 68: 312–322
- Kilic B, Dogan U, Parlak AH et al.: Ocular findings in patients with psoriasis. *Int J Dermatol* 2013; 52: 554–559
- Ogdie A, Weiss P: The epidemiology of psoriatic arthritis. *Rheum Dis Clin North Am* 2015; 41: 545–568
- Picciani BLS, Domingos TA, Teixeira-Souza T et al.: Geographic tongue and psoriasis. Clinical, histopathological, immunohistochemical and genetic correlation – a literature review. *Ann Bras Dermatol* 2016; 91: 410–421
- Pschyrembel: *Klinisches Wörterbuch. Psoriasis-Arthritis*. 268 Aufl. De Gruyter, Berlin, Boston 2020, 1451–1452
- Sakkas LI, Alexiou I, Simopoulou T et al.: Enthesitis in psoriatic arthritis. *Semin Arthritis Rheum* 2013; 43: 325–334
- Saleem MD, Kesty C, Feldman SR: Relative versus absolute risk of comorbidities in patients with psoriasis. *J Am Acad Dermatol* 2017; 76: 531–537
- Singh JA, Guyatt G, Ogdie A et al.: American College of Rheumatology/ National Psoriasis Foundation Guideline for the Treatment of Psoriatic Arthritis. *Arthritis Rheumatol* 2019; 71: 5–32
- Sudoł-Szopińska I, Afonso PD, Jacobson JA et al.: Imaging of gout. Findings and pitfalls. A pictorial review. *Acta Reumatol Port* 2020; 45: 20–25
- Takeshita J, Grewal S, Langan SM et al.: Psoriasis and comorbid diseases. Epidemiology. *J Am Acad Dermatol* 2017; 76: 377–390
- Takeshita J, Grewal S, Langan SM et al.: Psoriasis and comorbid diseases. Implications for management. *J Am Acad Dermatol* 2017; 76: 393–403
- Ungprasert P, Srivali N, Kittanamongkolchai W: Risk of Parkinson's disease among patients with psoriasis. A systematic review and meta-analysis. *Indian J Dermatol* 2016; 61: 152–156
- Veale DJ, Fearon U: The pathogenesis of psoriatic arthritis. *Lancet* 2018; 391: 2273–2284
- Vena GA, Vestita M, Cassano N: Psoriasis and cardiovascular disease. *Dermatol Ther* 2010; 23: 144–151



Photo: UKR

**PROF. DR. MED. DENT.  
MICHAEL BEHR**

University of Regensburg  
Faculty of Medicine  
Franz-Josef-Strauß-Allee 11  
93053 Regensburg

michael.behr@klinik.uni-regensburg.de

Christine Mirzakhania, Joachim Esken, Magdalena Schlegel, Guido Heydecke

# Treatment of the edentulous mandible with a fixed bridge supported by 4 mm short implants in the molar region – a case report

**Introduction:** In implant therapy of the edentulous mandible, the decision of implant position is often determined by the need for bone augmentation in the molar region. Bone augmentation requires an extra surgery and thus presents higher risks and costs. In addition, the prosthetic treatment modality of fixed versus removable prosthesis is dependent on implant position. Usually, treatment decision is made in favor of lower costs, less risks and higher patient comfort, which often results in choosing interforaminal implants and removable overdentures. Extra short implants allow for fixed implant supported bridges in the edentulous jaw. Furthermore, in patients with advanced bone loss, pre-treatment with complex bone augmentation is not necessary.

**Material & methods:** This report describes the treatment protocol for a fixed implant-supported prosthesis in the edentulous mandible based on a patient case. Implant therapy was performed without bone augmentation procedures, and instead 4 mm short implants were inserted in the molar and 10 mm long implants were inserted in the canine region with diameters of 4.1 mm. After implant exposure in a second-stage surgery, a fixed prosthesis with CAD/CAM-fabricated framework and full porcelain veneer was cemented on individualized titanium abutments.

**Results:** The described treatment with a fixed prosthesis supported by extra short implants in the molar, and regular long implants in the canine region resulted in full rehabilitation of masticatory function in the edentulous jaw. From the patient's perspective the achieved rehabilitation is comparable to a status with own teeth and leads to an improvement in quality of life.

**Conclusion:** A straight forward implant placement without prior bone augmentation reduces the overall treatment time. In addition, more patients with advanced bone loss in the molar region of the lower jaw may benefit from the presented treatment protocol. From the perspective of the patient treated, the major improvement of chewing ability and the fixed character of the prosthesis made an immense positive impact.

**Keywords:** advanced bone loss; edentulous mandible; fixed bridge; short implants

University Medical Center Hamburg-Eppendorf, Department of Prosthetic Dentistry, Center for Dental and Oral Medicine, Martinistr. 52, 20246 Hamburg: Dr. Christine Mirzakhania (corresponding author), Joachim Esken, Dr. Magdalena Schlegel, Prof. Dr. Guido Heydecke

**Citation:** Mirzakhania C, Esken J, Schlegel M, Heydecke G: Treatment of the edentulous mandible with a fixed bridge supported by 4 mm short implants in the molar region – a case report. Dtsch Zahnärztl Z Int 2022; 4: 94–99

**Peer-reviewed article:** submitted: 26.02.2021, revised version accepted: 02.02.2022

**DOI.org/10.53180/dzz-int.2022.0011**



## Introduction

Tooth loss and the corresponding oral rehabilitation are one of the major issues in health care service. Treatment options for tooth loss largely differ in costs, risks, and benefits for the patient. Implant treatment is a valuable option that minimizes risks and biological costs with survival rates of 95% after up to 10 years [10, 12].

Because the edentulous mandible in particular often provides insufficient bone volume, implant therapy is commonly combined with bone augmentation procedures. The latter is accompanied by additional invasive surgery, higher incidences of complications such as infections and loss of grafting materials, longer treatment time and higher costs.

Concepts with tilted implants to avoid bone augmentation procedures have been developed. For this, Malo and colleagues introduced the "All-on-4™ concept" (Nobel Biocare, Gothenburg, Sweden), where 4 implants are placed interforaminally, of which the distal implants are inserted tilted, the anterior implants axially. A fixed or removable prosthesis is fitted with 12 teeth replaced. In a 2015 retrospective case series, Malo et al. found an "... implant survival estimate of 95,4% after 7 years using the patient as the unit of analysis" [13]. In their systematic review on the All-on-4™ treatment, Patzelt et al. reported 99% survival rate for implants in the mandible after 36 months. However, authors concluded, that these results were highly biased, one of the reasons being that 69% of studies were conducted by a small group of experienced clinicians specialized in all-on-4. Also, study design and patient selection were detected as bias factors. Authors recommend further research with RCTs to gain reliable long-term data on survival and success for this procedure [14].

Another solution to avoid complex bone augmentation is the insertion of implants with reduced length to allow more patients to benefit from implant treatment with higher patient comfort. Implants with a length of 4 mm are the shortest currently available.

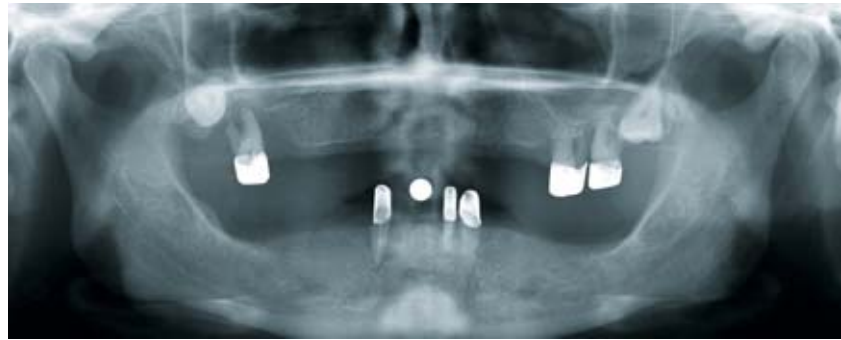

Figure 1 Pre-treatment standard radiograph

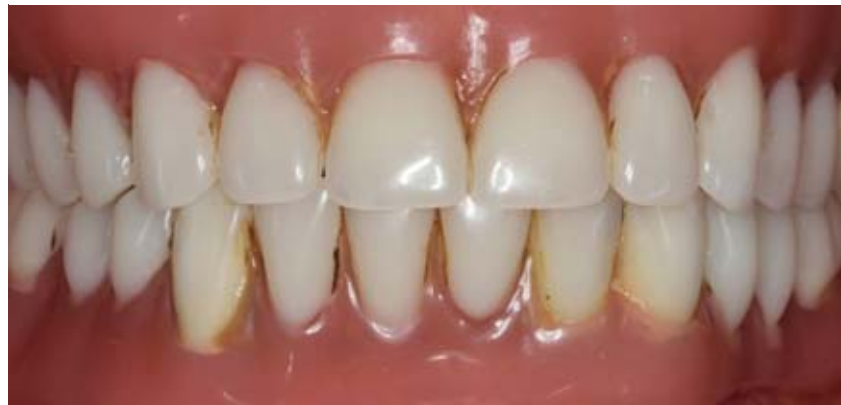

Figure 2 Pre-treatment clinical situation

Knowledge about biomechanics of dental implants has progressed and implant materials, surfaces and design have evolved accordingly over time. This leads to overcoming the dogma of achieving higher stability with long and wide implants [15]. Also, results of current studies appear to show promising evidence for the use of 4 mm short implants. Varying treatment protocols for the use of extra short implants in the mandible have been described.

Fabris and Anitua reported treatment protocols using extra short implants in combination with vertical bone augmentation placed in patients with shortened dental arches. After healing, implants were provided with splinted fixed crowns. Fabris used 4 mm short implants, whereas Anitua inserted 5.5 and 6.5 mm short implants [1, 7]. In a multicenter study, Slotte et al. treated patients with unilateral or bilateral tooth loss and inserted three to four 4 mm short implants without bone augmentation procedures, and splinted them with a bridge [17]. Calvo-Guirado et al. treated eden-

tulous patients and placed 6 implants, 2 implants of 10 mm length in the interforaminal area and 4 posterior implants with 4 mm length, without bone augmentation. A temporary prosthesis was inserted supported by provisional implants, and 90 days after implant surgery a screw-retained fixed prosthesis was fitted [4].

In the literature, survival rates for 4 mm short implants ranged from 92,2% after 5 years when inserted in free-end situations and splinted [17] to 97,5% after 1 year in edentulous mandibles in conjunction with four 4 mm short implants in the molar region and 2 interforaminal implants with regular length and a fixed prosthesis [4]. Comparable survival rates of implants of 4 mm and 8 mm length, the latter placed after 2-stage procedures with bone augmentation, were reported in a RCT by Rokn et al. [16]. In a split mouth design, 11 patients received 25 implants with 4 mm and 22 implants with 8 mm. In this case, survival rates for both implant lengths after 1 year were 100%. A statistically significant dif-

Implant position	Screw torque (Ncm)	RFA implant insertion (exposure) mesial (ISQ)	RFA implant insertion (exposure) buccal (ISQ)
36	25	72 (80)	53 (67)
33	35	72 (78)	62 (79)
43	30	68 (81)	58 (82)
46	35	74 (74)	67 (69)

**Table 1** Screw torque, RFA at implant insertion and RFA at implant exposure (in brackets)

ference in complication rates between procedures of 4-mm and 8-mm implants was observed; the sites with bone augmentation as pre-treatment and 8-mm implants showed complications such as membrane exposures and paresthesia, whereas the 4-mm-implant sites did not [16]. Felice et al. found similar survival rates after 1 year for 1–3 splinted 4 mm short and >8.5 mm long implants in premolar and molar sites [8]. The aforementioned studies showed comparable implant survival rates between 4 mm short and >8 mm long implants, whereas a 2016 systematic review concluded that implants shorter than 8 mm present a greater risk for failure [11].

In this case report, a treatment protocol is introduced for the edentulous mandible with a metal-ceramic fixed dental prosthesis supported by two 4 mm short implants in the region of the first molars and two 10 mm, regular long implants in the canine region.

### Materials and methods

**General medical history:** The 48 year old female patient presented herself at the dental hospital in 2018. Except for an allergy to egg protein and penicillin, the patient was healthy and a non-smoker and also she reported no complaints concerning mandibular joints.

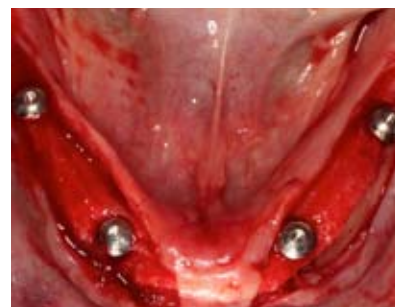**Special medical history:** The patient initially presented with upper and lower removable overdentures supported by 6 teeth (16, 26, 27, 33, 32, 43). The patient requested for better retention of the dentures and improved aesthetics. The fitting of new conventional dentures did not correspond to the patient's wishes

and she asked for information about the option of implant therapy.

**Diagnostic findings:** The extraoral findings showed no pathology. Intraoral findings revealed upper and lower telescopic overdentures at 16, 26, 27, 33, 32, 43 with poor prognosis. All remaining teeth presented with attachment loss of >75%, mobility grade II–III, horizontal and vertical bone loss with furcation involvement and advanced caries (Figure 1 and 2).

**Diagnosis:** Partially edentulous upper and lower jaws, supplied with insufficient partial removable dental prostheses retained with telescopic crowns.

**Therapy:** After obtaining panoramic radiography, the patient was informed about poor prognosis of the remaining teeth 16, 26, 27, 33, 32, 43. The teeth were subsequently extracted and the partial dentures were altered to full upper and lower dentures. After pre-treatment, the radiographic report was discussed with the patient to agree on a suitable treatment plan. The patient rejected conventional dentures. Due to advanced loss in bone height in the premolar and molar region, implant therapy in this area would have required an autologous bone grafting procedure prior to augmentation. To avoid bone augmentation, removable dental prostheses retained by 2 interforaminal implants with Locator® attachments (Zest Dental Solutions, Escondido, California, USA) or placement of 4 interforaminal implants and a bar-retained overdenture were discussed. As a treatment alternative, the patient was informed about participation in an ongoing prospective clinical study. Within this trial, patients were to receive a fixed dental



**Figure 3** Implant surgery lower jaw

prosthesis supported by 2 extra short 4 mm implants in the region of the first molar and 2 regular 10 mm long implants in the canine region (“Prospective clinical study of Straumann Roxolid/SLActive short implants in edentulous mandible”, approved by Ethics committee of Hamburg, study no. PV 4805).

After the patient decided to participate in the study, impressions of the upper and lower jaw were taken, followed by a bite registration and fitting of the set-up for backward planning. The set-up was then transferred to a template with radio-opaque teeth, which the patient inserted during Cone Beam Computed Tomography (CBCT) for image guidance of implant placement. Implant surgery was planned using a computer software (coDiagnostix®, Dental Wings Inc., Montreal (QC), Canada) to ensure correct positioning and axis of the implants and of the tooth to be replaced. Tissue-level titanium-zirconium alloy implants with a length of 4 mm and a diameter of 4.1 mm were selected for positions 36 and 46, and implants with a length of 10 mm and a diameter of 4.1 mm were selected for positions 33 and 43 (Straumann® Standard Plus Implants (SLActive®), Straumann USA LLC, Andover, USA). Afterwards the template was altered to a surgical template. The template was used during the procedure to determine the correct implant position according to the prosthetic requirements.

On the day of the surgery, the patient received antibiotic prophylaxis one hour prior to treatment (Clindamycin 600 mg). Implants were placed in healed sites and in a 2-stage surgery. The surgical procedure for

implant placement was carried out in accordance to Straumann protocols. Local anesthesia was achieved by alveolar nerve block anesthesia. A mucoperiosteal flap with midline incision on the alveolar crest was performed from the molar region to the midline on both sides of the lower jaw. First, two 10-mm implant holes were drilled in the position of the canines, the template was temporarily fixed by these holes, and then the 4-mm short implant holes were drilled. Then all implants were inserted manually (Figure 3). All implants achieved primary stability. Additionally, Resonance Frequency Analysis measurements (RFA) were performed (Table 1).

Closure screws were inserted and sutures were placed for covered healing. After surgical procedures, a radiograph was obtained to verify implant positions (Figure 4). The lower denture served as interim prosthesis and was adapted. Generous clearance around the implants was established to ensure that there was no pressure affecting the healing of the implants. Post OP pain medication was administered (NSAID, Ibuprofen 400 mg), which was limited to 3 dosages a day every 6 hours for a maximum of 3 consecutive days. Also, a rinsing protocol with antiseptic mouthwash twice daily for 7 days was prescribed (Chlorhexamed Forte, alcohol-free 0,2%, GlaxoSmithKline Consumer Healthcare GmbH & Co. KG, Munich, Germany). The patient was instructed to exclusively consume soft foods while the implant healed.

After 3 months of healing without loading implant exposure proceedings took place. Since there was

less than 3 mm of attached gingiva around implants 36 and 46, a free gingival graft (FGT) was placed in the molar region. During surgery, RFA was measured again (Table 1). The patient was asked not to insert the lower prosthesis for one week to allow the grafts to heal. The soft tissue was left to heal for 6 weeks.

Impression for final restoration was performed using polyether (Impregum™, 3M Deutschland GmbH, Neuss, Germany) with custom-made open trays (Figure 5), followed by bite registration and refitting of the set-up. Titanium abutments were then tried in first. Subsequently, a CAD/CAM-fabricated, milled bridge framework made of a non-precious metal alloy from 36 to 46 was inserted. After full porcelain veneering in the dental laboratory, the fixed dental prosthesis was cemented using provisional cement (Temp Bond™ NE, KerrHawe, SA, Bioggio, Switzerland) (Figure 6, 7 and 8).

In the maxilla, an implant-supported bar denture was placed on 4 implants (in regions 16, 14, 24, 26) and 2 separate CAD/CAM-fabricated milled titanium bars (Atlantis™ Isus bars, Dentsply IH GmbH, Germany) with semi-precision attachments (Preci-Horix and Preci-Vertex attachments, Ceka© & Preciline©, Switzerland) (Figure 8). At the end of the prosthetic treatment, the patient was thoroughly instructed in proper oral hygiene and followed up after 2 weeks and then every 4 months.

### Discussion:

The presented treatment offers different extensive advantages to patients

with edentulous mandibles and advanced bone loss. No bone augmentation procedure is needed, and due to the straightforward implant insertion, the treatment provides higher patient comfort.

The surgical risk associated with implant placement in non-augmented sites with 4 mm short implants is lower than that associated with placement of regular long implants in augmented sites, where postoperative complications, morbidity, and also bone loss occur more frequently than in non-augmented sites [6]. Additionally, a fixed construction is linked to higher quality of life compared to removable dentures [3]. Even though the observation period regarding the survival of 4 mm short implants is short and the variety of treatment protocols does not allow a transfer of these results to our treatment protocol, the splinting of 4 implants with a full arch bridge, the survival rates are nevertheless promising.

Mechanical or biological complications related to mandibular distortion and the splinted bridge on 4 implants are not foreseeable. To date, no evidence of clinical relevance of a relationship between mandibular distortion and implant loss or prosthetic failure has been found. It is suggested that mandibular distortion causes micromovement at the bone-implant interface, which could lead to fibrous encapsulation instead of osseointegration of dental implants [5]. In our case, the fixed prosthesis was cemented to the individual abutments with provisional cement to avoid possible consequences of loading the bone-implant interface, as decementing the prosthe-

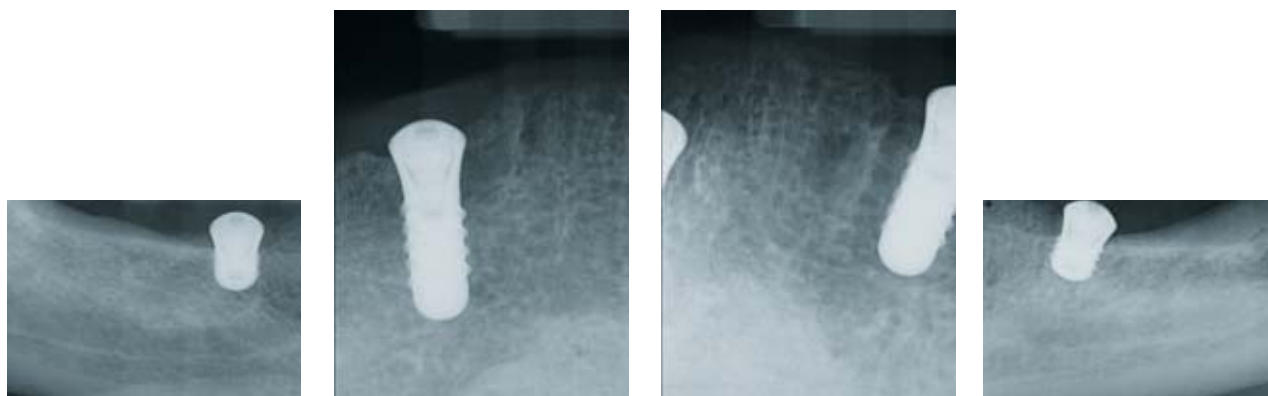


Figure 4a-d Radiographs after implant surgery, lower jaw

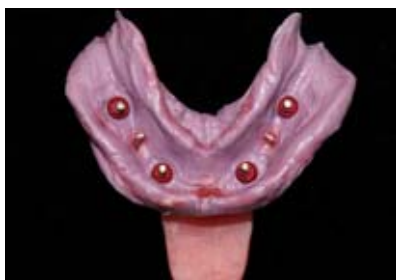

Figure 5 Lower jaw, impression

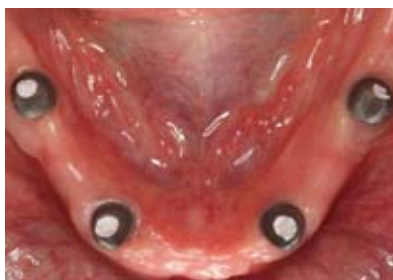

Figure 6 Lower jaw, abutments

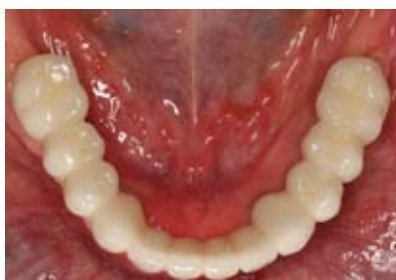

Figure 7 Lower jaw, fixed bridge

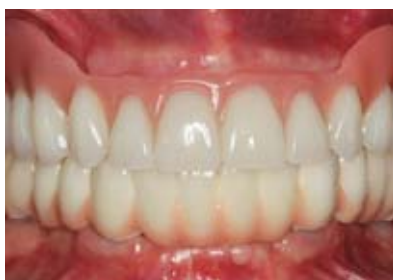

Figure 8 Intraoral overview

sis can prevent overloading of the implants. Crown margins were positioned supra- or epigingival to allow for full removal of cement residue.

Yet, the prognosis of a full-arch mandibular fixed prosthesis on 4 implants, with 2 of them being 4 mm short, is not predictable. Full-arch fixed dental prosthesis in the mandible on 4 implants with a conventional length of 10 mm or longer and 10–12 replaced units were classified to appearing successful in a systematic review [9]. It is unclear whether this assumption can be applied to our treatment protocol with 4 mm short implants in the molar region. In case of implant loss of only one implant, the inserted fixed prosthesis has to be removed. This would lead to further treatment and higher costs for patients. Then, a removable prosthesis could be more forward-looking in terms of anticipated implant loss.

One risk for the successful realization of the prescribed treatment could be the provisional phase from implant surgery to insertion of final prosthesis. In this case, the conventional prosthesis served as provisional restoration. Relining of the denture base after implant and exposure surgeries and establishing generous clearance around the implants cannot be regarded as a safe and predictable approach. Due to horizontal

movement of the denture on the mucosa and the yielding of the mucosa from vertical pressure, uncontrollable and destructive forces can possibly be transferred to the implants. To insert provisional implants and an implant-retained provisional prosthesis such as described by Calvo-Guirado [4] offers more safety. Nevertheless, additional costs for provisional implants and provisional prosthesis are a downside to this procedure.

In the edentulous mandible with advanced bone loss, the placement of 4 mm short implants leads to a shift in the crown-to-implant ratio, which could be another potential risk factor. There seems to be no correlation between bone loss and implant failure with increased crown-to-implant ratio [2]. The implant diameter, the number of splinted implants and the opposing dentition did affect bone loss and implant failure of short implants. A significant difference between antagonistic fixed prosthesis, negatively influencing bone loss around short implants and natural dentition or conventional full dentures was detected [2].

### Conclusion:

By comparing the risks and benefits of the implant treatment of the edentulous mandible with a fixed bridge supported by 4 mm short implants in

the molar and 10 mm long implants in the canine region, results suggest that this procedure is not only straightforward, but also costs less and provides higher patient comfort than alternative treatments. Long-term outcomes of short implants are still lacking and more research according to the number of short implants in a full-arch reconstruction of the edentulous mandible are needed.

### Conflict of interest

The authors declare that there is no conflict of interest within the meaning of the guidelines of the International Committee of Medical Journal Editors.

This case report originated from a study that was financially supported by Straumann GmbH.

### References

1. Anitua E, Alkhraisat MH, Orive G: Novel technique for the treatment of the severely atrophied posterior mandible. *Int J Oral Maxillofac Implants.* 2013; 28: 1338–1346. doi: 1310.11607/jomi.13137
2. Anitua E, Alkhraisat MH, Pinas L, Begona L, Orive G: Implant survival and crestal bone loss around extra-short implants supporting a fixed denture: the effect of crown height space, crown-to-implant ratio, and offset placement of the prosthesis. *Int J Oral Maxillofac Implants.* 2014; 29: 682–689. doi: 610.11607/jomi.13404
3. Brennan M, Houston F, O'Sullivan M, O'Connell B: Patient satisfaction and oral health-related quality of life outcomes of implant overdentures and fixed complete dentures. *Int J Oral Maxillofac Implants.* 2010; 25: 791–800
4. Calvo-Guirado JL, Lopez Torres JA, Dard M, Javed F, Perez-Albacete Martinez C, Mate Sanchez de Val JE: Evaluation of extrashort 4-mm implants in mandibular edentulous patients with reduced bone height in comparison with standard implants: a 12-month results. *Clin Oral Implants Res.* 2016; 27: 867–874. doi: 810.1111/clr.12704. Epub 12015 Oct 12703
5. Choi AH, Conway RC, Taraschi V, Ben-Nissan B: Biomechanics and functional distortion of the human mandible. *J Investig Clin Dent.* 2015; 6: 241–251. doi: 210.1111/jicd.12112. Epub 12014 Jul 12117

6. Esposito M, Buti J, Barausse C, Gasparro R, Sammartino G, Felice P: Short implants versus longer implants in vertically augmented atrophic mandibles: A systematic review of randomised controlled trials with a 5-year post-loading follow-up. *Int J Oral Implantol* (New Malden) 2019; 12: 267–280
7. Fabris V, Manfro R, Reginato VF, Bacchi A: Rehabilitation of a severely resorbed posterior mandible with 4-mm extra-short implants and guided bone regeneration: case report with 3-year follow-up. *Int J Oral Maxillofac Implants*. 2018; 33: e147–e150. doi: 110.11607/jomi.16548
8. Felice P, Checchi L, Barausse C et al.: Posterior jaws rehabilitated with partial prostheses supported by 4.0 x 4.0 mm or by longer implants: one-year post-loading results from a multicenter randomised controlled trial. *Eur J Oral Implantol*. 2016; 9: 35–45
9. Heydecke G, Zwahlen M, Nicol A et al.: What is the optimal number of implants for fixed reconstructions: a systematic review. *Clin Oral Implants Res*. 2012; 23: 217–228. doi: 210.1111/j.1600-0501.2012.02548.x
10. Karoussis IK, Salvi GE, Heitz-Mayfield LJ, Bragger U, Hammerle CH, Lang NP: Long-term implant prognosis in patients with and without a history of chronic periodontitis: a 10-year prospective cohort study of the ITI Dental Implant System. *Clin Oral Implants Res*. 2003; 14: 329–339. doi: 310.1034/j.1600-0501.1000.00934.x
11. Lemos CA, Ferro-Alves ML, Okamoto R, Mendonca MR, Pellizzer EP: Short dental implants versus standard dental implants placed in the posterior jaws: a systematic review and meta-analysis. *J Dent*. 2016; 47: 8–17. 10.1016/j.jdent.2016.1001.1005. Epub 2016 Jan 1019
12. Leonhardt A, Grondahl K, Bergstrom C, Lekholm U: Long-term follow-up of osseointegrated titanium implants using clinical, radiographic and microbiological parameters. *Clin Oral Implants Res*. 2002; 13: 127–132. doi: 110.1034/j.1600-0501.2002.130202.x
13. Malo P, de Araujo Nobre M, Lopes A, Ferro A, Gravito I: All-on-4® treatment concept for the rehabilitation of the completely edentulous mandible: a 7-year clinical and 5-year radiographic retrospective case series with risk assessment for implant failure and marginal bone level. *Clin Implant Dent Relat Res*. 2015; 17: e531–541. doi: 510.1111/cid.12282. Epub 2014 Dec 12223
14. Patzelt SB, Bahat O, Reynolds MA, Strub JR: The all-on-four treatment concept: a systematic review. *Clin Implant Dent Relat Res*. 2014; 16: 836–855. doi: 810.1111/cid.12068. Epub 2013 Apr 12065
15. Renouard F, Nisand D: Impact of implant length and diameter on survival rates. *Clin Oral Implants Res*. 2006; 17: 35–51. doi: 10.1111/j.1600-0501.2006.01349.x
16. Rogn AR, Monzavi A, Panjnoush M, Hashemi HM, Kharazifard MJ, Bitaraf T: Comparing 4-mm dental implants to longer implants placed in augmented bones in the atrophic posterior mandibles: one-year results of a randomized controlled trial. *Clin Implant Dent Relat Res*. 2018; 20: 997–1002. doi: 1010.1111/cid.12672. Epub 2018 Oct 12611
17. Slotte C, Gronningsaeter A, Halmoy AM et al.: Four-millimeter-long posterior-mandible implants: 5-year outcomes of a prospective multicenter study. *Clin Implant Dent Relat Res*. 2015; 17: e385–395. doi: 310.1111/cid.12252. Epub 2014 Jul 12217



Photo: C. Mirzakhanian

**DR. MED. DENT.**  
**CHRISTINE MIRZAKHANIAN M.SC.**  
University Medical Center  
Hamburg-Eppendorf  
Department of Prosthetic Dentistry  
Center for Dental and Oral Medicine  
Martinistr. 52, 20246 Hamburg  
c.mirzakhanian@uke.de

Dominik Groß

# Popular and loyal to the regime: The life and work of CVDZ President Wilhelm Herrenknecht

**Introduction:** In 1926 Wilhelm Herrenknecht succeeded Otto Walkhoff as president of the CVDZ (today: DGZMK). His fame, however, remained well below that of his predecessor. Accordingly, today's knowledge of Herrenknecht's professional work is limited. His relationship to National Socialism has also hardly been discussed. The present contribution takes these gaps in research as an opportunity to provide a synoptic reconstruction of Herrenknecht's life and work, with special emphasis on his role in the "Third Reich".

**Material and methods:** The study is based on archival records from Berlin and Freiburg i. Br., Herrenknecht's published oeuvre and the memoirs of his assistant Erwin Neu. In addition, a comprehensive evaluation of secondary literature on the history of the Freiburg dental clinic and on Herrenknecht himself was carried out.

**Results:** Herrenknecht was a practically versed university teacher and specialist politician who strove for balance but left hardly any traces in scientific terms. However, the permanent establishment of the Freiburg Dental Institute can be attributed to him.

During the "Third Reich" Herrenknecht became a member of the NSDAP. According to sources, he was consistently loyal to the regime.

**Discussion and conclusion:** Herrenknecht's CVDZ presidency (1926–1928) can be classified as a prototypical interim presidency between the "Walkhoff era" (1906–1926) and the "Euler era" (1928–1954). He did not reach the importance of the two colleagues, neither in terms of professional policy nor in scientific terms.

During the Nazi era, Herrenknecht acted as a typical follower. Because of his loyalty to the line, he contributed to the acceptance of the Nazi regime – albeit without appearing as a fervent National Socialist.

**Keywords:** CVDZ; chloroethyl narcosis; Freiburg im Breisgau; National Socialism; NSDAP

## Introduction

Wilhelm Herrenknecht served as president of the “Central-Verein Deutscher Zahnärzte” (Central Association of German Dentists, CVDZ; today: “Deutsche Gesellschaft für Zahn-, Mund- und Kieferheilkunde”, DGZMK) from 1926 to 1928. But unlike some presidents before him – such as Otto Walkhoff (1860–1934) [14, 20] – or after him – such as Hermann Euler (1878–1961) [6, 15, 18, 25, 26, 57] or Ewald Harndt (1901–1996) [19] –, Herrenknecht did not gain a prominent place in the history of the profession. Little is known about his relationship to National Socialism either. Although Wolfgang Röder presented a dissertation in 1970 that was dedicated to the dentist’s life and work, he made no reference to Herrenknecht’s role in the “Third Reich” or to his party-political orientation [53]; the same applies to most of the other secondary literature on the Freiburg university teacher available to date.

In view of this research gap, the present essay provides a concise bioergography of Herrenknecht, taking into account his (party) political stance in the “Third Reich”.

## Material and methods

This paper is largely based on files from the Federal Archives in Berlin and the University Archives in Freiburg in Breisgau. In addition, the surviving memoirs of the Jewish Herrenknecht student Erwin Neu (1908–2002) as well as all of Herrenknecht’s published scientific papers were evaluated. Furthermore, a comprehensive analysis of the secondary literature published to date on the history of the Freiburg Dental Clinic and on Herrenknecht as a person was carried out, including laudations, necrologies and lexical contributions, as well as individual journal articles and medicohistorical dissertations.

## Results and discussion

### 1. Wilhelm Herrenknecht – life and career

Wilhelm Herrenknecht (Fig. 1, [48]) was born on May 19, 1865 in Nonnenweier (Baden). The various stages of his life are comparatively well

documented [1, 5, 6, 8, 9, 25, 35, 36, 37, 39, 40, 49, 50, 52, 58, 59]: He was the son of a farmer who later became a “Rheindammmeister” (dike master on the Rhine).

Wilhelm Herrenknecht spent his school years in the Breisgau region, namely in Weisweil, Renzingen and finally in Freiburg, where he passed the Abitur in 1886 at the Berthold-Gymnasium (which still exists today). Wilhelm Herrenknecht was the only one of 4 siblings to complete an academic education: He studied medicine at the universities of Freiburg and Munich, passed the medical examination in July 1891 and subsequently received his medical licence. In the same year he received his doctorate – also in Freiburg – with the 37-page thesis “Beitrag zur Behandlung von carcinomatöser Stricture des Halsteils des Oesophagus” (Contribution to the treatment of carcinomatous stricture of the neck part of the oesophagus) (translated by DG) [10, 28]. In the very year, he took up an assistant post at the Freiburg University Eye Clinic, before becoming assistant physician in the surgical department of the municipal hospital in Karlsruhe in 1892. One year later – in April 1893 – he settled as a general practitioner in Donaueschingen; there he also worked as a doctor for the poor in the community.

In the same year, Herrenknecht married Mathilde de Beauclair on December 2. In the following years, his wife, who came from South America, gave birth to 7 children. After 6 years, however, Herrenknecht decided to give up his country doctor’s practice and move away with the family because his wife “could not tolerate the harsh climate in Donaueschingen” [53] and “fell so seriously ill that only a change of location promised her relief and healing” [9]. In this situation of upheaval and new beginnings, Herrenknecht also decided “on the advice of his friend Prof. [Oskar] Römer” to change disciplines and study dentistry [10, 37]. Oskar Römer (1866–1952) was already working as a private lecturer in dentistry in Strasbourg at that time.

So, in 1899 Herrenknecht moved with his family to the city of Frei-



With kind printing permission from Wolfgang Wehl

**Figure 1** Portrait of Wilhelm Herrenknecht

burg, which was known for its warm, temperate climate. However, he completed his (brief) additional studies in dentistry at the University of Strasbourg, 90 km away, with his friend Römer. The very next year (1900) Herrenknecht passed the dental examination in Strasbourg and obtained his licence to practise dentistry. He then went on a 6-month study trip with stays at the dental institutes of the universities of Berlin, Breslau and Prague.

In 1901 Herrenknecht opened a private practice in Freiburg as a “specialist for oral and dental diseases”, which quickly earned him a good reputation. In December 1902, he received an offer from the Medical Faculty of the University of Freiburg to habilitate in dentistry and subsequently take over the management of a dental institute planned there. Herrenknecht had already been known to the Freiburg faculty since his doctorate (1901); he was also friends with the chair of surgery there, Paul Kraske (1851–1930). It had also been Kraske who had made contact with Herrenknecht in this situation and had conveyed the faculty’s offer to him. In fact, Herrenknecht submitted his habilitation thesis to the University of Freiburg in the summer of 1903. It was entitled “Über Äthylchlorid und Äthylchloridnarkose – Für Ärzte und Zahnärzte” (On Ethyl Chloride and

Term of office	Name	NSDAP Membership	Life data
1906–1926	Otto Walkhoff	+	1860–1934
<b>1926–1928</b>	<b>Wilhelm Herrenknecht</b>	+	<b>1865–1941</b>
1928–45, 1949–54	Hermann Euler	+	1878–1961
1954–1957	Hermann Wolf	+	1889–1978
1957–1965	Ewald Harndt	+	1901–1996
1965–1969	Gerhard Steinhardt	+	1904–1995
1969–1971	Eugen Fröhlich	+	1910–1971
1972–1977	Rudolf Naujoks	–	1919–2004
1977–1981	Werner Ketterl	+	1925–2010

**Table 1** The presidents of the CVDZ (from 1933: DGZMK) who experienced the “Third Reich” as adults and their party-political orientation

Ethyl Chloride Anaesthesia – For Doctors and Dentists) [10, 29]. In July 1903 he gave his trial lecture (“On the caries of the teeth”) and in August he was appointed Privatdozent [39]. In the winter semester of 1903/04, Herrenknecht held his first regular lectures in Freiburg, and in December 1903 he was commissioned to establish a dental institute. It opened its doors in April 1904 with Herrenknecht as director. In August 1909, Herrenknecht was then appointed personal associate professor in Freiburg. In the following years, the institute was successively expanded, and in October 1912 Herrenknecht became a scheduled associate professorship. After the beginning of the First World War, he worked as a medical advisor to the XIV Army Corps; until the end of the war, he was mainly responsible for the care of oral and maxillofacial patients in Freiburg. In 1922 Herrenknecht was finally promoted to personal full professor in Freiburg. He held this position until his retirement in March 1934. Herrenknecht remained resident in Freiburg in the following period, but – unlike other emeritus colleagues of the time – he did not open a private practice, as can be

seen from contemporary dentists’ directories [45–47].

Wilhelm Herrenknecht died of intestinal gangrene based on enteric arteriosclerosis in 1941 after being ill for 8 weeks. His wife survived him by 11 years.

Herrenknecht was, among others, the father of the internist Mathilde (Till) Goette, née Herrenknecht (\*1896) and the dentist Margaretha Rosa Alice Treibs, née Herrenknecht (1900–1980). Furthermore, he was the grandfather of Dr. Gerda Beickert, née Goette (\*1929), Karlsruhe, and the great-grandfather of Wolfgang Wehl (\*1953), Professor of Mechatronics and Robotics at Heilbronn University [23].

## 2. Herrenknecht’s scientific and professional significance

Herrenknecht was actually not the first, but already the third teacher of dentistry at the University of Freiburg – however, it was only with him that the permanent establishment of a state dental university institute was achieved [7, 24, 42, 43, 51]. Nevertheless, Herrenknecht followed in big footsteps in Freiburg: in 1891, Carl Röse (1864–1947) was the first dentist to habilitate in dentistry at the University of Freiburg. He, too, had sub-

sequently been involved in founding a dental institute. However, it did not get beyond the status of a provisional institution and did not exist for long: The continuing, glaring underfunding of the provisional institution prompted Röse to apply for leave of absence in 1894/95. In 1896 he left Freiburg for good, without having returned in the meantime. Instead, he carried out important studies on the development of caries and epidemiology at different locations. Röse is the first dentist to be nominated for a Nobel Prize (category physiology/medicine) [24].

Röse was succeeded in 1896 by Otto Bartels (1860–1943) [37]. He became interim head of the dental polyclinic there in the position of “Lector” (Lecturer) and was responsible for dental training. Since he did not possess the *venia legendi*, his lectures were designated as “taking place with the permission of the directorate of the surgical clinic” [37, 42]. But Bartels soon demanded the expansion of the poorly equipped polyclinic into an institute and his appointment as head of this institute. However, he did not succeed in achieving “a clear legal position and in general an undisputed authority” [7]. Rather, he lost the support of the faculty after persistent criticism of his professional qualifications and his (supposedly insufficient) presence in the dental polyclinic. This was also the reason why Herrenknecht was approached in December 1902 in search of a personal alternative [37]. Herrenknecht was considered “a proven colleague in many respects” due to his successful work as a practising doctor for dental and oral diseases [42]. Bartels, however, remained active in the polyclinic until the opening of the aforementioned institute and subsequently ran a practice in Freiburg for many more years.

In 1904, individual items from Bartels’ polyclinic were transferred to the new dental institute, although the majority of the inventory had to be “newly acquired” [37]. Thus, Herrenknecht finally became the first director of a permanent, state-supported university dental institute. Keffer therefore rightly calls him the



actual “father of the Freiburg Dental Institute” [37].

However, the continued existence of the institution was repeatedly threatened. The main problem was the fact that the institute was – and remained – underfunded from the beginning. Since Herrenknecht had acquired some indispensable equipment – purely out of necessity – without a commitment of funds, the deficit added up to 9,250 marks by 1908. The Ministry then informed him “that in future he would be held personally liable for overdrafts” [37].

During the First World War, Herrenknecht had to cope with an enormous number of patients. Yet he did not even have a specific jaw hospital, but only a “treatment centre for the mouth injured”. Frenk commented on this: “The workload that weighed on Prof. Herrenknecht’s shoulders during these four years is clearly demonstrated by the fact that by June 1918, almost 700 wounded with jaw injuries and over 8,000 soldiers received treatment and help in more than 50,000 sessions at the dental polyclinic. These figures do not include a large number of officers and prisoners of war” [9].

In 1924, the closure of the Freiburg Dental Institute and Herrenknecht’s early retirement were considered for financial reasons. However, both were finally averted. This was made possible by a “new financial arrangement”, whereby the institute became less of a burden on the state treasury [9]: Herrenknecht had undertaken to pay all employees from clinic funds in future. In return, “the entire accounting was no longer to be handled by the university treasury, but by the polyclinic itself. Course fees also now fell to it”. In order to improve the revenue situation, an institutional and accounting link was also created with the municipal school dental clinic, which was in a far better financial position [37].

Thus, Herrenknecht succeeded in averting his dismissal – a feat of strength that was certainly appreciated by his colleagues. The Heidelberg colleague and institute director Georg Blessing (1882–1941) [10]



Courtesy of Quintessenz-Verlag

**Figure 2** Herrenknecht in the circle of his fellow board members (1926) (from right: Hermann Euler, Gustav Hesse, Heinrich Blum, Carl-Ulrich Fehr, Wilhelm Herrenknecht, Adolf Scheele) [16]

wrote about Herrenknecht: “He, who is so attached to his work and the fulfilment of his duties, would never have felt happy in his involuntary muse. We are pleased with him that it was possible to overcome the financial difficulties, to maintain his institute and to continue to have him as a teacher and clinic director” [1]. But the situation in Freiburg remained challenging: An “application for a [regular] full professorship in dentistry for Prof. Herrenknecht” submitted by the faculty on 26 November 1930 was rejected by the Ministry of Culture on the grounds that it was not possible to establish “new scheduled professorships” [37]. Thus, Herrenknecht remained a “personal full professor” until the end of his term of office – i.e. a professor with the personal rights, but not the position and salary of a full professor.

After Herrenknecht retired for reasons of age (1934), Fritz Faber (1887–1961) – an ardent National Socialist and member of the Waffen-SS – was appointed as his successor; this happened under pressure from influential National Socialists and against the will of the Freiburg Medical Faculty, which had shortlisted 5 other habilitated dentists [17].

Herrenknecht was a very practice-oriented university teacher who was appreciated by his students. This was expressed, among other things, in his nickname “Papa Herrenknecht” [35]. He was also considered approachable and popular in the contemporary scientific community. Above all, he was perceived as “very balanced” [53]. It was precisely this quality that put him in marked contrast to Otto Walkhoff, who had steered the fortunes of the CVDZ until 1926 and acted in a visibly autocratic manner. This had long since led to distortions in the board of the association. Referring to 1924, Hermann Euler noted: “Schaeffer-Stuckert, Dieck and Cohn had resigned from their positions on the board, partly in connection with previous differences, so that apart from Köhler and Parreidt the old guard was only represented by Walkhoff [...]. He watched all the more closely over the preservation of the old tradition and proposals that could change the internal structure of the Centralverein did not find a sympathetic ear with him” [5, 12]. In the end, continued criticism of his person prompted Walkhoff to resign from office in 1926 after 20 years; Julius Parreidt (1849–1933) [25] also

withdrew. In this situation, Herrenknecht agreed to succeed Walkhoff (cf. Tab. 1 and Fig. 2, [16]). The former immediately tried to conciliate Walkhoff: “Even if, in the opinion of very many members of the association, some of the fights of the last years would have been better left out in the interest of our profession or at least could have been conducted in a different form, this will never keep the Central Association of German Dentists (e.V.) from always gratefully commemorating the services of the two long-standing members of the board, even though Prof. Walkhoff [...] refuses to give thanks in such a hurtful way” [4]. At the 1926 General Assembly, a resolution was passed to honour Walkhoff’s many years of service by establishing a “Walkhoff Foundation” [12, 25].

Since Herrenknecht was very affable as president, it was “generally much regretted when he declined reelection in 1928” [5]. He gave his workload as the reason for the refusal. Now the previous second chairman, Herrmann Euler, was elected as the new president. Euler was to hold this position longer than any other incumbent before or after him: Only with the appointment of Hermann Wolf (1889–1978) [22] in 1954 did the “Euler era” end.

Herrenknecht had succeeded in steering the CVDZ into calmer waters. He was helped in this by a close network of colleagues with whom he maintained friendly relations, including Oskar Römer, Georg Blessing, Ernst Jessen (1859–1933) [10], Hermann Euler and Ottomar Jonas (1885–1956) [10].

In scientific terms, however, Herrenknecht clearly lagged behind earlier presidents of the CVDZ such as Willoughby D. Miller (1853–1907) [13] or the aforementioned Walkhoff. Even among the 9 presidents thematised in this series who experienced the “Third Reich” as adults, he was the only one without significant research contributions. Röder, who in 1970 wrote the only monograph on Herrenknecht to date and sketched him rather uncritically from a historiographical point of view and largely dispensed with shades of grey, also counted him

“not among the great scholars of dentistry” [53]. Herrenknecht’s publications clearly showed “that he was more concerned with the tasks of a practical dentist than with scientific problem points” [9]. It is worth mentioning that Herrenknecht made chloroethylene anaesthesia (already developed in the 19th century) known in dentistry. It was probably against this background that Georg Blessing dedicated the publication “Die Entwicklung der Lokalanästhesie in der Zahnheilkunde” (The Development of Local Anaesthesia in Dentistry) to him on his 60th birthday [2]. In 1910, Herrenknecht was one of the first specialists to point out “that apical foci can develop into a general disease such as rheumatism” [27]. In addition to anaesthesia and chloroethylene anaesthesia [29, 30, 32], his main areas of work were the connections between general medicine and dentistry – especially “focal diseases” – and the subject area of oral and dental hygiene and prophylaxis [31, 33, 34].

In his long career, Herrenknecht published hardly more than 30 articles [53] – thus, also in quantitative terms, he remained clearly behind Walkhoff (over 160 publications), Euler (over 240 publications) or Wolf (over 180 publications). Nevertheless, Herrenknecht produced several academic students who later became professors, such as Walter Adrion (1891–1960) [10], Hermann Becks (1897–1962), Erwin Neu, Curt Scheidt (1901–1964) [10] or Eugen Wannenmacher (1897–1974) [10].

Herrenknecht received the Baden Cross of War Merit in 1916, the Iron Cross II Class on the white-black ribbon in 1917 and the Cross of Honour for War Participants in 1935 for his service in the First World War. His most important professional awards were the honorary doctorate (Dr. med. dent. h.c.) by the University of Freiburg (1920) and his honorary membership in the CVDZ (1930).

### 3. Herrenknecht’s relationship to National Socialism

Like all German universities, the University of Freiburg was brought into line politically after the National So-

cialists came to power; this was accompanied by the disenfranchisement of Jewish lecturers [41, 56].

Herrenknecht behaved in a conformist manner in the “Third Reich” from the very beginning. It is recorded that he dismissed his Jewish assistant and pupil Erwin Neu, hired in 1929, on April 11, 1933 without any attempt at a petition – with reference to a letter from the Ministry of Education, “stating that all Jewish employees are to be dismissed from their posts” [41]. In contrast, Hans Rehm (1903–1967) [10] had at the same time courageously campaigned for Neu’s temporary retention at the Freiburg clinic – although, unlike Herrenknecht, he was not Neu’s superior, so that his petition probably carried less weight. Incidentally, Rehm was to become director of the Freiburg dental clinic himself much later – in 1947.

Both facts – Rehm’s ultimately unsuccessful attempt to intervene on Neu’s behalf and Herrenknecht’s lack of effort – are mentioned by Neu himself in his autobiographical memoirs [44].

Rehm’s advocacy for Neu was not an unusual reaction: Elsewhere, too, “Aryan” superiors tried from 1933 onwards to keep their Jewish assistants in office, at least for a certain time, in the form of such petitions – mostly with specific references to their indispensability for clinical procedures or to their earlier war service as front-line fighters. The best-known example of this is provided by Professor Hermann Schröder, director at the Berlin Dental Institute: He stood up for his Jewish assistant Konrad Lipschitz (1878–1935), who was thus able to remain in office until October 1935 [55]. Fritz Trebitsch (1897–1990) also retained his position at the Berlin Institute until 1935 after an intervention by Schröder [38]. The same applies to his Jewish assistant Fritz Munz (1895–1986) [55].

While Herrenknecht remained inactive in the Causa Neu in 1933, he turned to the Ministry of Culture on his own account in the same year. Specifically, he wanted to obtain a financial promotion at the Freiburg Institute: In a letter at the end of 1933,

Herrenknecht declared his support for the new National Socialist leadership and implied that he had been considered politically dissident in the Weimar Republic. According to Herrenknecht, his political unpopularity had prevented his promotion to full professor in 1930. Specifically, he expressed his gratitude that the National Socialist government had put an end to the previous unsatisfactory conditions. Finally, he asked that the financial disadvantages described be taken into account when determining his pension [59].

At the time of this letter – at the end of 1933 – Herrenknecht had not yet joined the party. In fact, membership was not possible at this stage: The NSDAP had received a veritable flood of applications for membership, especially immediately after the Reichstag elections in March 1933. Since a large proportion of them were thought to be political opportunists – the National Socialists referred to them pejoratively as “Märzgefalle- ne” – the party imposed a membership ban in May 1933. This was only relaxed again in the spring of 1937 and it was at this time that Herrenknecht joined the NSDAP (admission 01.04.1937; no. 4,715,504) [3].

Unlike his successor in office in Freiburg, Fritz Faber [10], Herrenknecht did not make any pro-National Socialist statements to the outside world. Nevertheless, he was obviously politically loyal until the end of his life. This is also evident from the fact that the National Socialist Reich dentist leader Ernst Stuck (1893–1974) personally honoured Herrenknecht with an obituary in 1941, which only happened in individual cases. There he stated: “We lose [...] a professional comrade with constant devotion to his work and a person with high qualities of mind and heart” [58].

## Conclusions

The facts presented lead to the conclusion that Herrenknecht was a typical interim president. This is already evident from the short, only 2-year term of office (1926–1928), while the “Otto Walkhoff era” had previously lasted about 20 years (1906–1926) and the term of office of Herren-

knecht’s successor, Hermann Euler, even spanned the years 1928 to 1954 (with an interruption in the post-war period).

This finding becomes even clearer when one takes a retrospective look at the professional policy achievements that can be attributed to the respective presidents: Walkhoff’s term of office included the establishment of the Abitur (A level) as a prerequisite for studying dentistry (1909) and the introduction of the right to obtain a doctorate in dentistry (1919) – two milestones in the professionalisation process of dentists [11, 14, 20, 21]. Under Euler’s leadership, further significant progress in professional policy was achieved: He not only steered the centralised DGZMK through the “Third Reich”, but also took part in the reconstitution of the DGZMK in 1949 in the post-war period, in the gradual reintegration of the German specialist representatives into the international scientific community and in the solution of dental dualism, i.e. in the abolition of the competing profession of non-academic “Dentisten” and the integration of the already licensed Dentisten into the dental profession. The latter was implemented in 1952 in the Federal Republic of Germany after several years of preparation – with the help of the DGZMK [15, 16, 18, 25, 26].

Herrenknecht’s professional merit merely consisted in pacifying the professional society as the successor to the autocratic Walkhoff and leading it into calmer waters, as well as securing the continued existence of the Freiburg Dental Institute, which was at times in great danger.

In scientific terms, Herrenknecht was not up to the aforementioned colleagues. His publications were more aids for practitioners than pioneering scientific achievements. Nevertheless, he was considered a committed teacher who was popular with his students and aroused the interest of some of his academic pupils in a university career.

Politically, Herrenknecht can be classified as a typical follower. He implemented the repressive anti-Jewish university policy in his area without any signs of resistance and also

showed himself to be politically loyal in other ways. Herrenknecht did not openly appear as an ardent National Socialist; but through his loyalty to the line, he ultimately contributed to the acceptance of the Nazi regime – like many Germans in positions of responsibility.

## Conflict of interest

The author declares that there is no conflict of interest within the meaning of the guidelines of the International Committee of Medical Journal Editors.

## References

1. Blessing G: Wilhelm Herrenknecht. Dtsch. Mschr. Zahnheilk. 1925; 43: 261 f.
2. Blessing G: Die Entwicklung der Lokalanästhesie in der Zahnheilkunde, Dt. Mschr. Zahnheilk. 1925; 43: 262–269
3. BArch R 9361-IX/15250513
4. Dtsch Zahnärztl Wschr 1926; 29: 271
5. Euler H: Wilhelm Herrenknecht zum Gedächtnis. Dtsch Zahnärztl Wschr 1941; 44: 183
6. Euler H: Lebenserinnerungen eines Lehrers der Zahnheilkunde. Hanser, München 1949, 30, 37, 50, 120f., 126, 181
7. Eulner HH: Die Entwicklung der medizinischen Spezialfächer. Enke, Stuttgart 1970. 409f., 683
8. Fischer I (Hrsg.): Biographisches Lexikon der hervorragenden Ärzte der letzten fünfzig Jahre. Band 1. Urban & Schwarzenberg, München 1962, 614
9. Frenk M: Prof. Dr. med. et Dt. med. dent. h.c. Wilhelm Herrenknecht – Ein vergessener Sohn Nonnenweiers. Biographie, In: Frenk M: Riedprofile. Ottenheim 2004, 37–50
10. Friederich W: Die deutschen zahnärztlichen Hochschulgelehrten der Geburtsjahrgänge 1840–1909. Untersuchungen über beruflichen Werdegang, Lebenserwartung und private Neigungen in den verschiedenen Altersgruppen. Diss. med. dent. Berlin 1968, passim
11. Groß D: Die schwierige Professionalisierung der deutschen Zahnärzteschaft (1867–1919). Lang, Frankfurt a.M. 1994, 227–256
12. Groß D: Die “Deutsche Gesellschaft für Zahn-, Mund- und Kieferheilkunde”

- im Spiegel der Geschichte (1859 bis 1999), Quintessenz, Berlin 1999, 85, 108f., 177, 181, 188
13. Groß D: Willoughby Dayton Miller – Erklärer der Karies. Zahnärztl Mitt 2017; 107(18): 108–110
14. Groß D: Otto Walkhoff – Erkämpfer des Dr. med. dent., Zahnärztl Mitt 2017; 107(23–24): 100–102
15. Groß D: Hermann Euler – der entartete DGZMK-Präsident, Zahnärztl Mitt 2018; 108(12): 92f.
16. Groß D: Die Geschichte des Zahnarztberufs in Deutschland. Einflussfaktoren – Begleitumstände – Aktuelle Entwicklungen. Quintessence, Berlin 2019, 114
17. Groß D: Fritz Faber (1887–1961) – zwischen Universität und Waffen-SS. Zahnärztl Mitt 2020; 110(5): 72–74
18. Groß D: Hermann Euler (1878–1961) – Ein Nationalsozialist der leisen Töne, Zahnärztl Mitt 2020; 110(15–16): 66–68
19. Groß D: A complex case: Ewald Harndt (1901–1996) and his relationship to National Socialism, DZZ International 2020; 2(4): 131–141
20. Groß D: "Walkhoff, Otto", In: Neue Deutsche Biographie. 27. Band. Vockeroth – Wettiner, Berlin 2020, 328f.
21. Groß D: Otto Walkhoff (1860–1934) – Model scientist and early National Socialist, DZZ International 2022; 4(2): 77–84
22. Groß D: Lexikon der Zahnärzte und Kieferchirurgen im „Dritten Reich“ und im Nachkriegsdeutschland. Täter, Mitläufer, Oppositionelle, Verfolgte, Unbeteiligte. Band 2. Hentrich & Hentrich, Berlin 2022
23. Groß D: Persönliche Recherchen
24. Groß D, Hansson N: Carl Röse (1864–1947) – The first dentist nominated for the Nobel Prize and his contributions to caries research. Brit Dent J 2020; 229: 54–59
25. Groß D, Schäfer G: Geschichte der DGZMK 1859–2009. Quintessenz, Berlin 2009, 78f., 102, 104, 269f., 274
26. Groß D, Schmidt M, Schwanke E: Zahnärztliche Standesvertreter im "Dritten Reich" und nach 1945 im Spiegel der Lebenserinnerungen von Hermann Euler (1878–1961) und Carl-Heinz Fischer (1909–1997). In: Krischel M, Schmidt M, Groß D (Hrsg.): Medizinische Fachgesellschaften im Nationalsozialismus. Bestandsaufnahme und Perspektiven. Lit, Berlin, Münster 2016, 129–171
27. Heidel CP: Johann Alexander Vogel-sang (1890–1963) und sein Beitrag zur Etablierung der Zahnheilkunde an dem Johannstädter Stadtkrankenhaus und der Medizinischen Akademie Dresden, In: Albrecht DM: Beiträge zur Dresdener Hochschulmedizin (= Schriften der Medizinischen Fakultät Carl Gustav Carus der Technischen Universität Dresden, Neue Folge, 3), Dresden 1999, 95–112, insb. 97
28. Herrenknecht W: Beitrag zur Behandlung von carcinomatöser Stricture des Halsteils des Oesophagus. Diss. med. dent. Freiburg i. Br. 1891
29. Herrenknecht W: Über Äthylchlorid und Äthylchloridnarkose – Für Ärzte und Zahnärzte. Habil. Schrift. Freiburg i. Br. 1903 (1904 publiziert bei Thieme, Leipzig)
30. Herrenknecht W: 3000 Äthylchloridnarkosen. Münch Med Wschr 1907; 54: 2421–2424
31. Herrenknecht W: Zur Prophylaxe der Zahnkaries. Münch Med Wschr 1910; 57: 400–403
32. Herrenknecht W: Über die forensische Bedeutung der Narkosen bei Operationen in der Mundhöhle. Dt Zahnärztl Wschr 1910; 13: 821–823, 897–898
33. Herrenknecht W: Allgemeine und Mundhygiene. Fortschr Zahnheilk 1925; 1: 796–814
34. Herrenknecht W: Mundhygiene. Fortschr Zahnheilk 1926; 2: 668–676, sowie 1927; 3: 678–688, sowie 1928; 4: 736–751 (zus. mit H. Becks), sowie 1929; 5: 715–726, sowie 1930; 6: 664–677, sowie 1931; 7: 716–725, sowie 1932; 8: 659–666 (jeweils zus. mit C. Scheidt)
35. Hoffmann H: Prof. Dr. med. et med. dent. h.c. Herrenknecht. Zahnärztl Mitt 1925; 16: 198
36. Jonas O: Prof. Dr. Herrenknecht. Zahnärztl Rdsch 1941; 50: 472–474
37. Keffer B: Geschichte des zahnärztlichen Universitätsinstitutes in Freiburg. Diss. med. dent. Freiburg 1968, passim
38. Köhn M: Zahnärzte 1933–1945. Berufsverbot, Emigration, Verfolgung (= Reihe Deutsche Vergangenheit, 113). Hentrich, Berlin 1994, 77, 178
39. Kürschners Deutscher Gelehrten-Kalender 1935; 5: 529
40. Maretzky K, Venter R: Geschichte des deutschen Zahnärzte-Standes. Bundeverband der deutschen Zahnärzte, Köln 1974, 137
41. Mattes JB: Demütigung – Vertreibung – Neuanfang: aus Freiburg geflohen in alle Welt, In: Grün B, Hofer HG, Leven KH (Hrsg.): Medizin und Nationalsozialismus. Die Freiburger Medizinische Fakultät und das Klinikum in der Weimarer Republik und im "Dritten Reich". Peter Lang, Frankfurt a. M. 2002, 161–188
42. Nauck ET: Die Anfänge des Zahnheilkunde-Unterrichts an der Universität Freiburg i. Br. Ber Naturf Ges Freiburg i. Br. 1953; 43: 47–73
43. Nauck ET: Die Privatdozenten der Universität Freiburg i. Br. Albert, Freiburg i. Br. 1956, 119
44. Neu E: Erinnerungen von Dr. Erwin Neu (Paris), In: Ruch M: Aus der Heimat verjagt. Zur Geschichte der Familie Neu. Jüdische Schicksale aus Offenburg 1874–1998. Hartung-Gorre, Konstanz 1998, 133–166
45. Ottow EH, Ottow E (Hrsg.): Deutsches Zahnärzte-Buch. 18. Ausgabe. Berlinische Verlagsanstalt, Berlin 1935, Teil C, 406
46. Ottow EH, Ottow E (Hrsg.): Deutsches Zahnärzte-Buch und Zahnärzte-Verzeichnis. 19. Ausgabe des Adreßkalenders der Zahnärzte im Deutschen Reich, in der Freien Stadt Danzig und im Memelland. Berlinische Verlagsanstalt, Berlin 1938, Teil C, 441
47. Ottow EH, Ottow E (Hrsg.): Deutsches Zahnärzte-Buch und Zahnärzte-Verzeichnis. 20. Ausgabe des Adreßkalenders der Zahnärzte im Groß-Deutschen Reich. Berlinische Verlagsanstalt, Berlin 1941, Teil C, 428
48. Privatarchiv Wehl: Portrait Wilhelm Herrenknecht – mit freundlicher Druckgenehmigung von Wolfgang Wehl
49. Reichsärztekammer (RÄK) (o. J.) (Herrenknecht, Wilhelm)
50. Reichsverband: Der Reichsverband der Zahnärzte Deutschlands e. V. gratuliert Herrn Professor Herrenknecht! Zahnärztl Mitt 1925; 16: 197f.
51. Reither W: Geschichte des Zentrums für Zahn-, Mund- und Kieferheilkunde der Universität Freiburg i. Br. Dtsch Zahnärzte-Kal 1986; 45: 151–155
52. Riemer SK: Karl Schuchardt – Leben und Werk. Diss. med. dent. Hamburg 2001, 50–53, 238
53. Röder W: Prof. Dr. med. et. Dr. med. dent. h.c. Wilhelm Herrenknecht (1865–1941). Diss. med. dent. Köln 1970, passim
54. Schaeffer-Stuckert F: Geschichte des Zentral-Vereins Deutscher Zahnärzte: 1909–1934. Verfasst im Auftrag der Deutschen Gesellschaft für Zahn-, Mund- u. Kieferheilkunde zum 75jährigen Bestehen des Vereins. Lehmann, München 1934, passim
55. Schröck-Schmidt P: Leuchtende Sterne der Medizin. Zur verdrängten Geschichte jüdischer Zahnoperateure, Zahnärzte und Professoren. Wissenschaftliches Zentrum, Leipzig 1996, 82–85
56. Seidler E, Leven KH: Die Medizinische Fakultät der Albert-Ludwigs-Universität Freiburg im Breisgau: Grundlagen und

Entwicklungen (= Freiburger Beiträge zur Wissenschafts- und Universitätsgeschichte, Neue Folge, 2) Alber, Berlin 2007, 267, 359, 388, 427f., 440, 458, 497f., 772, 786

57. Staehle HJ, Eckart WU: Hermann Euler als Repräsentant der zahnärztlichen Wissenschaft während der NS-Zeit. Dtsch Zahnärztl Z 2005; 60: 677–694

58. Stuck E: Prof. Herrenknecht gestorben. Zahnärztl Mitt 1941; 32: 129

59. Universitätsarchiv (UA) Freiburg, R 24 1341 (Personalakte Wilhelm Herrenknecht) – zitiert nach Keffer [1968], 66



Photo: University Hospital Aachen

---

**UNIV.-PROF. DR. MED. DR. MED.  
DENT. DR. PHIL. D. GROSS**  
RWTH Aachen University  
Medical School,  
MTI II, Wendlingweg 2,  
D-52074 Aachen  
dgross@ukaachen.de

**DZZ International  
German Dental Journal International**

**Publishing Institution**

International Journal of the German Society of Dentistry and Oral Medicine/Deutsche Gesellschaft für Zahn-, Mund- und Kieferheilkunde e.V. (Zentralverein, gegr. 1859), Liesegangstr. 17a, 40211 Düsseldorf, Phone: +49 211 610198-0, Fax: +49 211 610198-11

**Affiliations**

German Society of Periodontology (DG PARO)  
German Society for Prosthetic Dentistry and Biomaterials  
German Association for Conservative Dentistry  
German Society of Craniomandibular Function and Disorders in the DGZMK  
German Society of Paediatric Dentistry  
German Academy of Oral and Maxillofacial Surgery  
German Association of Dento-Maxillo-Facial Radiology (GSDOM)  
German Academy of Dental Ergonomics  
Group of Basic Science in Dentistry

**Editors**

Prof. Dr. Guido Heydecke  
Editor in Chief | DZZ International  
Chairman Department of Prosthetic Dentistry  
University Medical Center Hamburg-Eppendorf  
Martinistraße 52 | 20246 Hamburg  
Phone +49 (0) 40 7410-53261  
Fax +49 (0) 40 7410-54096

Prof. Dr. Werner Geurtsen  
Editor | DZZ International  
Elly-Beinhorn-Str. 28  
30559 Hannover

**Associate Editors**

Prof. Nico H.J. Creugers, D.D.S., PH.D., Nijmegen/NL  
Prof. Dr. Henrik Dommisch, Berlin/GER  
Prof. Dr. Marco Rainer Kesting, Erlangen/GER  
Prof. Dr. Torsten Mundt, Greifswald/GER  
Prof. Dr. Falk Schwendicke, Berlin/GER  
Univ.-Prof. Dr. med. dent. Michael Wolf, M.Sc., Aachen/GER

**Publisher**

Deutscher Ärzteverlag GmbH  
Dieselstr. 2, 50859 Köln;  
Postfach 40 02 65, 50832 Köln  
Phone: +49 2234 7011-0; Fax: +49 2234 7011-6508  
www.aerzteverlag.de

**Executive Board**

Jürgen Führer, Patric Tongbhoyai

**Product Management**

Carmen Ohlendorf, Phone: +49 02234 7011-357;  
Fax: +49 2234 7011-6357;  
ohlendorf@aerzteverlag.de

**Editorial Office**

Susanne Neumann, Phone: +49 2234 7011-219,  
neumann.extern@aerzteverlag.de  
Thomas Volmert, Phone: +49 2234 7011-253,  
volmert@aerzteverlag.de

**Frequency**

6 times a year

**Layout**

Larissa Arts

**Account**

Deutsche Apotheker- und Ärztebank, Köln,  
Kto. 010 1107410 (BLZ 370 606 15),  
IBAN: DE 2830 0606 0101 0110 7410,  
BIC: DAAEDED3,  
Postbank Köln 192 50–506 (BLZ 370 100 50),  
IBAN: DE 8337 0100 5000 1925 0506,  
BIC: PBNKDEFF

**4. Volume**

ISSN 2627-3489

**Copyright and Right of Publication**

Diese Publikation ist urheberrechtlich geschützt und alle Rechte sind vorbehalten. Diese Publikation darf daher außerhalb der Grenzen des Urheberrechts ohne vorherige, ausdrückliche, schriftliche Genehmigung des Verlages weder vervielfältigt noch übersetzt oder transferiert werden, sei es im Ganzen, in Teilen oder irgendeiner anderen Form. Die Wiedergabe von Warenbezeichnungen, Handelsnamen und sonstigen Kennzeichen in dieser Publikation berechtigt nicht zu der Annahme, dass diese frei benutzt werden dürfen. Zumeist handelt es sich dabei um Marken und sonstige geschützte Kennzeichen, auch wenn sie nicht als solche bezeichnet sind.

**Disclaimer**

Die in dieser Publikation dargestellten Inhalte dienen ausschließlich der allgemeinen Information und stellen weder Empfehlungen noch Handlungsanleitungen dar. Sie dürfen daher keinesfalls ungeprüft zur Grundlage eigenständiger Behandlungen oder medizinischer Eingriffe gemacht werden. Der Benutzer ist ausdrücklich aufgefordert, selbst die in dieser Publikation dargestellten Inhalte zu prüfen, um sich in eigener Verantwortung zu versichern, dass diese vollständig sind sowie dem aktuellen Erkenntnisstand entsprechen und im Zweifel einen Spezialisten zu konsultieren. Verfasser und Verlag übernehmen keinerlei Verantwortung oder Gewährleistung für die Vollständigkeit, Richtigkeit und Aktualität der in dieser Publikation dargestellten Informationen. Haftungsansprüche, die sich auf Schäden materieller oder ideeller Art beziehen, die durch die Nutzung oder Nichtnutzung der in dieser Publikation dargestellten Inhalte oder Teilen davon verursacht werden, sind ausgeschlossen, sofern kein nachweislich vorsätzliches oder grob fahrlässiges Verschulden von Verfasser und/oder Verlag vorliegt.

© Copyright by Deutscher Ärzteverlag GmbH, Köln