

INTRODUCTION & OBJECTIVE

The initial surgical treatment of children with cleft lip and palate often triggers centripetal deviation of the perimaxillary tissues that lead to the appearance of malocclusion. The most frequent is posterior crossbite due to maxillary constriction. The aim of this study was to evaluate the efficacy of the Quad-helix appliance in maxillary expansion of patients with cleft lip and palate.

MATERIALS AND METHODS

Sample size:
 N = 20 patients with cleft lip and palate (CLP)

12 male and 8 female, mean age 12.85 years ± 1,78
 40 cone-beam computed tomography (CBCT) scans: 20 preexpansion (T0) and 20 postexpansion (T1)

Inclusion criteria: Patients in the mixed dentition with lip and palate repair, maxillary arch constriction and a **need for maxillary expansion before the alveolar bone graft procedure.**

Exclusion criteria: Syndromic patients and previous orthodontic treatment

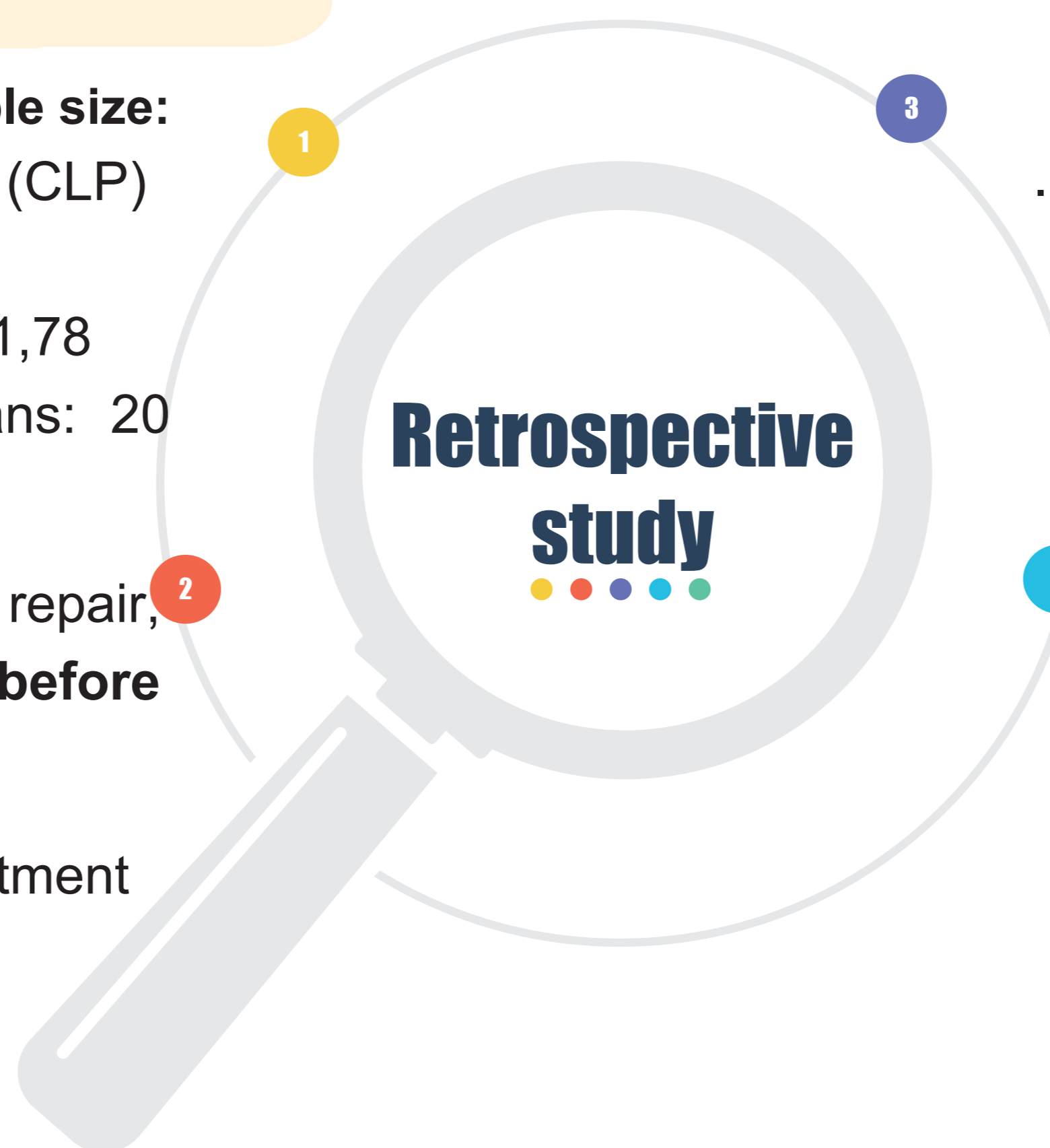


Image analysis: CBCT images were obtained with iCatvision New Generation System (Imaging Sciences International, Hatfield, PA), and the DICOM files were assessed by using the Anatomage's Invivo5 3D imaging software

A landmark-based method was used to superimpose the images using the zygomatic buttress as reference.

Statistical analysis: Shapiro-Wilk and paired t-tests (t-Student and Wilcoxon) at a 5% level of significance were used. The mean, standard deviation and 95% confidence interval were calculated to evaluate changes over time. The data obtained from all measurements were processed with SPSS software (version 24.0, IBM-SPSS Corporation, EUA).

| Abbreviation | Landmark description |
|--------------|--|
| MaxW | Maxillary skeletal base width: Linear distance of bilateral points on the jugal process at the intersection of the outline of the tuberosity of the maxilla and the zygomatic buttress. |
| ACW | Alveolar crest width: Linear distance of the lowest point of the alveolar process from the right to the left side |
| CEJ | Cemento-enamel junction: Linear distance from the right to the left side of the area of union of the cementum and enamel at the cervical region of the tooth |
| AW | Arch width: Linear distance between the most prominent lateral point on the buccal cusp of the right and left upper first molar, first premolar or first deciduous molars |

Table 1 - Dental and skeletal parameters.

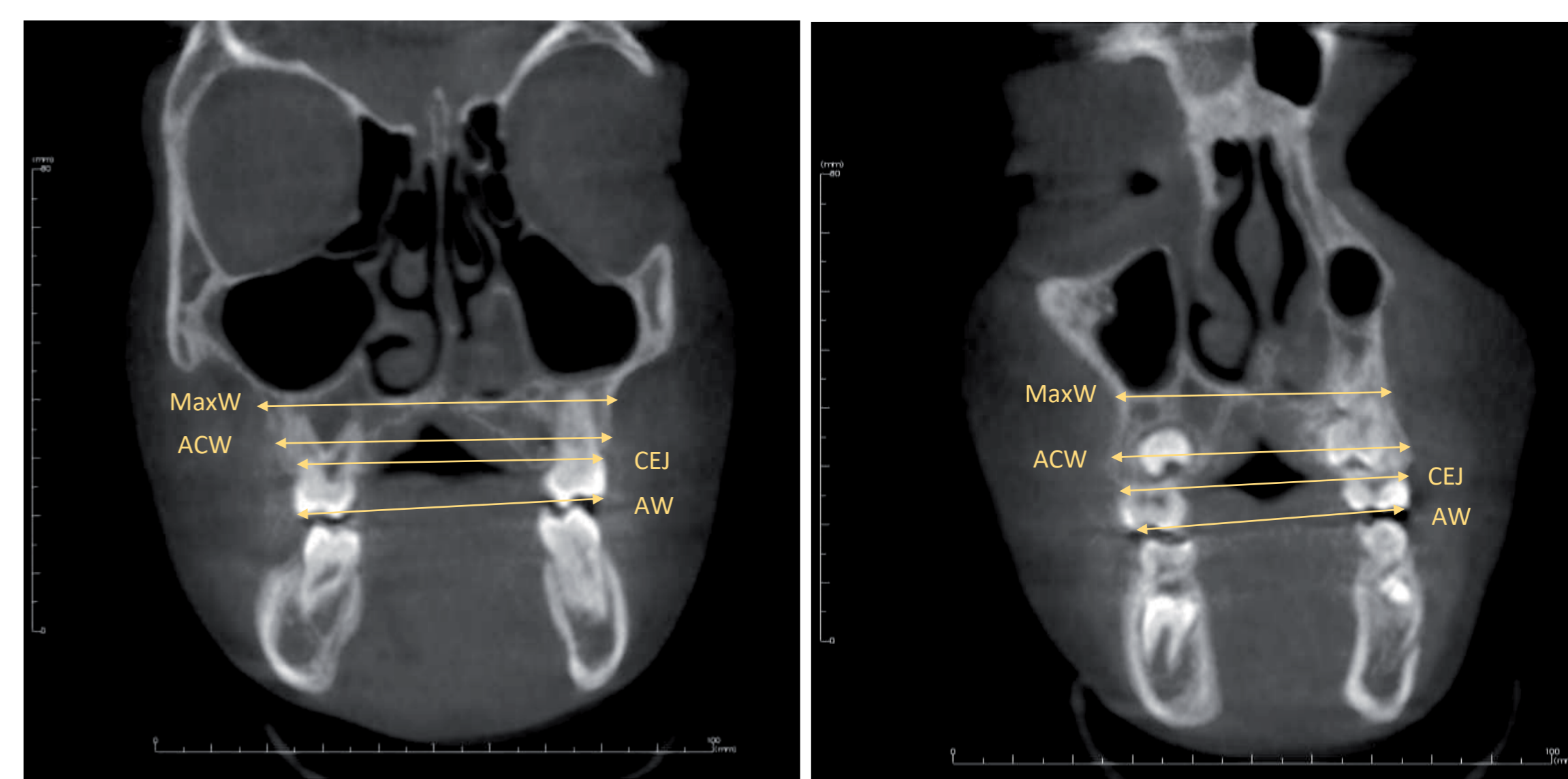


Fig. 1 - Landmarks with the measurements analysed in the coronal view.

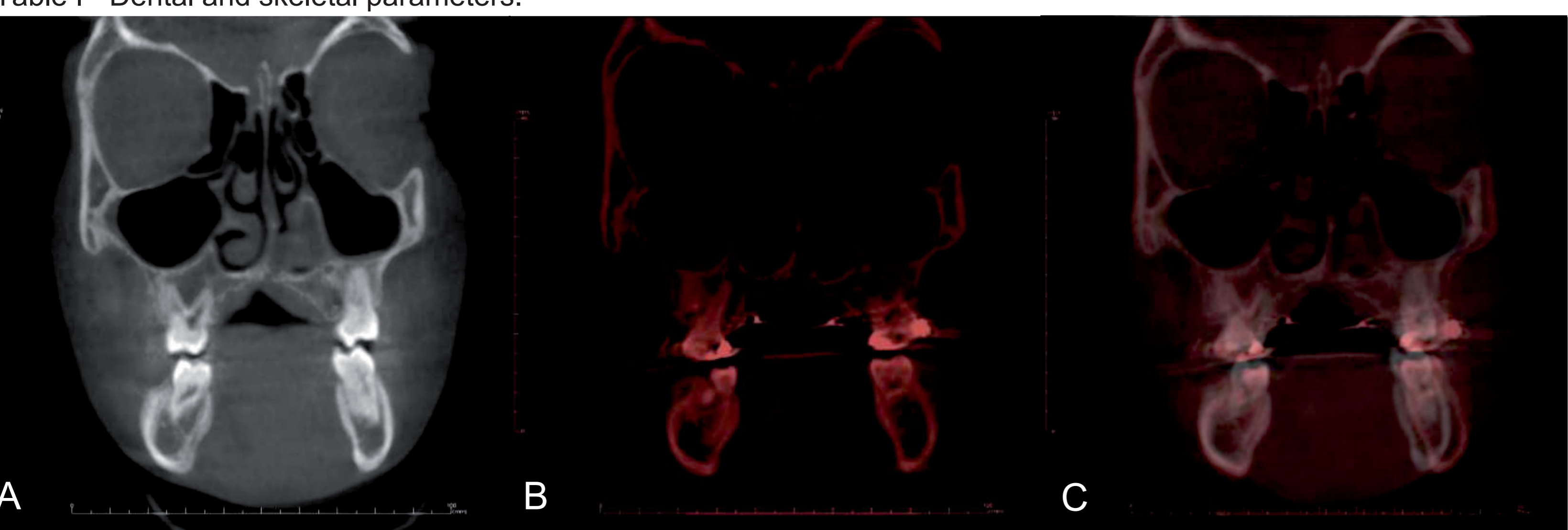


Fig. 2a - Coronal view of the posterior teeth pre-expansion CBCT

Fig. 2b - Post-expansion CBCT

Fig. 2c - Superimposition of the two CBCT

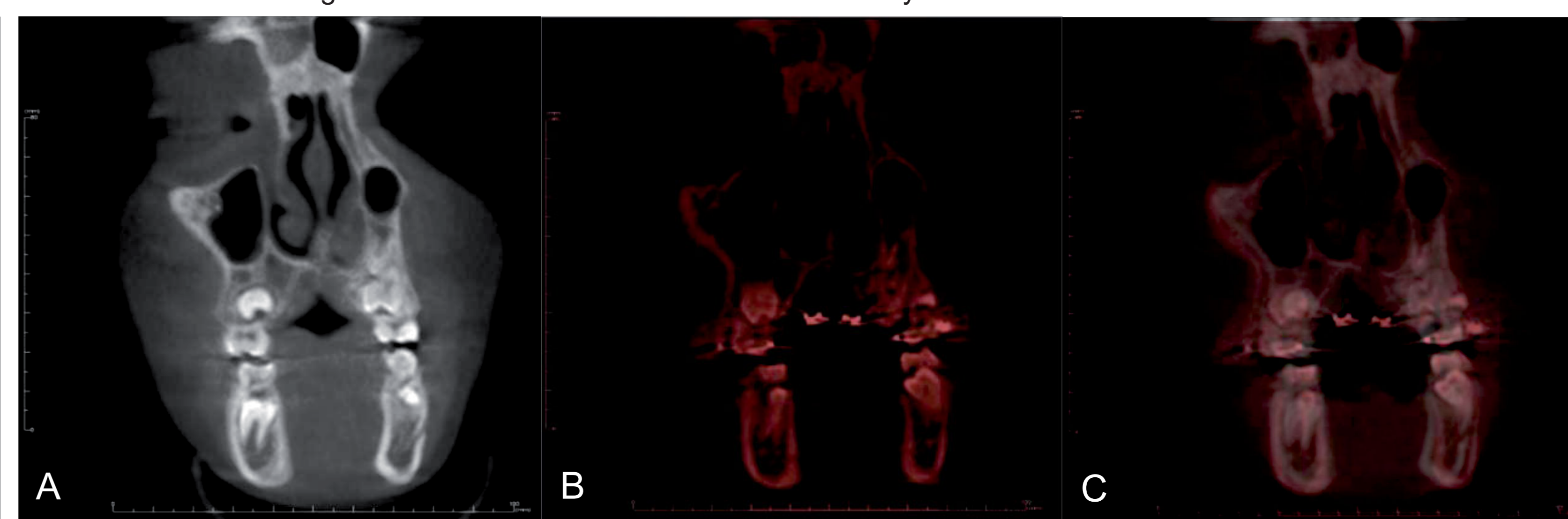

Fig. 3a - Coronal view of the anterior teeth pre-expansion CBCT

Fig. 3b - Post-expansion CBCT

Fig. 3c - Superimposition of the two CBCT

RESULTS

Statistical analysis revealed a statistically significant increase ($p < 0.01$) in both groups (posterior and anterior), after expansion in all of the measurements. Regarding skeletal changes, marginal bone had a mean increase of **4.1mm** in the **posterior**, and a **4.8mm** mean increase in the **anterior** regions. Maxillary width increased **3,7mm** in the **posterior** and **2,2mm** in the **anterior** regions. Dento-alveolar measurements showed a greater transversal change after expansion in both groups of approximately **5 mm**. Dental tipping was evaluated by calculating the difference between CEJ and AW at T0 and T1 and showed a mean difference of **1.4mm** in the **posterior** and **2,7mm** in the **anterior** (Figures 4-11.).

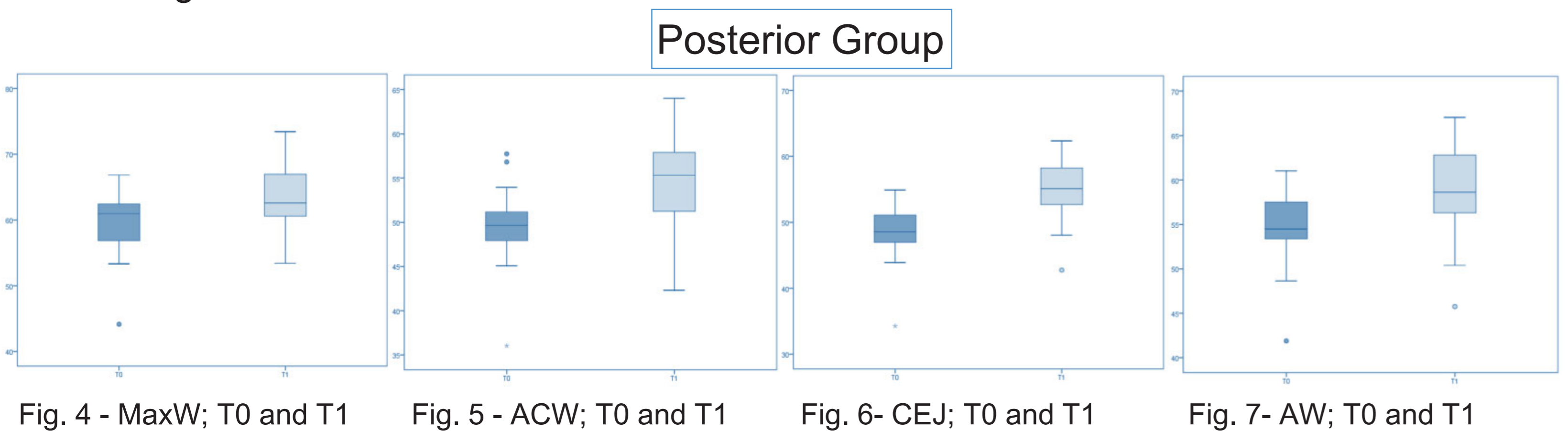


Fig. 4 - MaxW; T0 and T1

Fig. 5 - ACW; T0 and T1

Fig. 6 - CEJ; T0 and T1

Fig. 7 - AW; T0 and T1

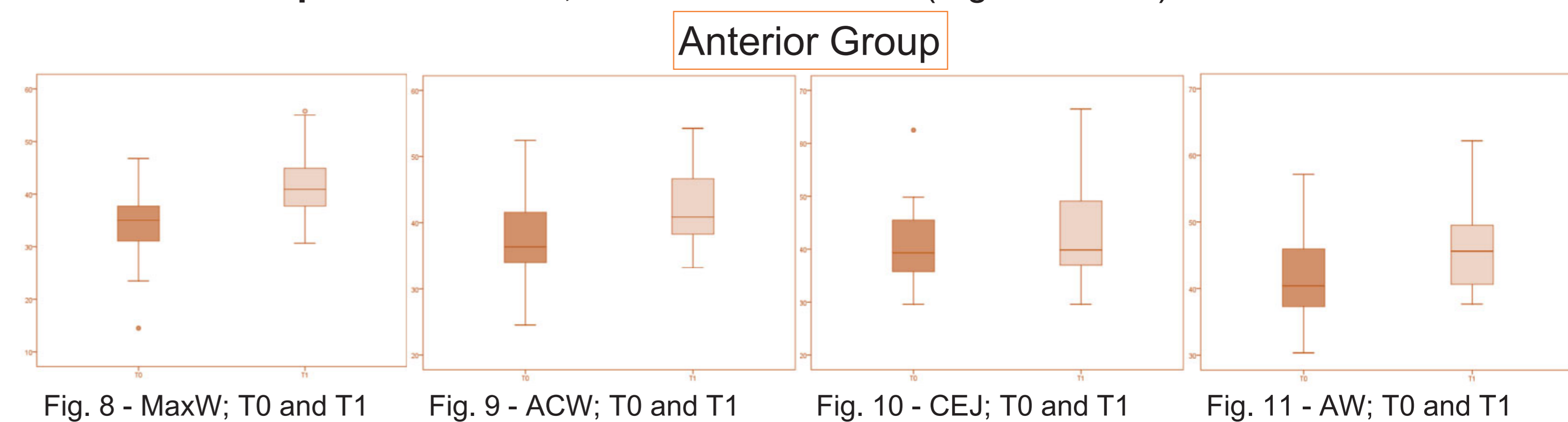


Fig. 8 - MaxW; T0 and T1

Fig. 9 - ACW; T0 and T1

Fig. 10 - CEJ; T0 and T1

Fig. 11 - AW; T0 and T1

DISCUSSION

In this study, we evaluated the dento-skeletal responses in the transversal plane after expansion with the Quad-helix appliance by using high-resolution CBCT. The total expansion achieved with this appliance can be divided into 3 parts: skeletal expansion, alveolar expansion and dental tipping. This appliance showed a greater expansion in the anterior maxillary region in comparison with the posterior region. Expansion also produced buccal tipping of molars, premolars and deciduous first molars. It was observed that the Quad-helix produces greater dento-alveolar expansion than skeletal, probably due to the resistance of scar tissue existing in the cleft region.

CONCLUSION

In this study it was possible to verify the efficacy of Quad-helix in transversal maxillary expansion in children with cleft lip and palate. It was also possible to verify a greater efficacy in the anterior region than in the posterior region of the maxilla with a bigger dento-alveolar component.

CLINICAL IMPLICATIONS

The use of Quad-helix appliance in mixed dentition is an effective treatment in the correction of maxillary transverse discrepancy of patients with cleft lip and palate, especially when most of the maxillary collapse is in the anterior region.