

# Evaluation of risk parameters in bone regeneration using a customized titanium mesh – results of a clinical study

HILDEBRANDT H<sup>1</sup>, KAEMMERER PW<sup>2</sup>, SEILER M<sup>3</sup>, HARTMANN A<sup>3</sup>

<sup>1</sup>Praxis Am Mühlenviertel, Bremen, Germany

<sup>2</sup>University Medical Center of the Johannes Gutenberg University Mainz, Department of Oral- and Maxillofacial Surgery, Germany

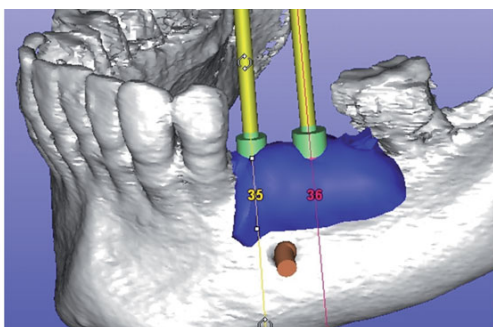
<sup>3</sup>Praxis Dr. Seiler und Kollegen, Filderstadt, Germany

## Objectives

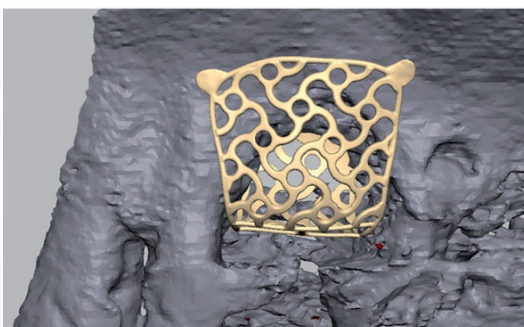
Management of defects of the jaw bone and consecutive implant placement is still a challenge in daily practice. Patient-specific titanium meshes are a promising tool to create optimal patient care. With this study, the surgical protocol was analyzed for feasibility and evaluated to identify risk factors concerning soft tissue healing according to a new classification for mesh exposure.

## Methods

65 patients with 70 grafting procedures were included. The treatment of the defects based on a customized titanium mesh (Yxoss CBR®, ReOSS, Filderstadt, Germany) and A®-/I®-PRF. The meshes were installed by using a mixture of autogenous bone graft and Bio-Oss® (Geistlich, Wolhusen, Switzerland) particles in a 1:1 ratio. Implant placement (Camlog Screw Line®, Camlog, Wimsheim, Germany) was performed either simultaneously with mesh insertion or after a healing period of 4-6 months combined with the removal of the mesh (Fig.1 and 2).

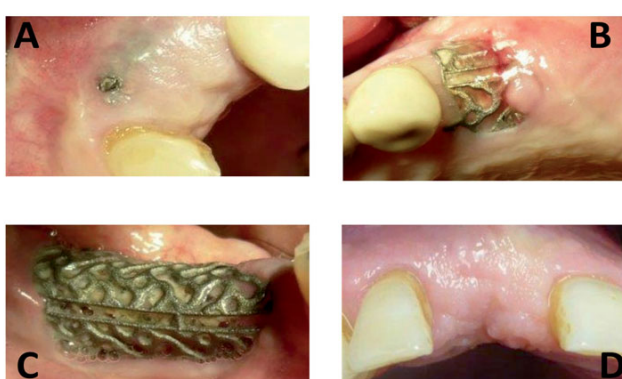

**Fig.1:** Prosthetic backward planning and definition of augmentation volume



**Fig.2:** Design-example. The inner contour of the mesh represents the desired augmentation volume.

Patients and augmentation sites were analyzed focussing on defect regions, defect and mesh sizes, healing difficulties and potential risk factors such as tobacco abuse, periodontitis, tissue phenotype ("A"= thin and fragile phenotype, "B"= thick phenotype), additional sinus floor augmentation procedures and diabetes mellitus. Exposures of the meshes and grafting outcome were analyzed according to a novel classification (Fig.3).



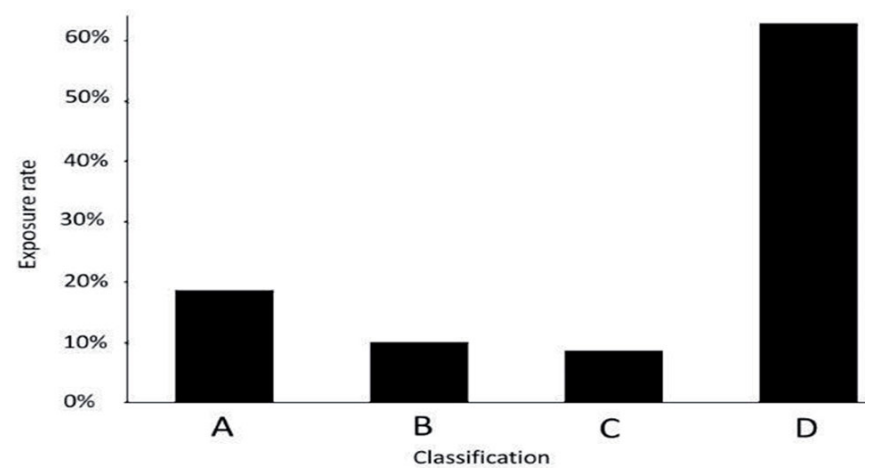
**Fig. 3:** Classification of mesh exposure:  
(A) = Punctual exposure of the titanium mesh  
(B) = One tooth width (premolar)  
(C) = Complete exposure  
(D) = No exposure.

Subtypes revealed loss of augmentation material and infection parameters.

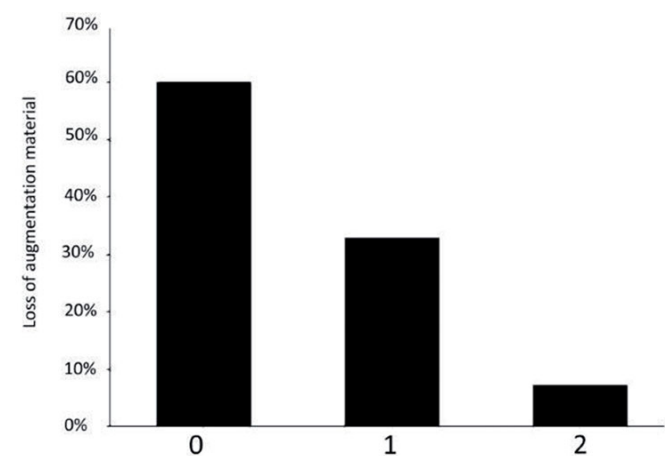
Subtypes	
With loss of augmentation material	
1)	partial
2)	complete loss (regrafting necessary)
With infection parameters	
3)	swelling
4)	pus
5)	fistula

## Results

In 37,1% of cases, exposures (A-D) of the meshes were documented which were significantly associated with loss of grafted material ( $p < 0.001$ ) (Fig.4 and 5).



**Fig.4:** Exposure (A-D): In total, 37,1 % exposures of the meshes occurred. According to classification, 13 meshes (18,6 %) were Group "A", "B" was found in 7 cases (10 %) and Group "C" consisted of 6 cases (8,6 %). No exposure ("D") was seen in 44 cases (62,9 %).



**Fig.5:** Subtypes: Loss of augmentation material (0-2) Subtypes revealed a partial loss of augmentation material ("1") in 23 cases (32,9 %), 5 cases (7,1 %) of complete loss ("2") and a stable and profound augmentation site ("0") in 42 cases (60 %; figure 8). After re-grafting procedures and the respective healing time, implant placement was not possible in two cases (2,9 %).

Tobacco abuse ( $p=0.032$ ) and grafting procedures together with simultaneous sinus floor elevation techniques ( $p=0.001$ ) were found to be risk factors for success of the graft. Other factors did not influence outcome. Implant placement was not possible in 2 cases only.

## Discussion

The new surgical protocol including patient-specific titanium meshes, A®- and I®-PRF, resorbable membranes and bone grafting materials was proven to be a promising technique in complex bone and soft tissue reconstruction, even in cases of dehiscences. The present study applied a new exposure classification to describe soft tissue and grafting outcome. Potential risk factors associated with this protocol were tobacco abuse and mesh insertion simultaneous with sinus floor elevation procedures. A splitting of the surgical procedures in terms of sinus floor elevation is mandatory.