



ORAL RECONSTRUCTION
FOUNDATION

Full arch delayed implant placement with fully guided surgery. Case report



M. Solonko¹, H. Ribeiro-Vidal¹, E. Montero^{1,2}, I. Sanz-Sanchez^{1,2}, M. Sanz^{1,2}.

¹ - Master on Periodontology and Implants, Complutense University of Madrid, Spain

² - ETEP (Etiology and Therapy of Periodontal Diseases) Research Group, Complutense University of Madrid, Spain

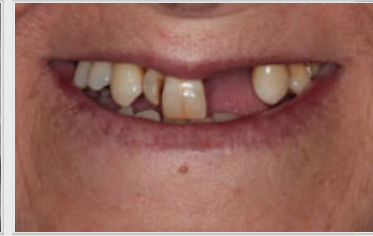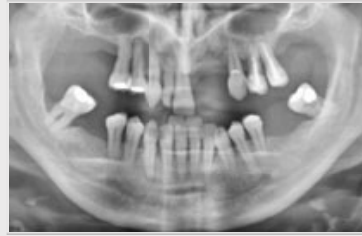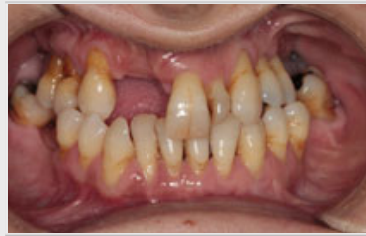Introduction and Purpose

Aim: to present a case report of a prosthetically driven digital treatment planning and its subsequent execution, using the fully guided implant placement protocol, in a patient with generalised advanced chronic periodontitis.

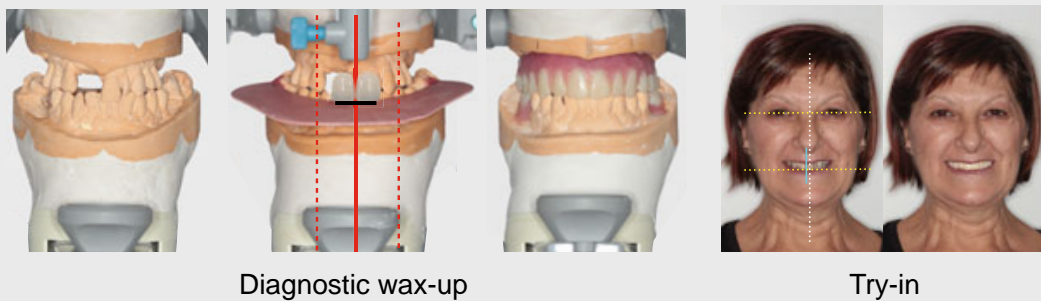
Methods

A 58-year old partially edentulous female patient was referred to the post-graduate clinic of Master of Periodontology program of Complutense University (Madrid, Spain).

Chief complaint: my upper and lower teeth are moving, and I am looking for the fixed rehabilitation of my mouth.



Diagnostics and esthetic analysis

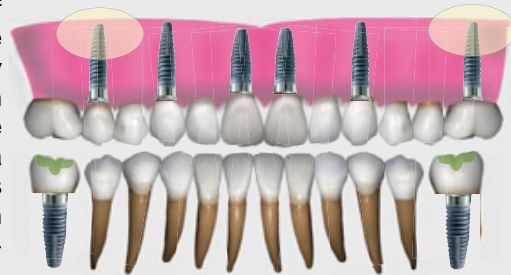


Diagnostic wax-up

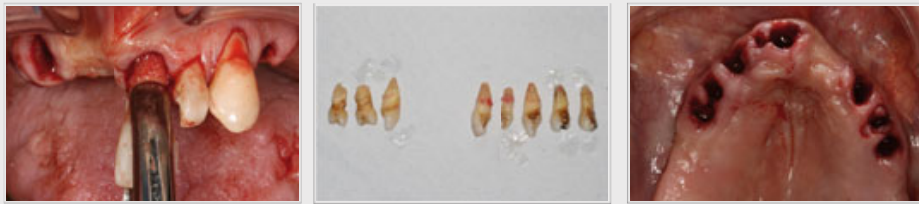
Try-in

Treatment plan

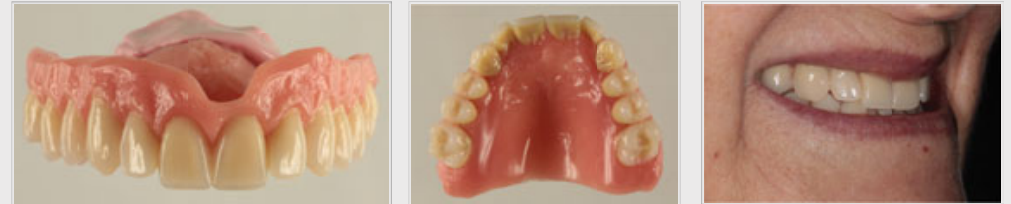Based on the diagnosis of chronic generalized severe periodontitis, teeth mobility grade II-III, pathologic teeth migration, posterior bite collapse and patient's desire to have a fixed solution, the decision was taken to extract all upper teeth with a subsequent fixed implant-supported rehabilitation.



Teeth extraction

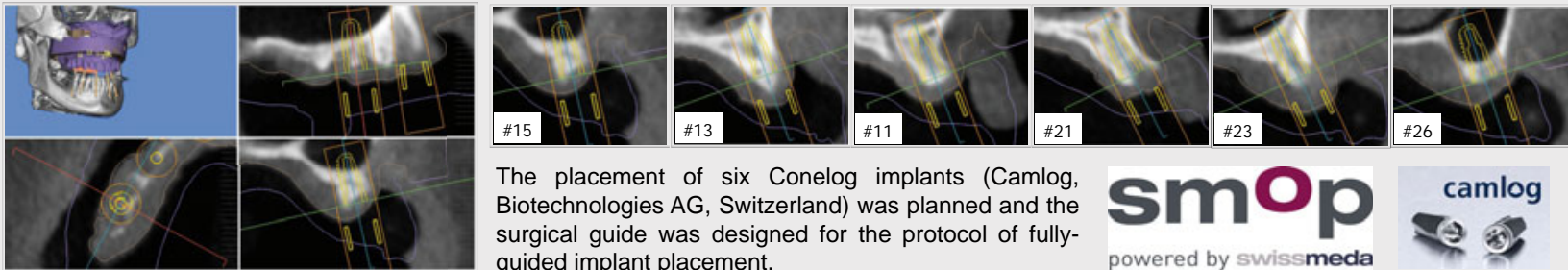


Immediate complete denture



Virtual planning of the surgical guide

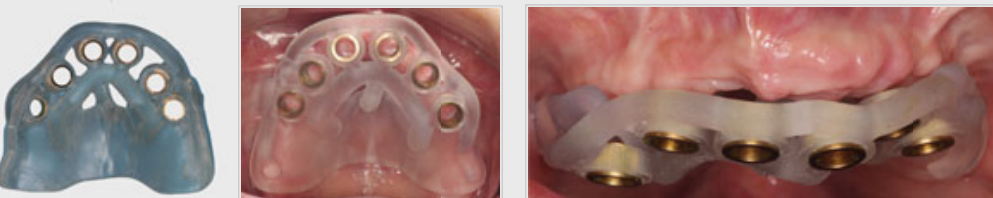6 weeks after teeth extraction, a CBCT was obtained, and the dental stone model of the maxilla was optically scanned. Resulting DICOM and STL files were superimposed in the SMOP Implant Planning System (Smop, Swissmeda, Zurich, Switzerland).



The placement of six Conelog implants (Camlog, Biotechnologies AG, Switzerland) was planned and the surgical guide was designed for the protocol of fully-guided implant placement.

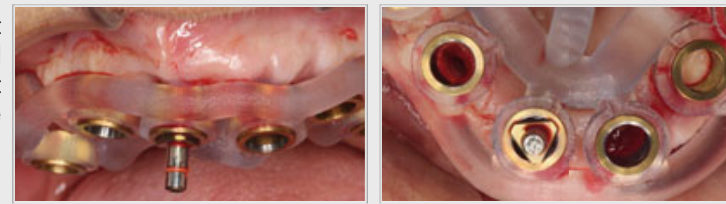


Try-in of the surgical guide

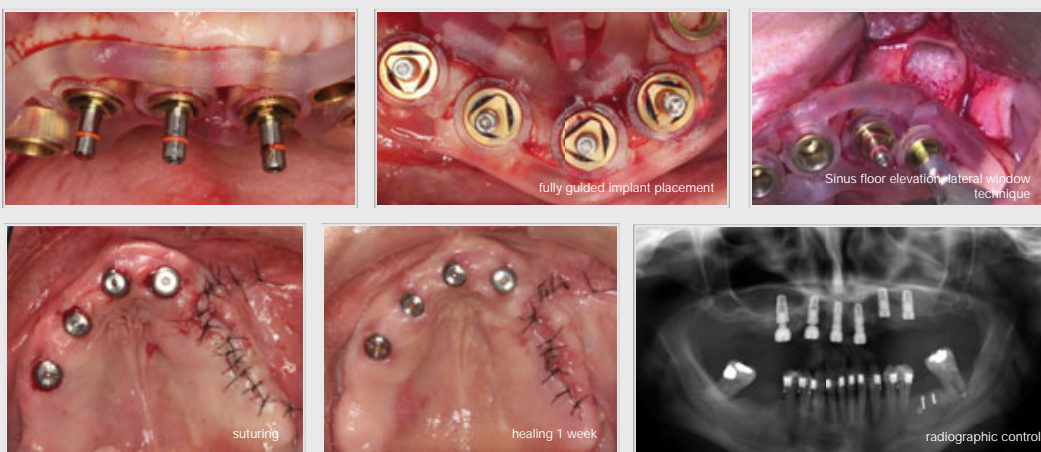


Surgical procedure

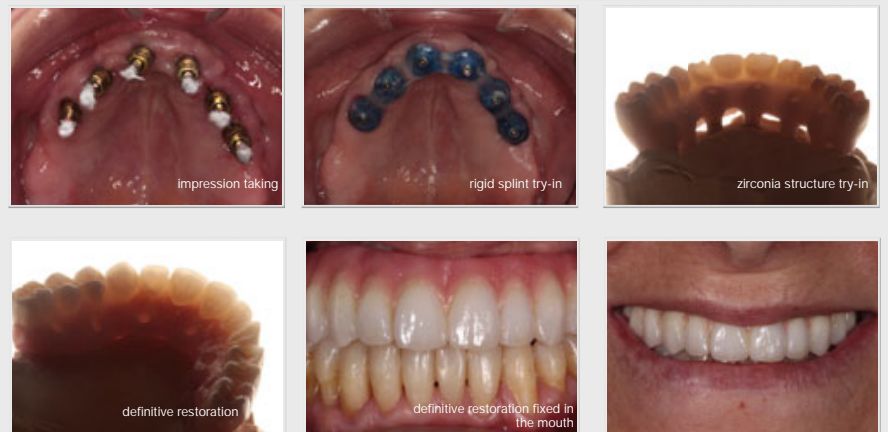First implant placement, and insertion post left in place to ensure additional surgical guide stability



Surgical procedure



Restorative procedures



Conclusions

Complex treatment planning using digital approach may facilitate the process of implants placement, making it more safe and predictable, and improve the long-term functional and esthetic result of the complex rehabilitation.

Disclosure

The authors declare that they do not have any conflict of interest.