

Peri-implant tissue behaviour next to implants with different surface characteristics

A 6-year follow-up prospective study

Dellepiane E*, Menini M, Chvartzaid D, Baldi D, Schiavetti I, Pera P

Objectives

To evaluate the behaviour of peri-implant tissues around implants with different surface treatment.

Materials and methods

Eight patients were identified according to these criteria: systemically good health, no history of periodontal disease, no contraindications for the surgical and prosthodontic protocol applied. Each patient received at least 2 implants (1 control, 1 test) into an edentulous quadrant. The control implants had dual acid-etched (DAE) surface in the apical portion and a machined coronal part, test implants had a completely DAE surface (Figures 1, 2). Machined healing abutments were placed on control implants and DAE abutments on test ones (Figures 3, 4). Standardized periapical radiographs were taken at baseline, 3 and 6 months, 1 year after surgery and then annually up to the 6 year follow-up. Histologic and microbiologic analyses of peri-implant tissues were conducted in the first year. Bleeding on probing (BOP) and Plaque Index (PI) were recorded annually. The research project was approved by the Scientific Ethical Committee of Genoa University and all patients provided informed consent to the study.

Statistical analysis

Differences in bone resorption over time were evaluated by Friedman test. For statistically significant differences post-hoc analysis with Wilcoxon signed-rank test was conducted with a Bonferroni correction. Any difference in bone resorption between the two types of implants or the maxilla operated, cortical or midullary bone quality were assessed by a repeated measure ANOVA for ranked data. The same analysis evaluated differences in PI and BOP. A $p \leq 0.05$ was statistically significant.

Results

A statistically significant difference in bone level was noted over time, in particular between baseline and the 1-year follow-up appointment ($p=0.001$), whereas no significant changes were observed after 1-year follow-up. At 1-year follow-up the difference in bone resorption between test and control was significant ($p=0.030$) with lower bone loss next to test implants (Figures 5, 6). A statistically significant difference ($p<0.001$) was found in bone resorption for the quality of cortical bone, with lower bone resorption in class 1 (dense) bone compared to class 2 (medium) and 3 (soft) during the first 3 years and a greater bone resorption in class 1 bone at subsequent follow-up appointments (Figure 7). In contrast, no statistically significant differences in the bone resorption were found for cancellous bone quality. No statistically significant differences were detected between test and control implants for BOP ($p=0.82$) and PI ($p=0.38$) (Figures 8, 9). Mean Probing Depth (PD) was 2,92 mm for test implants and 2,74 mm for control implants. No statistically significant difference was found in PD ($p=0.235$).

Conclusions

Moderate bone loss was found 1 year after surgery, then a steady state condition was observed with less bone resorption next to test implants. Implant surface might affect the bone remodelling phase subsequent to the surgical trauma, but once osseointegration was established, implant surfaces did not affect bone maintenance over time. Implant surfaces did not affect soft tissue behavior in the present study.



Fig. 1 Test implant on the left and control implant on the right.

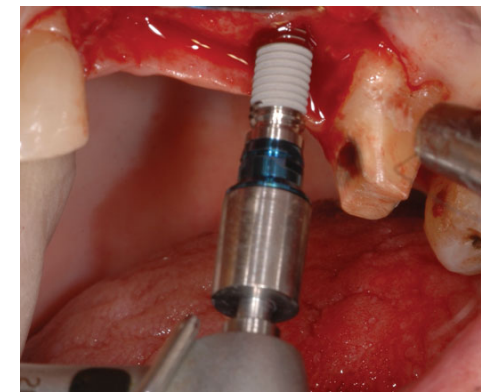


Fig. 2 Intraoperative view.



Fig. 3 Test and control healing abutments.

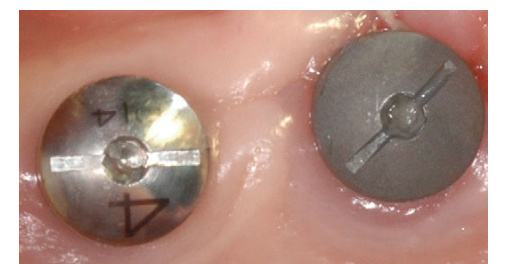


Fig. 4. Healing abutments (intraoral view).

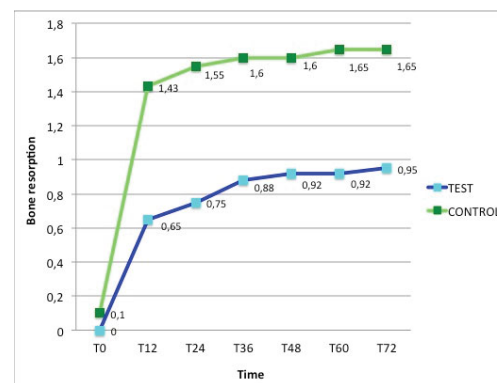


Fig. 5 Interproximal bone resorption (mm) over time (months) for implant type.

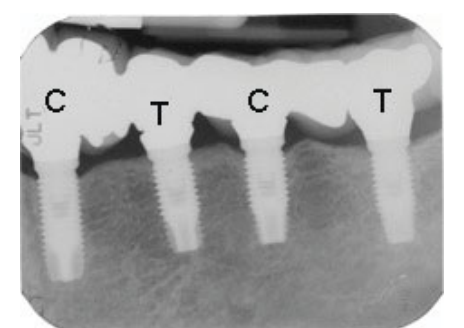


Fig. 6 Periapical radiograph taken 6 years post implant placement (C=control, T= test).

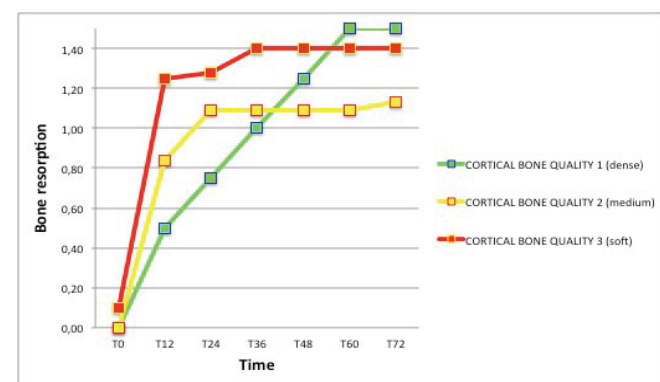


Fig. 7 Interproximal bone resorption (mm) over time for cortical bone quality .

	IMPLANT		p
	CONTROL	TEST	
T12	1,10 (0,57)	1,00 (0,67)	0,38
T24	1,50 (0,97)	1,10 (0,74)	
T36	1,30 (1,16)	1,60 (1,43)	
T48	1,80 (1,13)	0,90 (0,74)	
T60	0,90 (0,88)	1,10 (1,10)	
T72	0,60 (0,52)	0,80 (0,63)	

Fig. 8 Mean values of PI for type of implant.

	IMPLANT		p
	CONTROL	TEST	
T12	0,40 (0,52)	0,40 (0,52)	0,82
T24	0,60 (0,70)	0,50 (0,53)	
T36	0,80 (1,14)	1,00 (1,05)	
T48	0,80 (1,03)	0,80 (0,92)	
T60	1,20 (0,32)	1,10 (0,88)	
T72	0,60 (0,70)	0,90 (0,57)	

Fig. 9 Mean values of BOP for type of implant.

References

- Baldi D, Menini M, Pera F, Ravera G, Pera P. Plaque accumulation on exposed titanium surfaces and peri-implant tissue behaviour. A preliminar 1-year clinical study. Int J Prosthodont 2009;22:447-455.
- Pongnarison NJ, Gemmell E, Tan AE, Henry PJ, Marshall TI, Seymour GJ. Inflammation associated with implants with different surface types. Clin Oral Implants Res 2007;18:114-25.
- Degidi M, Artese L, Piattelli A, Scarano A, Shibli JA, Marcello Piccirilli M, Perrotti V, Iezzi G. Histological and immunohistochemical evaluation of the peri-implant soft tissues around machined and acid-etched titanium healing abutments: a prospective randomized study. Clin Oral Investig 2012;16:857-866.
- Chvartzaid D, Koka S. On manufactured diseases, healthy mouths and infected minds. Int J Prosthodont 2011;24:102-103.